Intrinsic Assessment, Anatomy, and Case Management

Presented by:
Mike Cricchio, MBA, OT/L, CHT

Hand & Upper Extremity
Conference Series LLC

Teton
Hand & Upper Extremity
Conference Series LLC



Teton
Hand & Upper Extremity
Conference Series LLC



Linkenauger, S., Wong, H., Geuss, M., Stefanucci, J., McCulloch, K., Bülthoff, H., Mohler, B. and Proffitt, D., 2015. The perceptual homunculus: The perception of the relative proportions of the human body. *Journal of Experimental Psychology: General*, 144(1), pp.103-

Teton
Hand & Upper Extremity
Conference Series LLC


Teton
Hand & Upper Extremity
Conference Series LLC

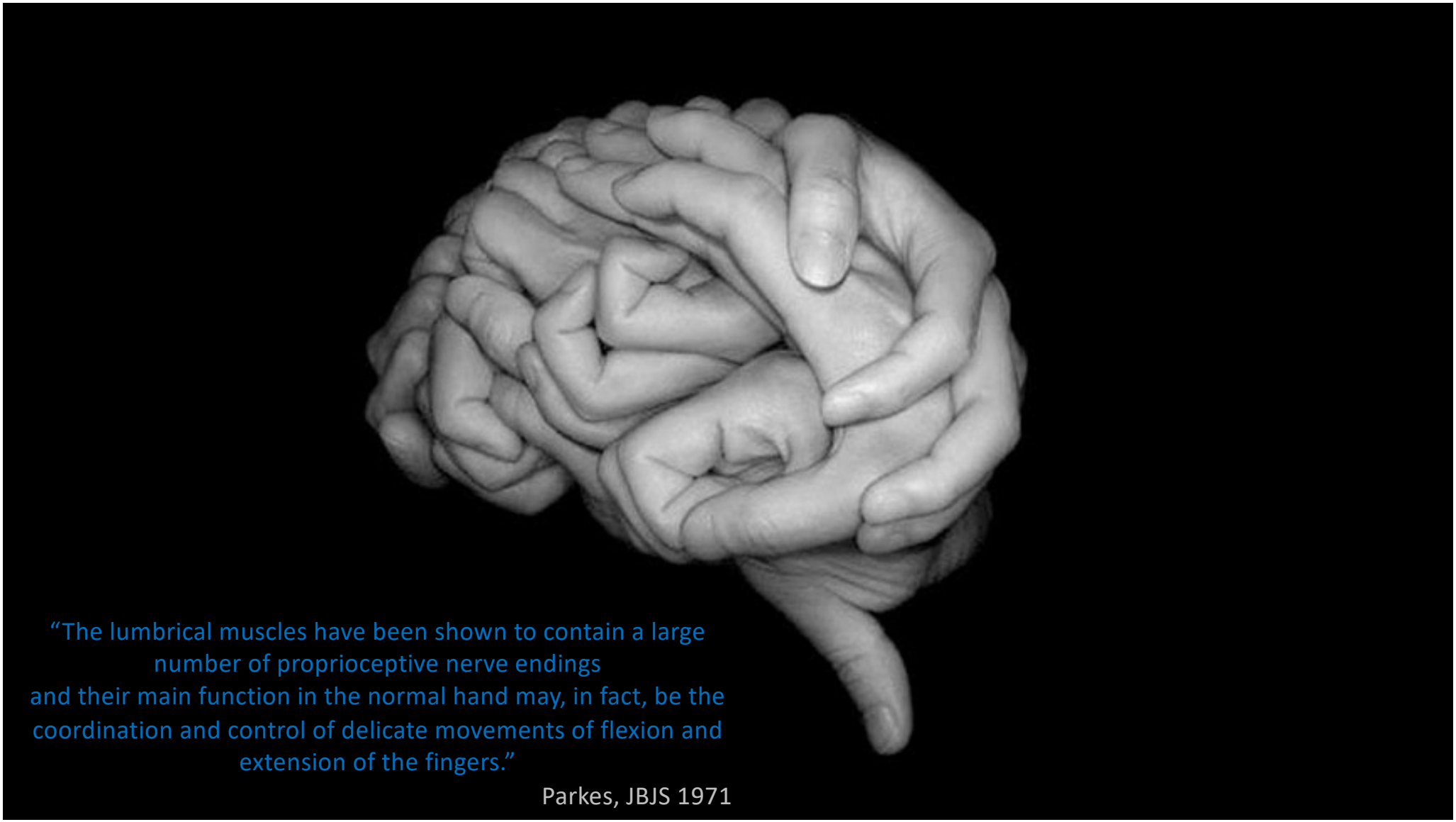

"The lumbrical muscles have been shown to contain a large number of proprioceptive nerve endings and their main function in the normal hand may, in fact, be the coordination and control of delicate movements of flexion and extension of the fingers."

Parkes, JBJS 1971

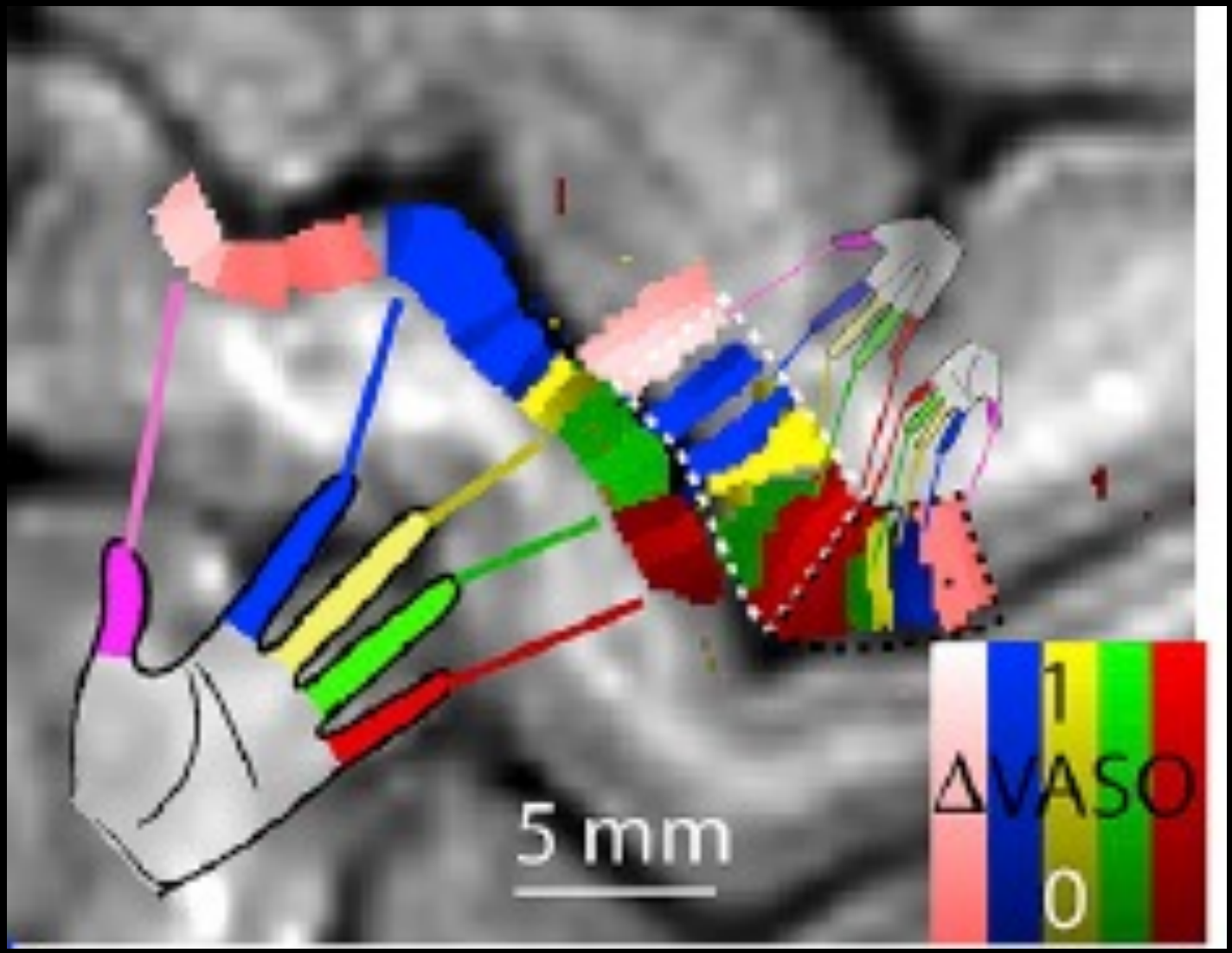
1
1
5 mm
ΔVASO
1
0



Conference Series LLC


Teton
Hand & Upper Extremity
Conference Series LLC


Teton
Hand & Upper Extremity
Conference Series LLC



Hand & Upper Extremity
Conference Series LLC

Teton
Hand & Upper Extremity
Conference Series LLC

Intrinsic Assessment, Anatomy, and Case Management

- Examine the anatomy and function of the dorsal interossei.
- Examine the anatomy and function of the palmar interossei.
- Examine the anatomy and function of the lumbricals.
- Discuss the relationship between the dorsal, palmar interossei and the lumbricals.
- Review the relationship between the intrinsic and extrinsic mechanisms.
- Highlight clinical cases to illustrate normal and pathological intrinsic anatomy.







Teton
Hand & Upper Extremity
Conference Series LLC


Kohler & Campbell



Intrinsic Assessment, Anatomy, and Case Management

Chapter 12

Intrinsic muscles of the fingers: function, dysfunction, and surgical reconstruction

RICHARD J. SMITH, M.D.
Boston, Massachusetts

Hand & Upper Extremity
Conference Series LLC

Teton
Hand & Upper Extremity
Conference Series LLC

Intrinsic Assessment, Anatomy, and Case Management

ARCHIVE

Non-Ischemic Contractures of the Intrinsic Muscles of the Hand

SMITH, RICHARD J. **Author Information**

JBJS: October 1971 - Volume 53 - Issue 7 - p 1313-1331

Hand & Upper Extremity
Conference Series LLC

Teton
Hand & Upper Extremity
Conference Series LLC

Intrinsic Assessment, Anatomy, and Case Management



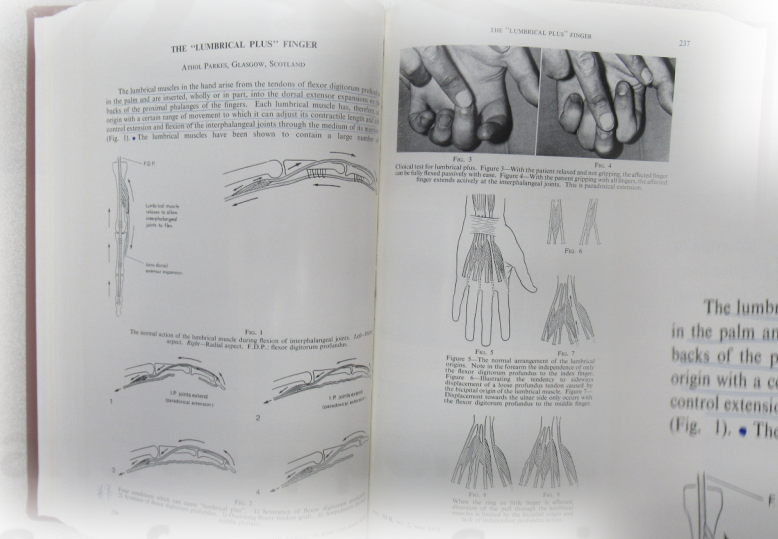

THE "LUMBRICAL PLUS" FINGER

ATHOL PARKES, GLASGOW, SCOTLAND

The lumbrical muscles in the hand arise from the tendons of flexor digitorum profundus in the palm and are inserted, wholly or in part, into the dorsal extensor expansion on the backs of the proximal phalanges of the fingers. Each lumbrical muscle has, therefore, its origin with a certain range of movement to which it can adjust its contractile length and so control extension and flexion of the interphalangeal joints through the medium of its tendon (Fig. 1). • The lumbrical muscles have been shown to contain a large number

Hand & Upper Extremity Conference Series

Teton
Hand & Upper Extremity
Conference Series LLC

Intrinsic Assessment, Anatomy, and Case Management



Teton
Hand & Upper Extremity
Conference Series LLC

HandLab



Intrinsic Assessment, Anatomy, and Case Management

Intrinsic Tightness
Interosseous Tightness
Lumbrical Tightness
Lumbrical-Plus Digit
Extensor Habitus
Paradoxical Extension
Quadriga

Teton
Hand & Upper Extremity
Conference Series LLC

Intrinsic Assessment, Anatomy, and Case Management

- **Interosseous Tightness**
  - Most common form of intrinsic tightness, contracture (adaptive shortening) of dorsal and/or palmar interossei. Measured PASSIVELY. Results in limited flexion of the PIP joint as the **MCP joint is extended**; Greater PIP joint flexion with **MCP joint flexed** than with the MCP joint extended.
- **Lumbrical Tightness**
  - Less common than interosseous tightness, contracture (adaptive shortening) of the lumbrical muscle resulting in tension on the radial lateral band and limited DIP flexion with combined PIP joint flexion. Must be measured ACTIVELY secondary to soft tissue origin on the FDP tendon.
- **Lumbrical-Plus Digit** (Extensor Habitus, Paradoxical extension)
  - FDP lacerated distal to the origin of the lumbrical muscle. Absent its distal integrity, the FDP tendon, that continues to have an attachment to the lumbrical muscle, and the lumbrical to the lateral band and extensor mechanism, loses its ability to contribute to flexion of the PIP joint. As a result, the FDP contracts and extends the PIP and DIP joints. The result a Lumbrical-Plus digit; paradoxical extension occurs. Distal FDP anchor moves proximally to point of extensor mechanism.
- **Quadriga Effect**
  - **Active flexion lag** in *adjacent* digits following repaired FDP (MF,RF, SF)
  - Functional shortening of FDP caused by over-advanced FDP repair, adhesion, retraction of tendon resulting in a weak grip and inability to fully flex adjacent digit(s).

Hand & Upper Extremity Conference Series LLC

Intrinsic Assessment, Anatomy, and Case Management

Most common: FDP to IF is independent muscle belly, FDP to MF, RF, SF share a common muscle belly
Paradoxical EXTENSION of the IP joints while attempting to FLEX the fingers
Most common in MF (2nd lumbrical)
DIP amputation
FDP tendon graft that is too long
Amputation through the middle phalanx
FDP avulsion/transection
FDP laceration & FDP contraction lead to pull on lumbricals

Teton Hand & Upper Extremity Conference Series LLC

Intrinsic Assessment, Anatomy, and Case Management

Lumbricals pull on lateral bands leading to PIP and DIP extension of involved digit

FDP distal transection leads to pull of the 3rd lumbrical origin ulnarly (bipennate) leads to increased tightening of the middle finger lumbrical (2nd lumbrical, unipennate), and increases the lumbrical plus of the MF

Hand & Upper Extremity Conference Series LLC

Teton
Hand & Upper Extremity
Conference Series LLC



Teton
Hand & Upper Extremity
Conference Series LLC



Teton
Hand & Upper Extremity
Conference Series LLC



Hand & Upper Extremity
Conference Series LLC

Teton
Hand & Upper Extremity
Conference Series LLC

Intrinsic Assessment, Anatomy, and Case Management

Outline:

1st section: Intrinsic & Extrinsic Relationship
2nd section: Intrinsic & Extrinsic Assessment
3rd Section: Mechanics
4th Section: Distal Intrinsic Anatomy
5th Section: Static Stabilizers
6th Section: Drawling Lab

Hand & Upper Extremity Conference Series LLC

Intrinsic Assessment, Anatomy, and Case Management

1st Section:

Intrinsic and extrinsic relationships

Hand & Upper Extremity Conference Series LLC

Teton
Hand & Upper Extremity
Conference Series LLC

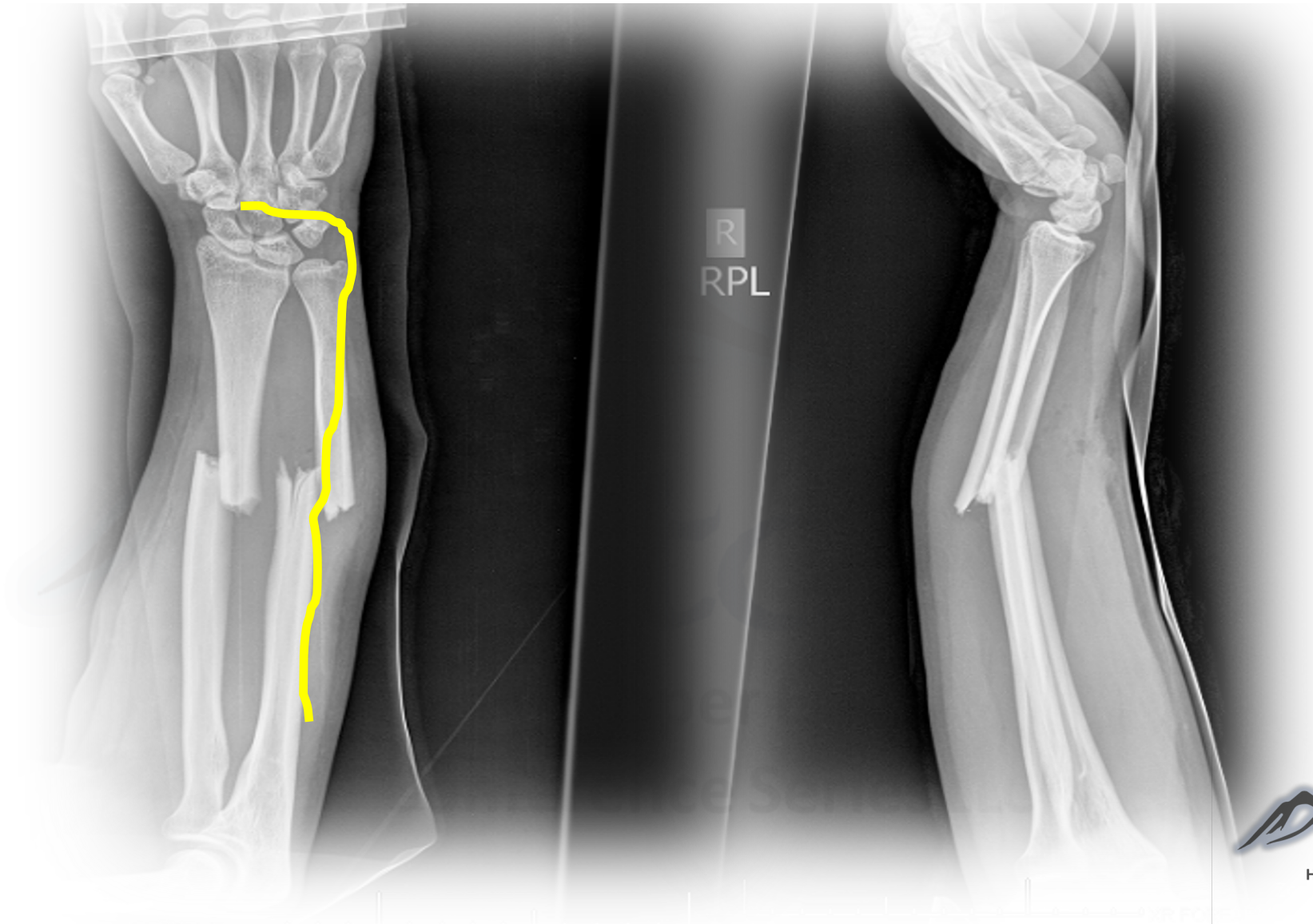

Teton
Hand & Upper Extremity
Conference Series LLC

Intrinsic Assessment, Anatomy, and Case Management



IP Joint Extension

Intrinsic Contribution

Extrinsic Contribution

Teton
Hand & Upper Extremity Conference Series LLC

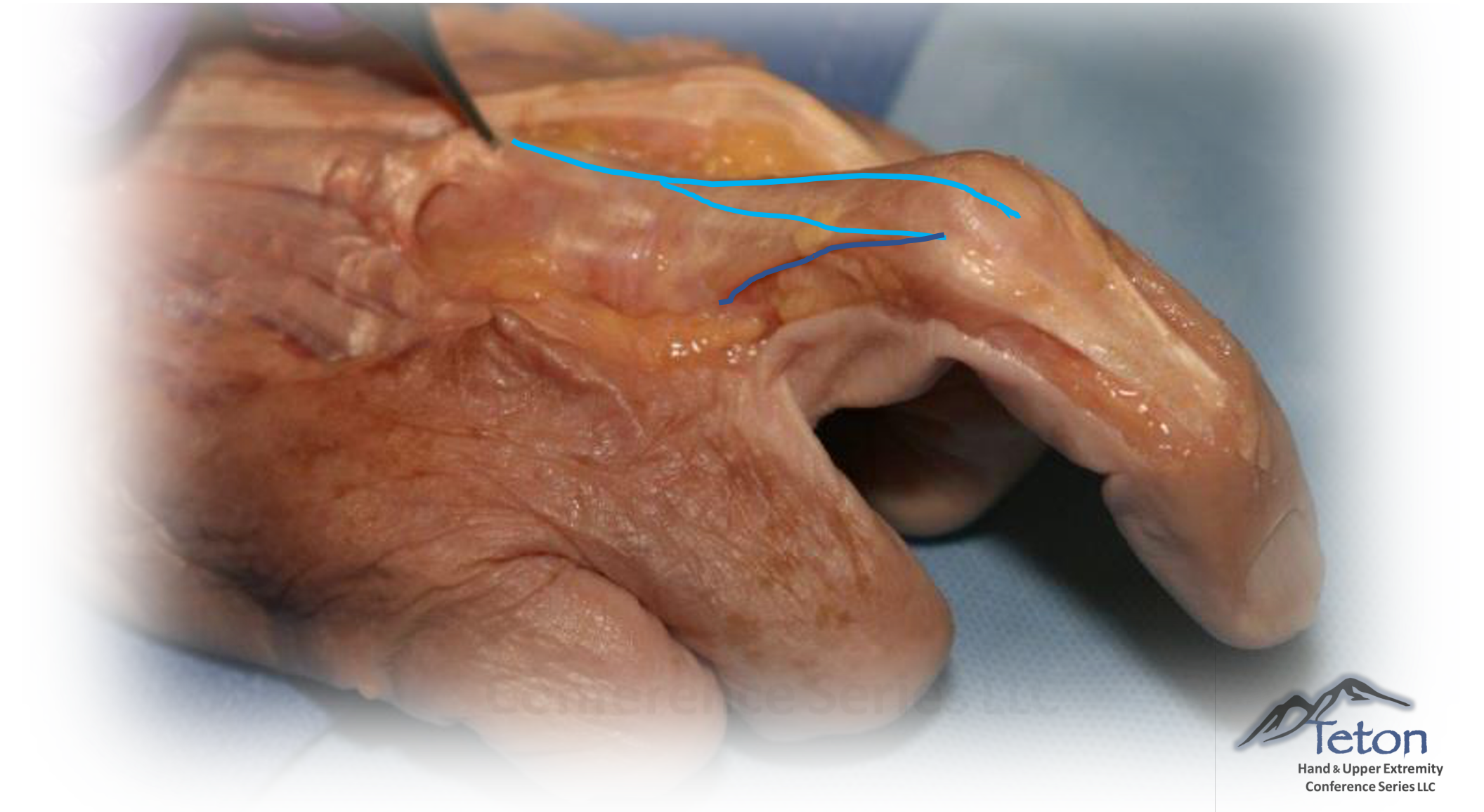

Teton
Hand & Upper Extremity
Conference Series LLC



Teton
Hand & Upper Extremity
Conference Series LLC



Teton
Hand & Upper Extremity
Conference Series LLC

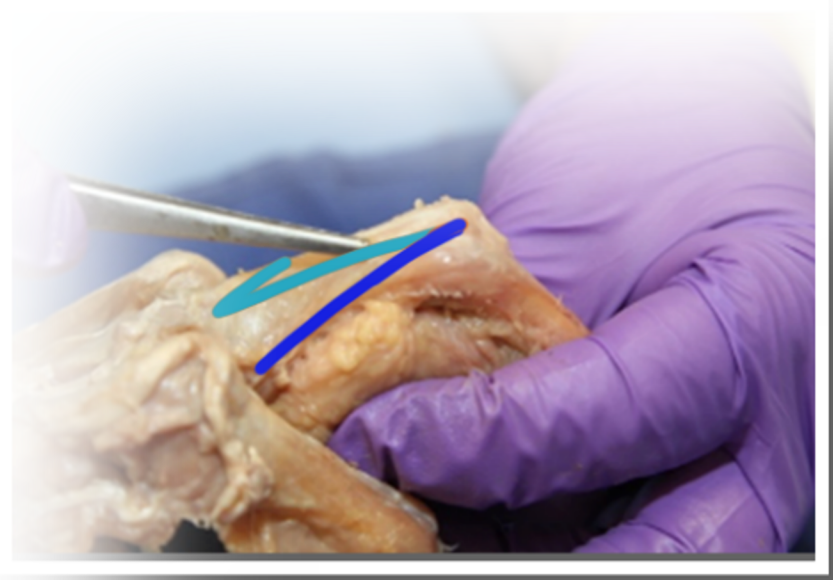

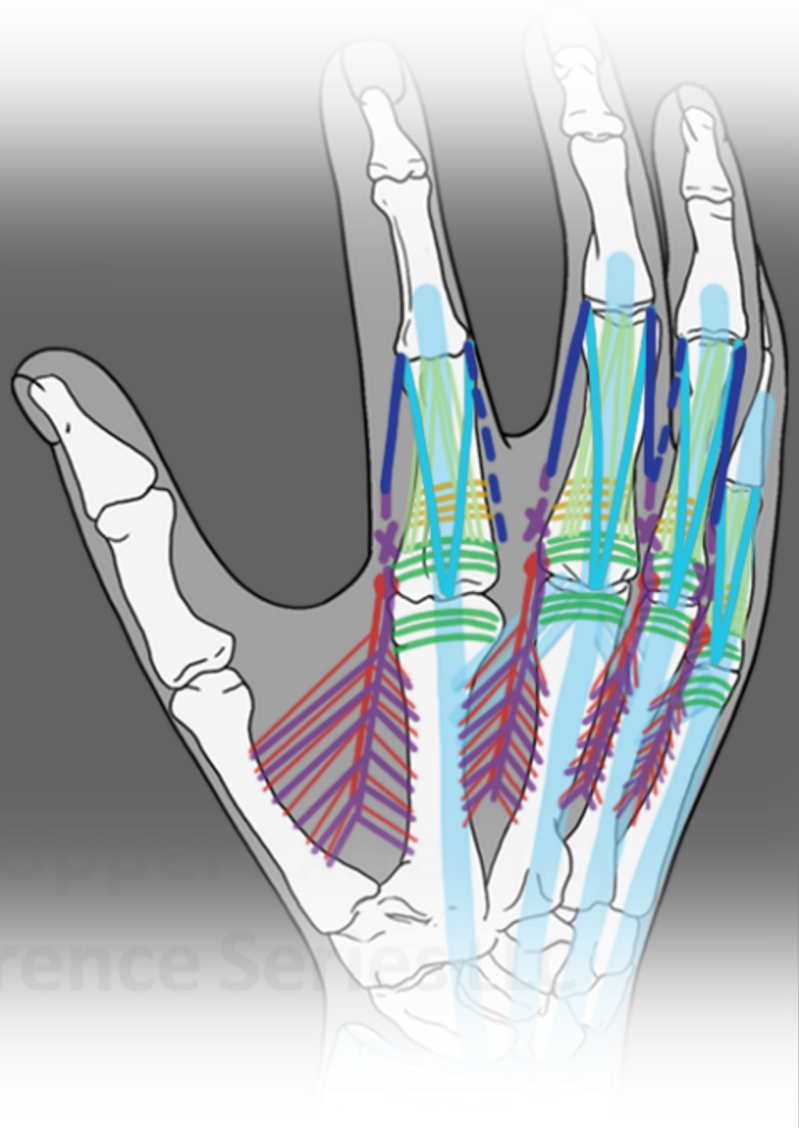

Teton
Hand & Upper Extremity
Conference Series LLC

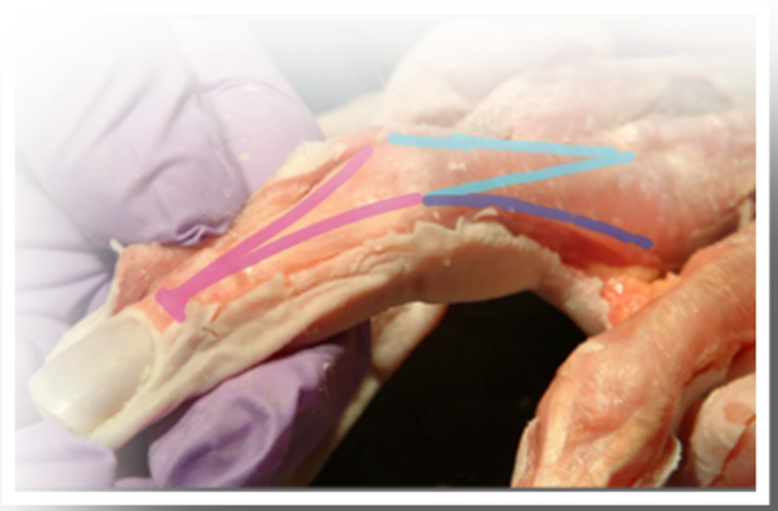

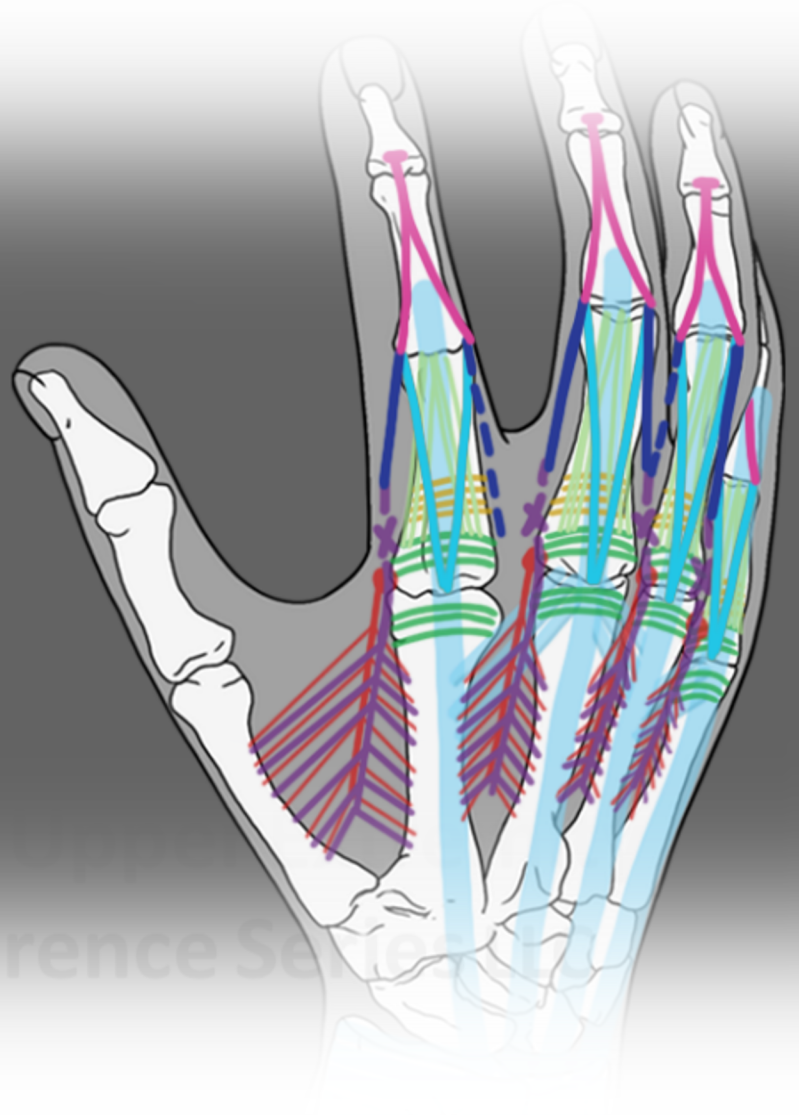

Conference Series LLC

Teton
Hand & Upper Extremity
Conference Series LLC

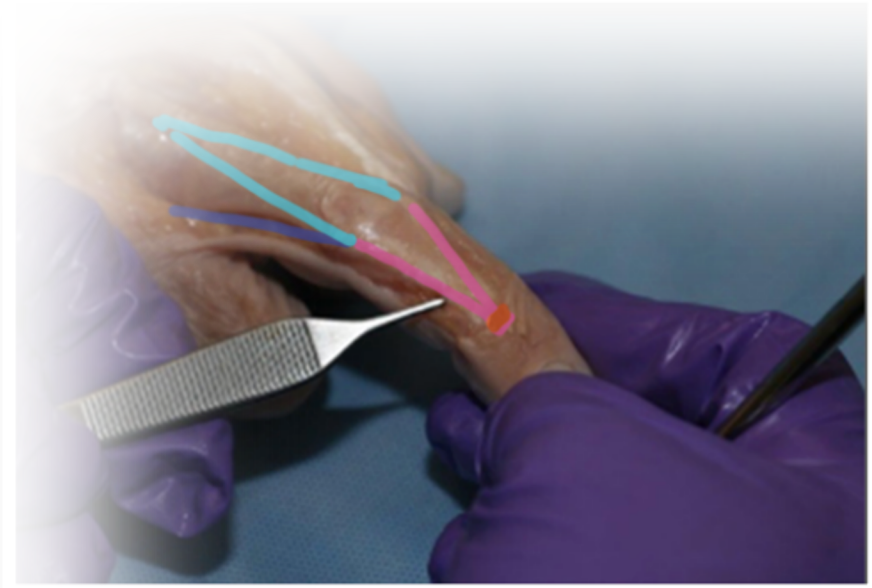

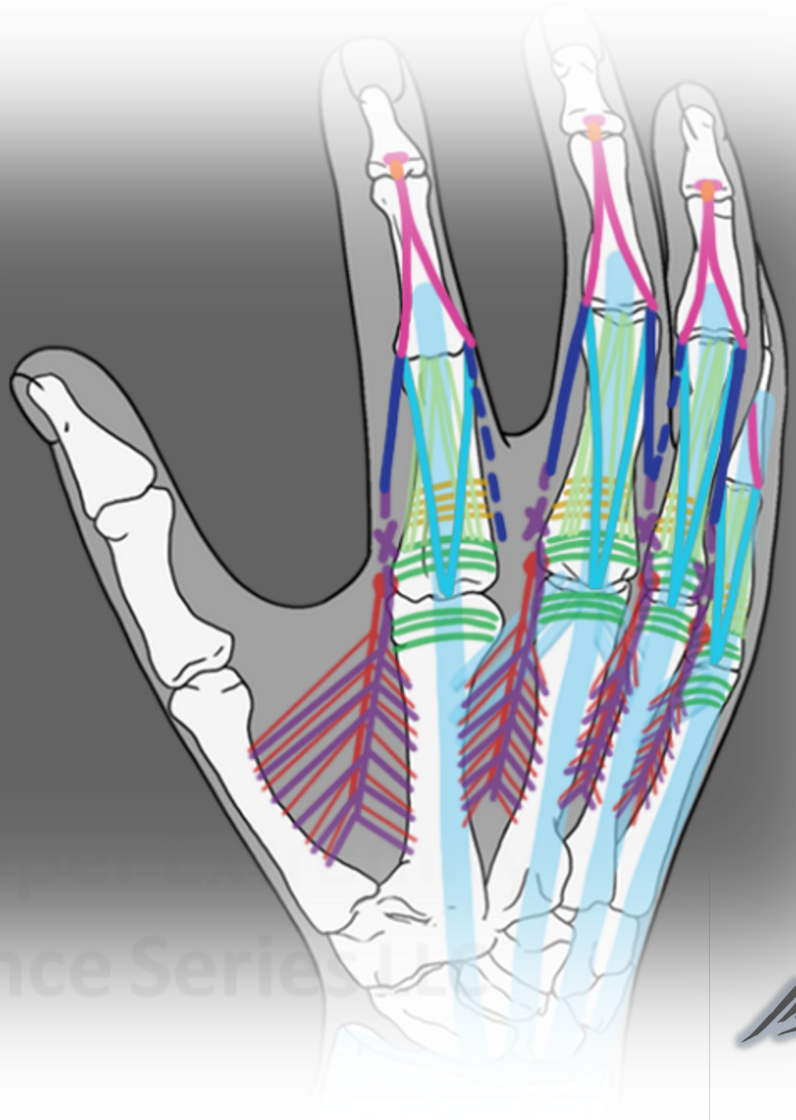

Conference Series LLC

Teton
Hand & Upper Extremity
Conference Series LLC

Intrinsic Assessment, Anatomy, and Case Management





Teton
Hand & Upper Extremity
Conference Series LLC

Intrinsic Assessment, Anatomy, and Case Management



Teton
Hand & Upper Extremity
Conference Series LLC


Teton
Hand & Upper Extremity
Conference Series LLC

Intrinsic Assessment, Anatomy, and Case Management



Teton
Hand & Upper Extremity
Conference Series LLC



Conference Series LLC

Teton
Hand & Upper Extremity
Conference Series LLC



Teton
Hand & Upper Extremity
Conference Series LLC



Conference Series LLC

Teton
Hand & Upper Extremity
Conference Series LLC



Hand & Upper Extremity
Conference Series LLC

Teton
Hand & Upper Extremity
Conference Series LLC



Teton
Hand & Upper Extremity
Conference Series LLC

Intrinsic Assessment, Anatomy, and Case Management

2nd Section:

Intrinsic & Extrinsic Assessment

Hand & Upper Extremity
Conference Series LLC

Teton
Hand & Upper Extremity
Conference Series LLC



Teton

Hand & Upper Extremity
Conference Series LLC



Hand & Upper Extremity
Conference Series LLC





Hand & Upper Extremity
Conference Series LLC

Teton
Hand & Upper Extremity
Conference Series LLC

Intrinsic Assessment, Anatomy, and Case Management

- Intrinsic tightness test (radial & ulnar moment tests)
- Oblique retinacular ligament tightness test (ORL test)
- Wartenburg's sign/test (3rd Palmar internossei/ulnar nerve)
- Froment's sign (Adductor pollicis/ulnar nerve)
- Extrinsic extensor tightness test (muscle/tendon shortening)
- Extrinsic flexor tightness test (muscle/tendon shortening)
- Snapping Lateral Bands

Teton
Hand & Upper Extremity
Conference Series LLC

Intrinsic Assessment, Anatomy, and Case Management

Intrinsic (Interosseus) Tightness Test

Described by Finochietto in 1920

Limited flexion of the PIP joint as the MCP joint is extended

Greater PIP joint flexion with MCP joint flexed than with the MCP joint extended



Teton
Hand & Upper Extremity
Conference Series LLC

Intrinsic Assessment, Anatomy, and Case Management



Teton
Hand & Upper Extremity
Conference Series LLC



Teton

Hand & Upper Extremity
Conference Series LLC

Intrinsic Assessment, Anatomy, and Case Management





Teton
Hand & Upper Extremity
Conference Series LLC

Intrinsic Assessment, Anatomy, and Case Management



Conference Series LLC

Teton
Hand & Upper Extremity
Conference Series LLC

Intrinsic Assessment, Anatomy, and Case Management



Conference Series LLC

Teton
Hand & Upper Extremity
Conference Series LLC

Intrinsic Assessment, Anatomy, and Case Management



Teton
Hand & Upper Extremity
Conference Series LLC

Intrinsic Assessment, Anatomy, and Case Management



Oblique Retinacular Ligament (ORL) Tightness: positive test when DIP passive flexion is greater with PIP joint flexion than with PIP extension.

Teton
Hand & Upper Extremity
Conference Series LLC

Intrinsic Assessment, Anatomy, and Case Management



Wartenberg Sign:

Patient complains that the little finger gets caught on the edge of the pants pocket when he or she tries to place the hand into the pocket. (3rd Palmar interossei ulnar nerve involvement and weakness)

Hand & Upper Extremity Conference Series LLC

Intrinsic Assessment, Anatomy, and Case Management



Extrinsic Extensor Tightness

MCP joint is flexed, the extrinsics are near their maximal excursion. The PIP joint should be able to flex more than 90 degrees, but if it cannot, it means that the extrinsics are tight and have lost that extra excursion.

Teton
Hand & Upper Extremity
Conference Series LLC

Intrinsic Assessment, Anatomy, and Case Management



Extrinsic Flexor Tightness

MCP joint and IP joints are extended, in this position the extrinsics flexors are near their maximal excursion. The PIP and DIP joints assumes a flexed posture due to shortening of the FDS & FDP tendon(s)

Teton
Hand & Upper Extremity
Conference Series LLC

Intrinsic Assessment, Anatomy, and Case Management



Froment's Sign

(weakness 1st DI & Adductor Pollicis/ulnar nerve)

Hand & Upper Extremity Conference Series LLC

Teton
Hand & Upper Extremity
Conference Series LLC

Intrinsic Assessment, Anatomy, and Case Management



Hand & Upper Extremity
Conference Series LLC

Snapping Lateral Bands

Teton
Hand & Upper Extremity
Conference Series LLC

Intrinsic Assessment, Anatomy Diagnoses, and Case Management

3rd Section

Mechanics

Hand & Upper Extremity
Conference Series LLC

Teton
Hand & Upper Extremity
Conference Series LLC

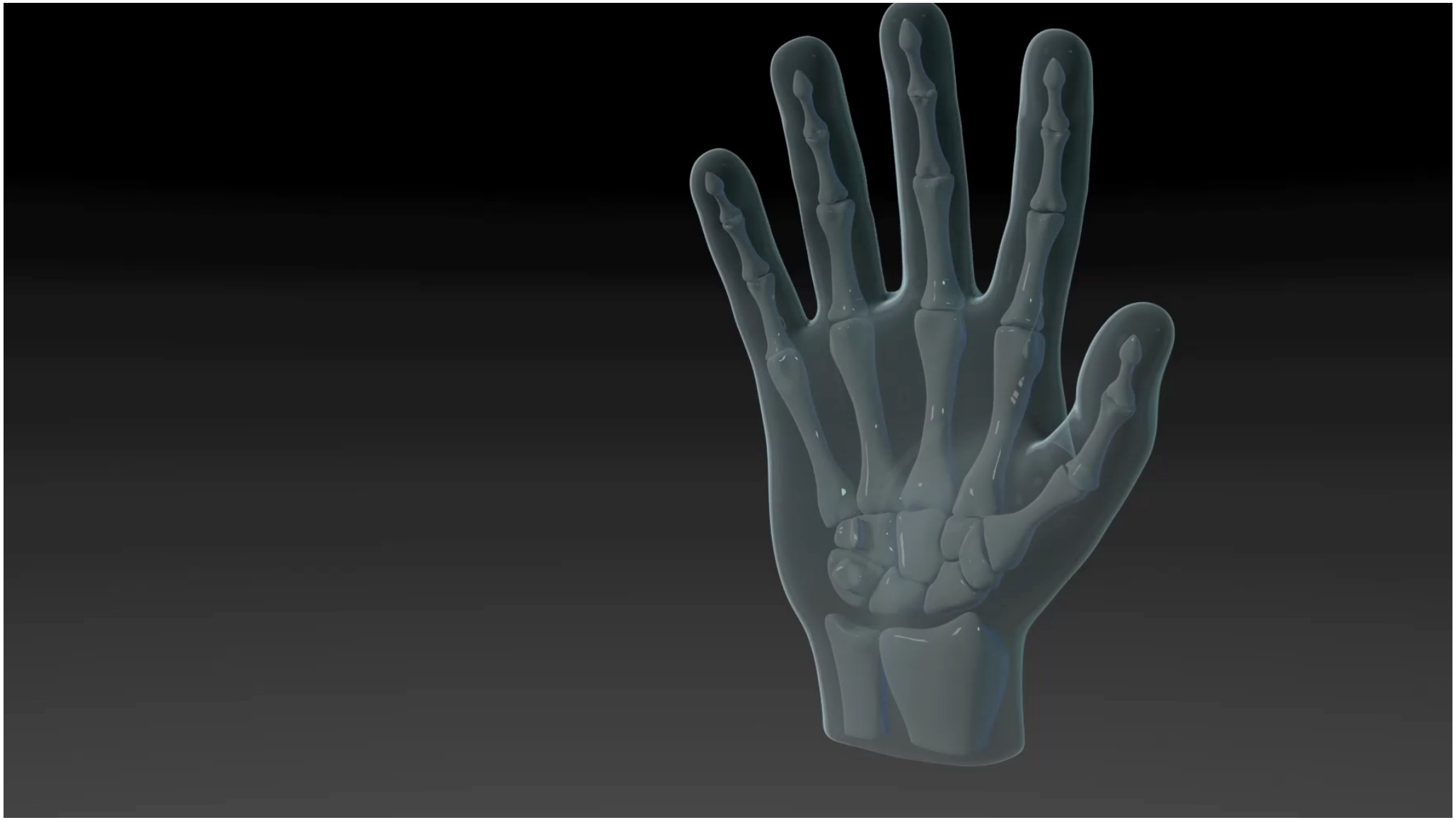

Intrinsic Assessment, Anatomy, and Case Management

Function of Sagittal Bands

- Acts as dorsal sling for long extensors of fingers over MCP joints
- With extensor contraction, the extensor tendon lifts the proximal phalanx through the sagittal band

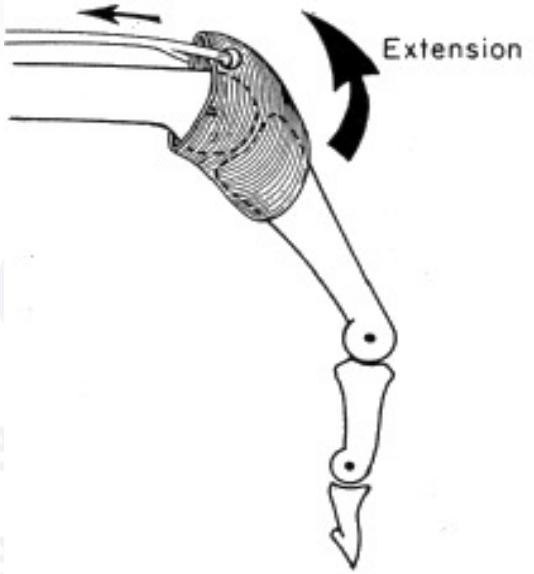

Teton
Hand & Upper Extremity
Conference Series LLC

Intrinsic Assessment, Anatomy, and Case Management

Function of Sagittal Bands

- Keeps the extensor tendon midline
- If MCP joint hyperextends, the sagittal band locks the extensor tendon
- The extensor tendon has less control on IP joints and IP joints fall into flexion

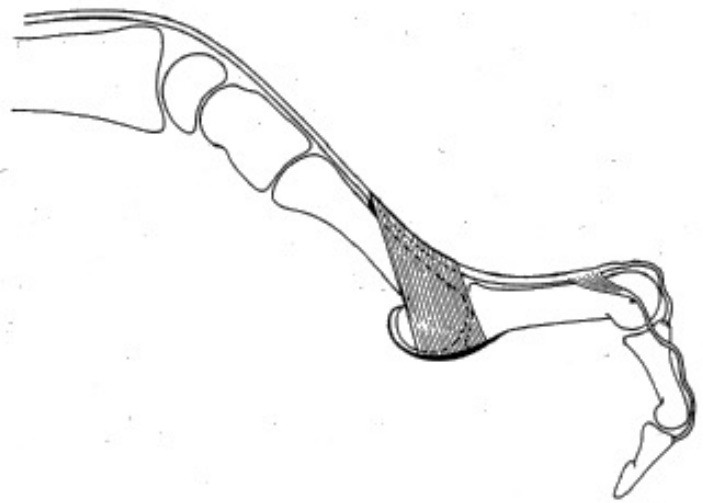

Hand & Upper Extremity Conference Series LLC

Intrinsic Assessment, Anatomy, and Case Management



Conference Series LLC

Teton
Hand & Upper Extremity
Conference Series LLC



Teton
Hand & Upper Extremity
Conference Series LLC

Intrinsic Assessment, Anatomy, and Case Management



Hand & Upper Extremity
Conference Series LLC

Intrinsic Assessment, Anatomy, and Case Management



Teton
Hand & Upper Extremity
Conference Series LLC

Intrinsic Assessment, Anatomy, Case Management



Teton
Hand & Upper Extremity
Conference Series LLC

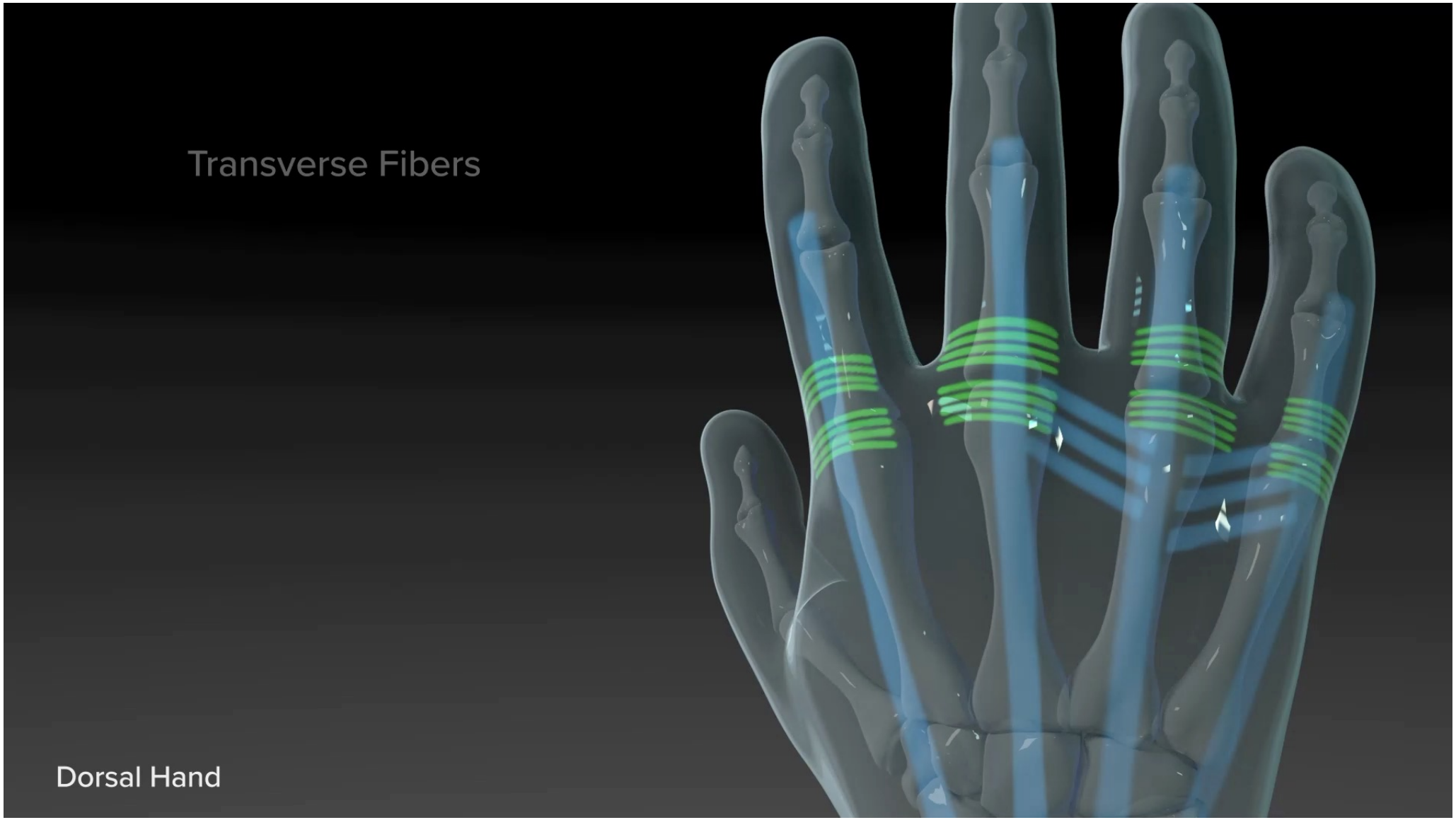
Transverse Fibers
Dorsal Hand

Intrinsic Assessment, Anatomy, and Case Management

Function of Transverse Fibers

- Function: flex the MCP joints when the interossei contract
- Part of the intrinsic muscle apparatus of finger

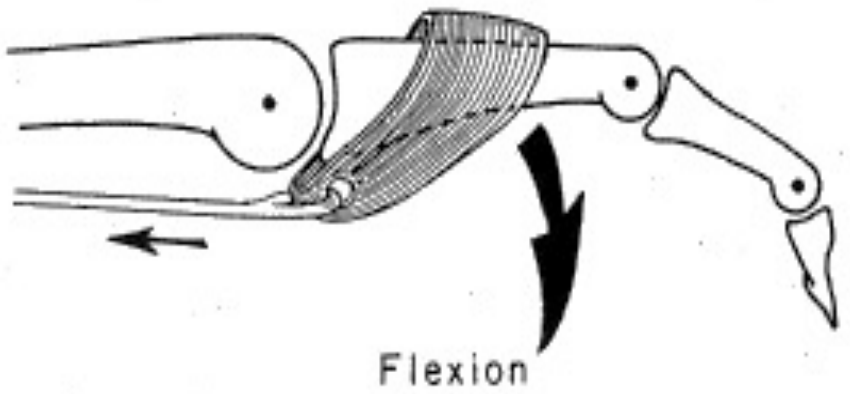

Teton
Hand & Upper Extremity
Conference Series LLC

Intrinsic Assessment, Anatomy, and Case Management





Conference Series LLC

Teton
Hand & Upper Extremity
Conference Series LLC

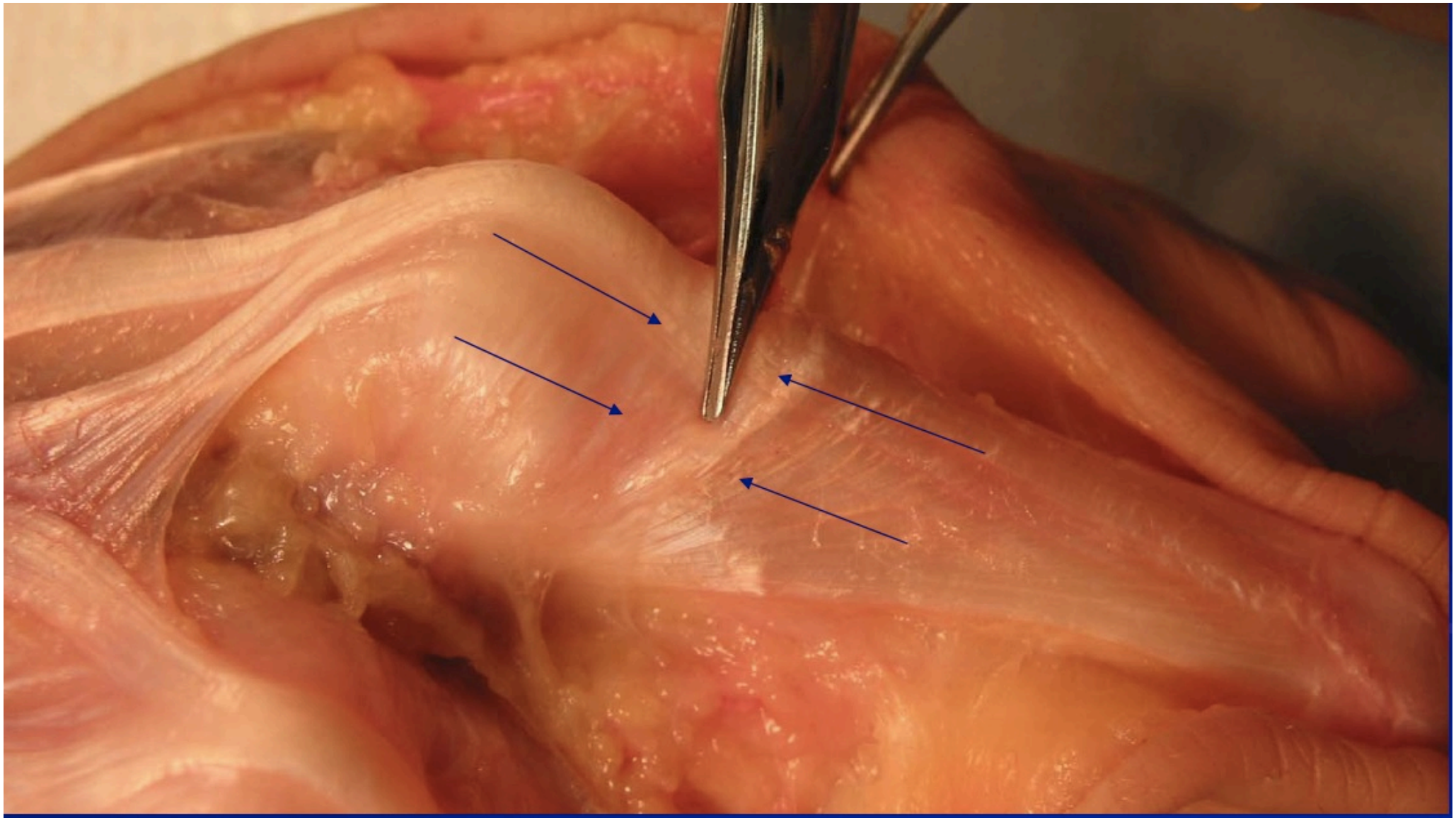

Intrinsic Assessment, Anatomy, and Case Management



Teton
Hand & Upper Extremity
Conference Series LLC

Intrinsic Assessment, Anatomy, Case Management

Function of Transverse Fibers

- Function: flex the MCP joints when the interossei contract
- Part of the intrinsic muscle apparatus of finger

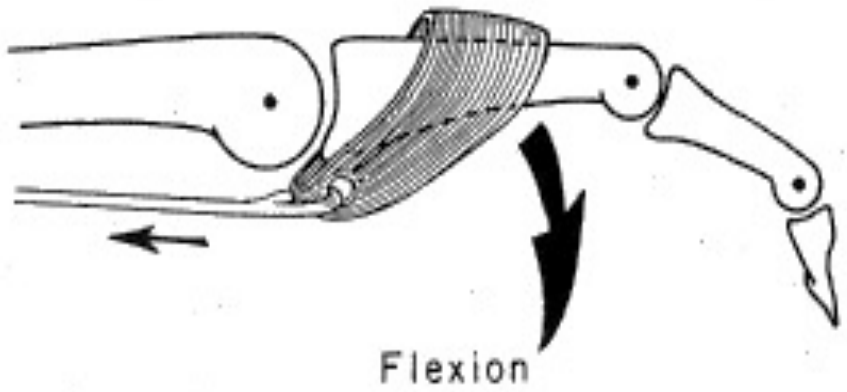

Hand & Upper Extremity Conference Series LLC

Teton
Hand & Upper Extremity
Conference Series LLC

Intrinsic Assessment, Anatomy, and Case Management

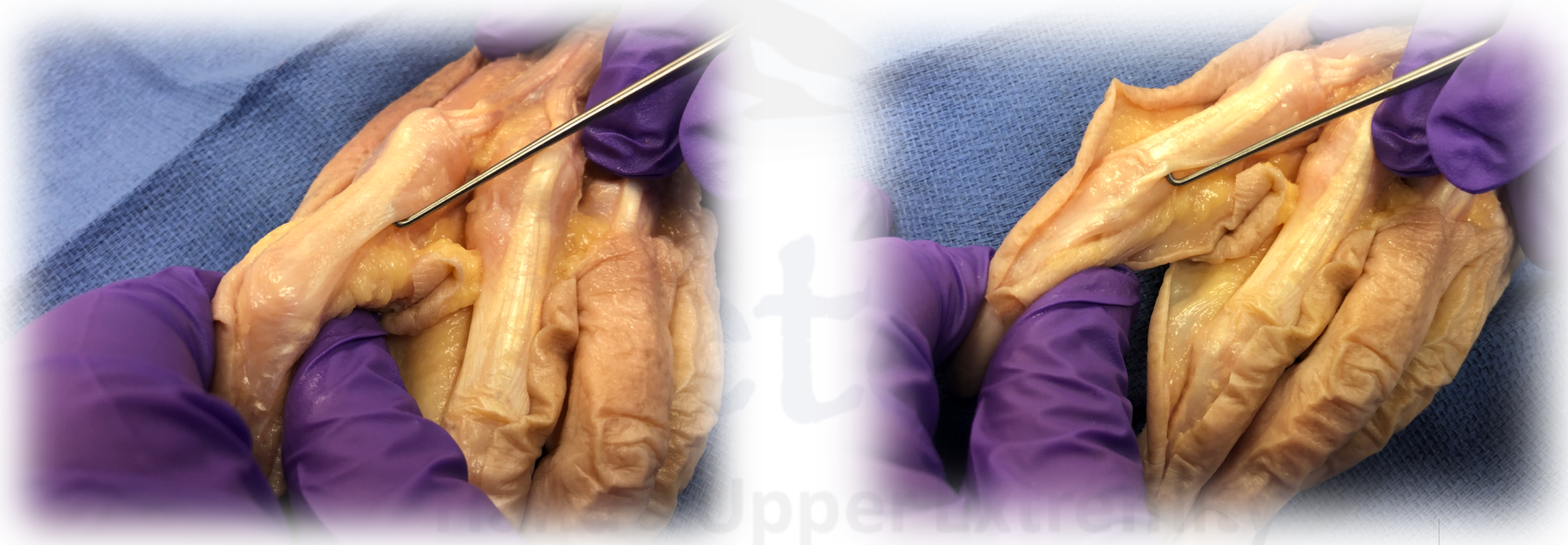

Conference Series LLC

Teton
Hand & Upper Extremity
Conference Series LLC

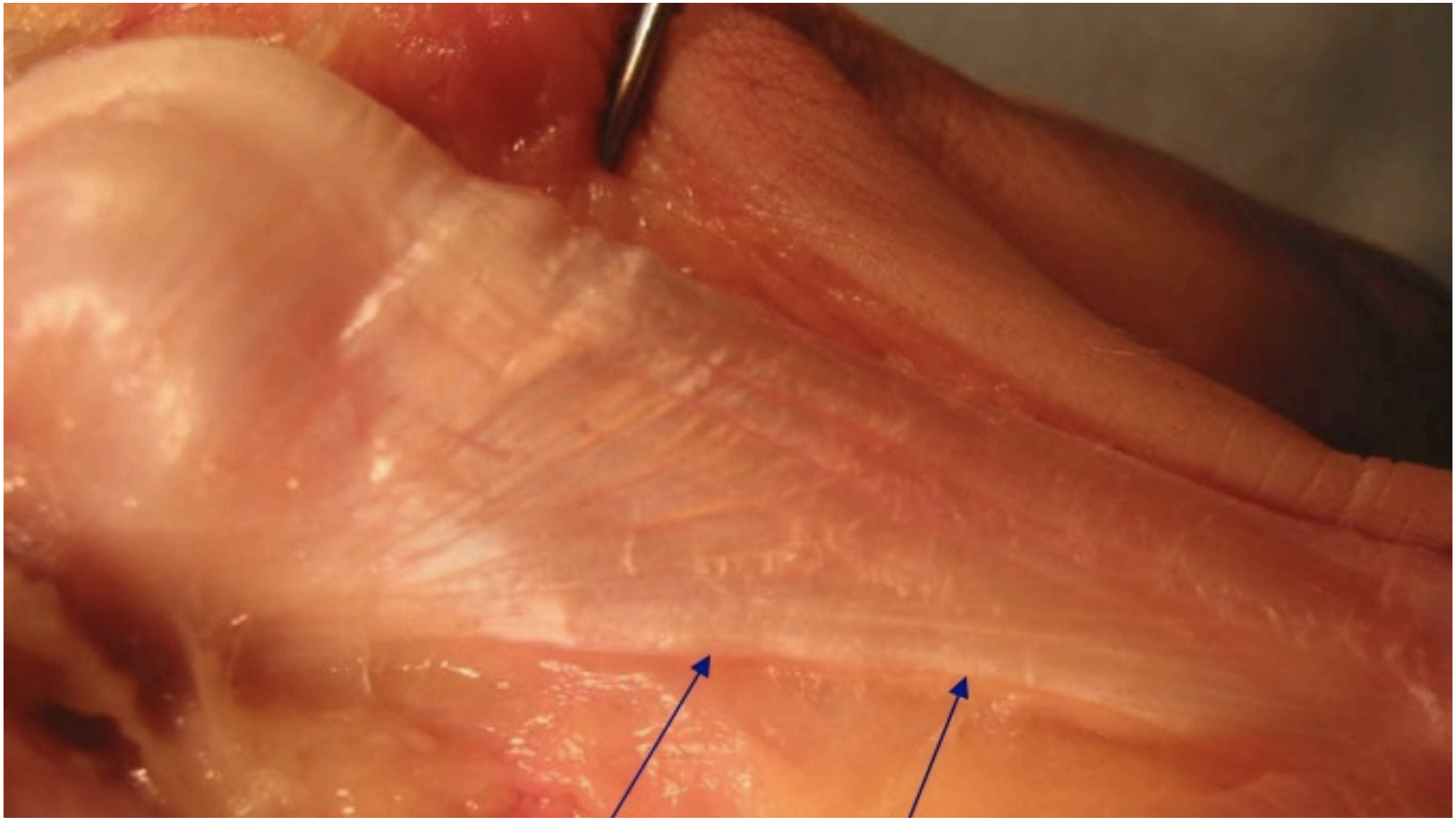

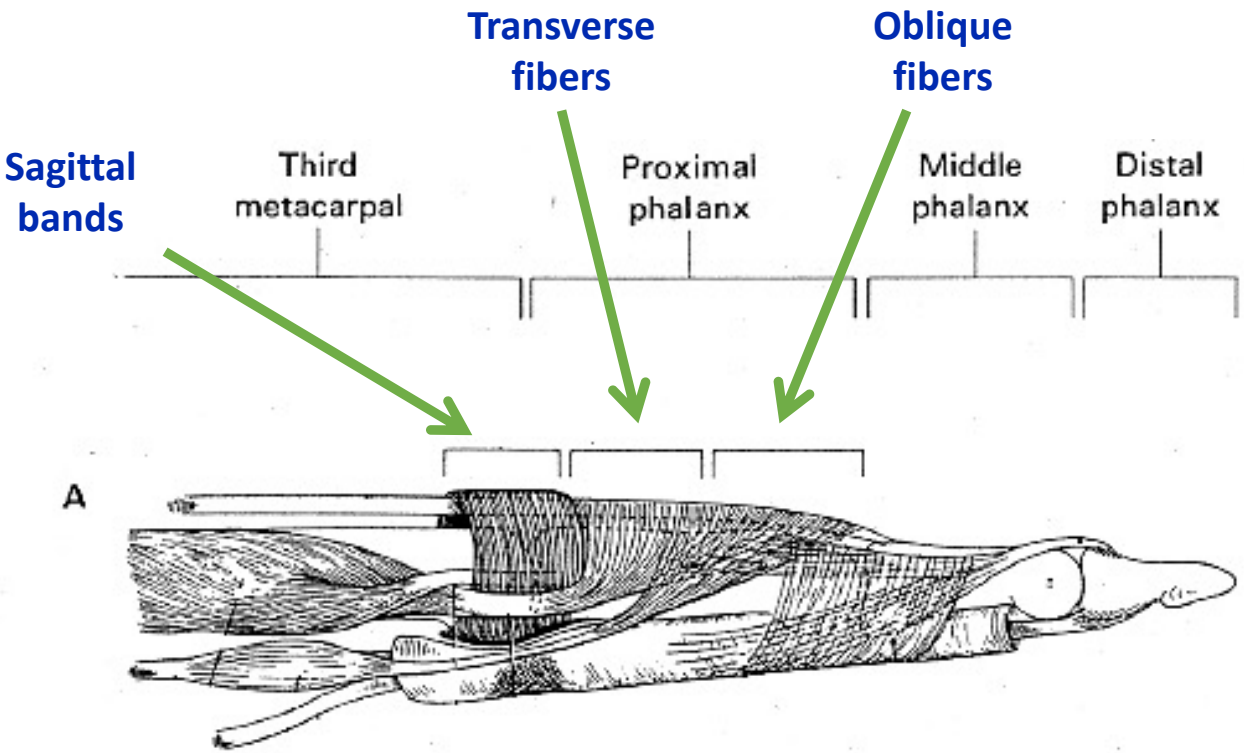

Hand & Upper Extremity Conference Series LLC

Intrinsic Assessment, Anatomy, and Case Management

4th Section:

Distal Intrinsic Anatomy: Lateral Bands, Lateral Slips of EDC, Conjoined lateral bands, Terminal Tendon

Hand & Upper Extremity Conference Series LLC

Teton
Hand & Upper Extremity
Conference Series LLC

Intrinsic Assessment, Anatomy, and Case Management

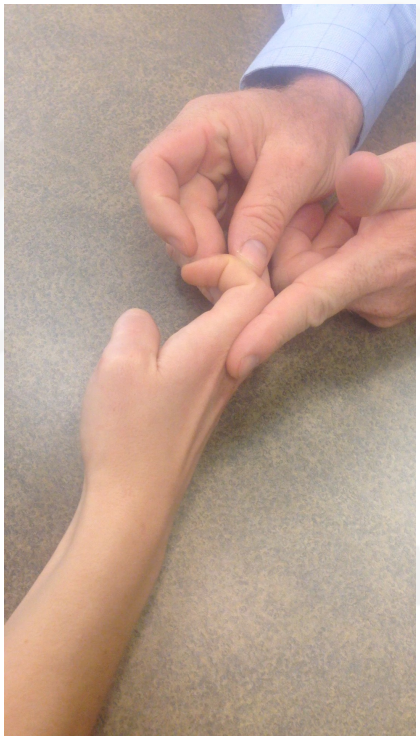

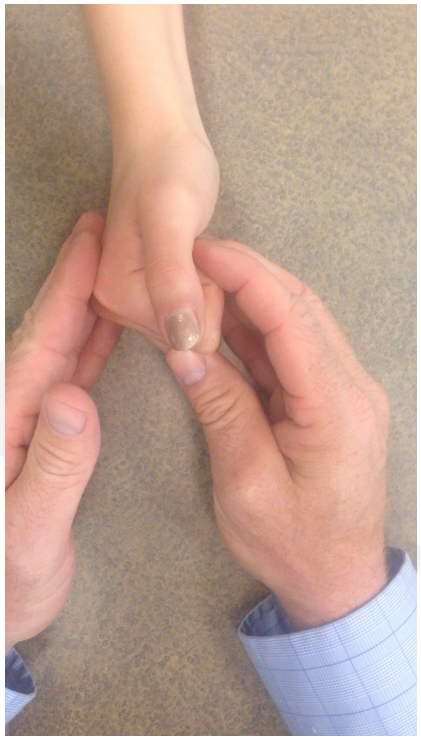

Teton
Hand & Upper Extremity
Conference Series LLC

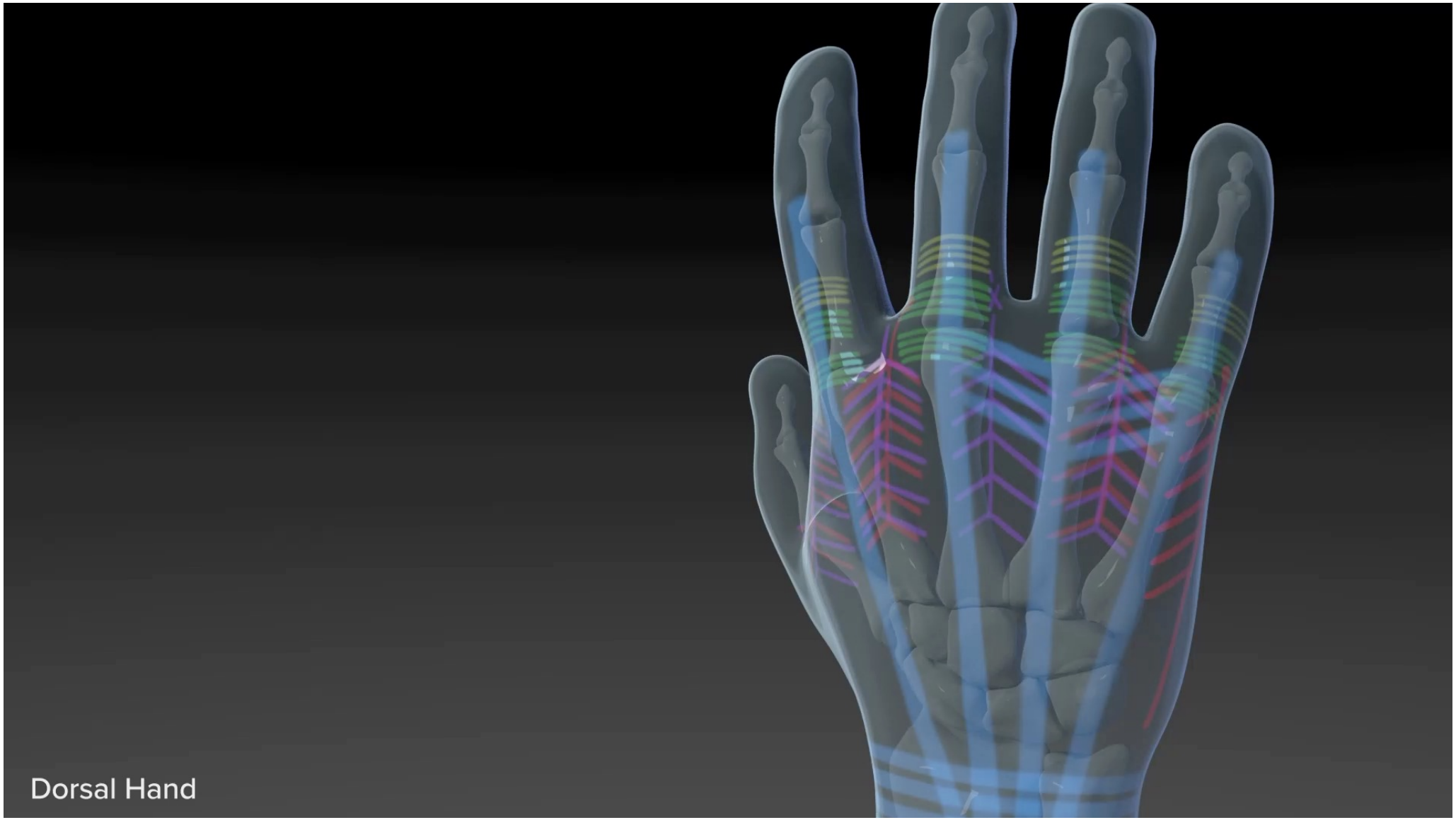
Dorsal Hand

Intrinsic Assessment, Anatomy, and Case Management

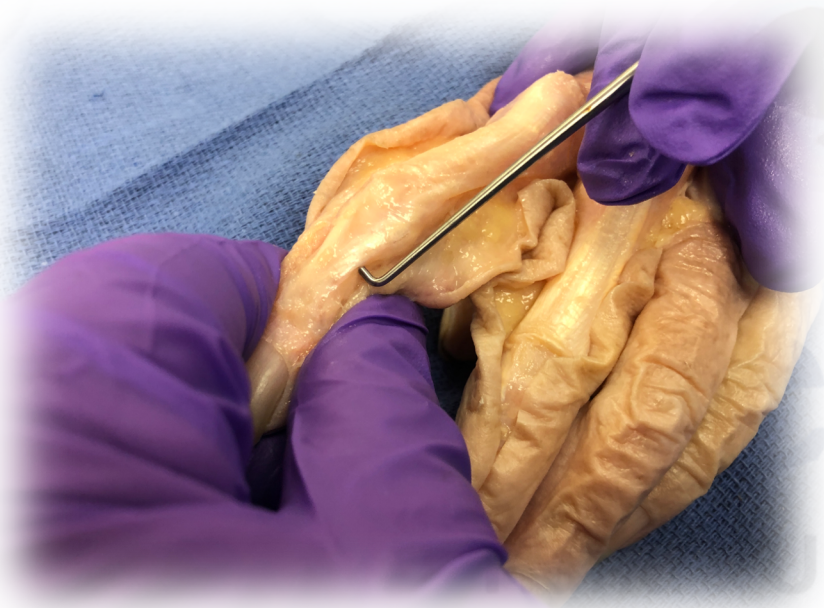



Conference Series LLC

Teton
Hand & Upper Extremity
Conference Series LLC

- Lateral band from intrinsics is joined by lateral slips of long extensors to form the conjoined lateral band

  At distal 1/3 of proximal phalanx

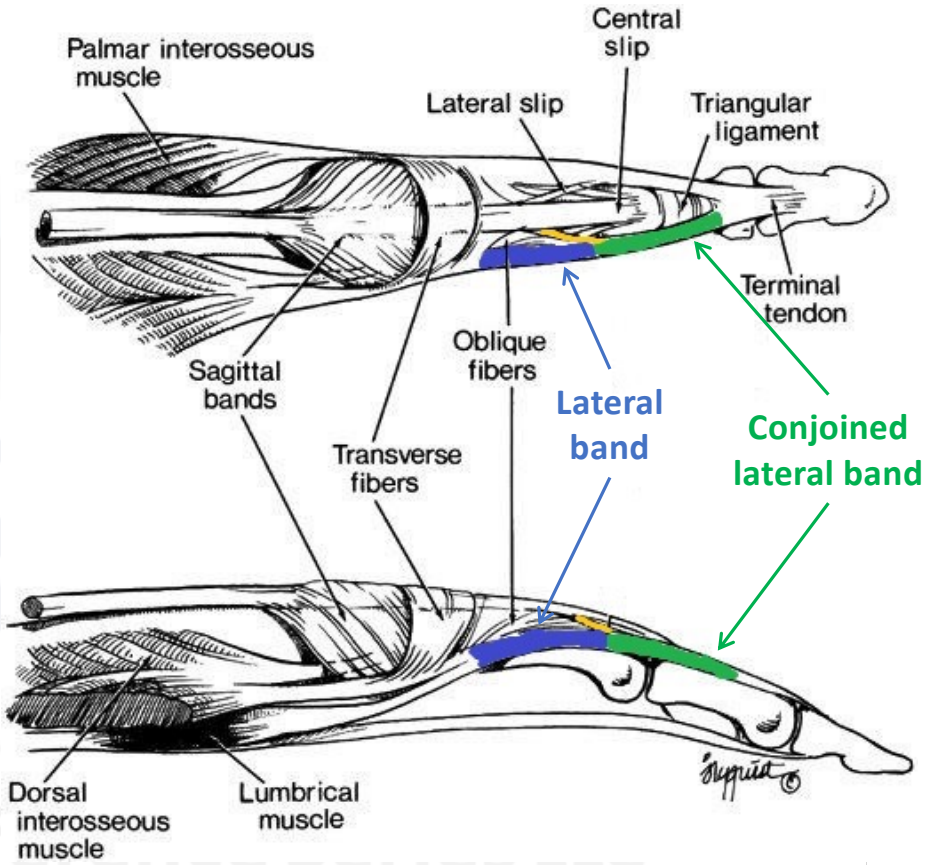

Teton
Hand & Upper Extremity Conference Series LLC

Lateral Slips



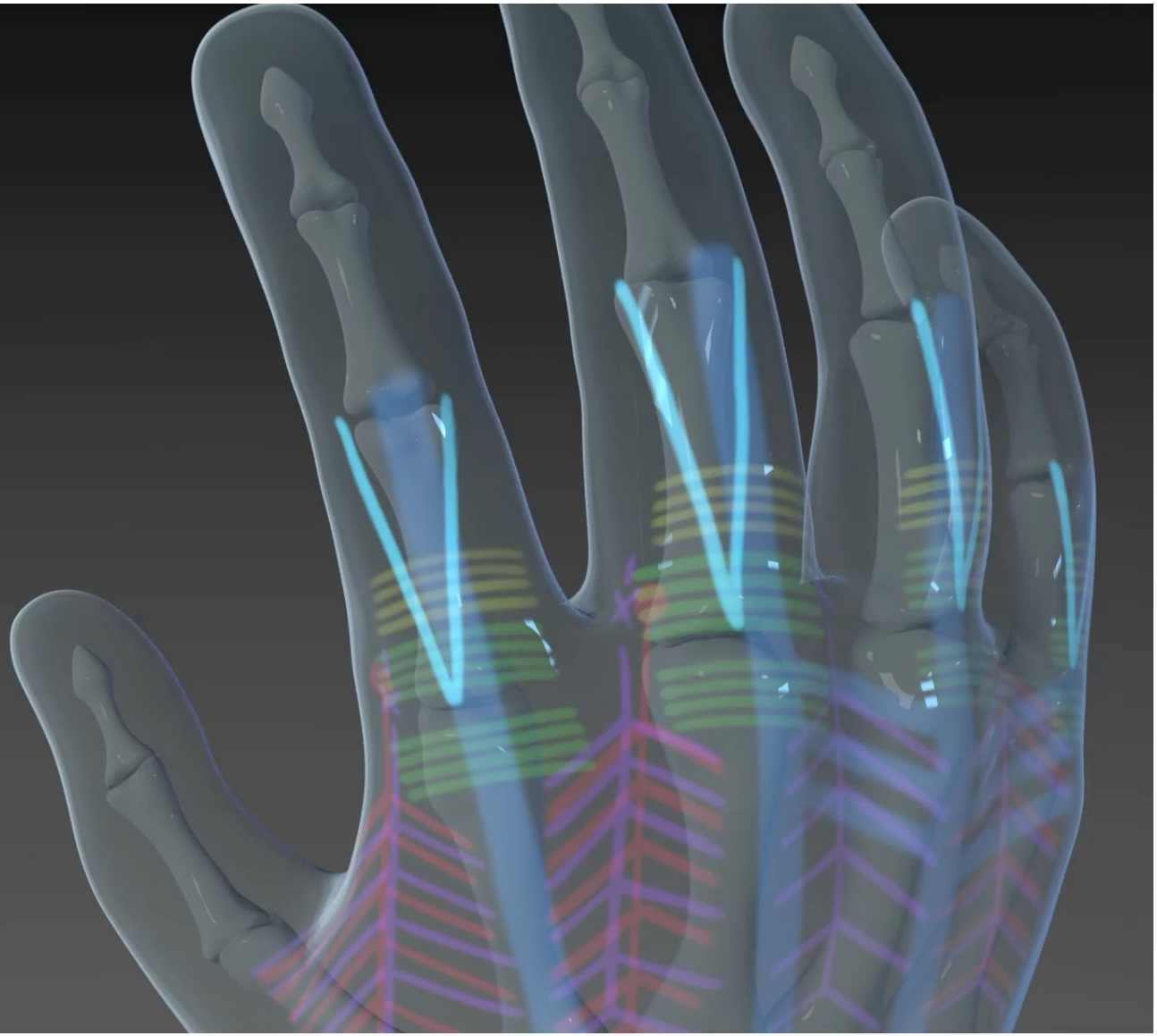

Dorsal Hand

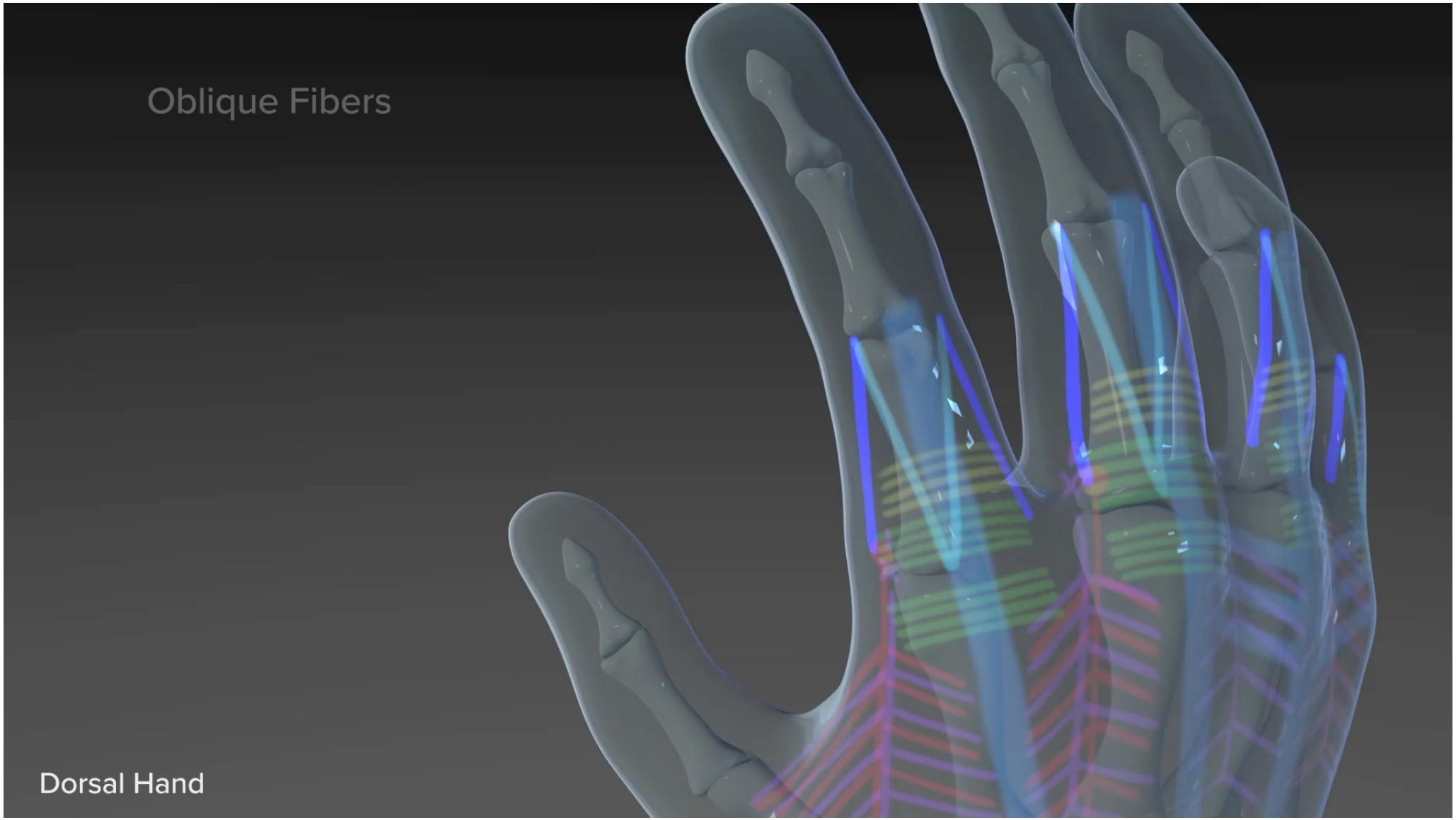
Oblique Fibers
Dorsal Hand

Intrinsic Assessment, Anatomy, and Case Management



Conference Series LLC

Teton
Hand & Upper Extremity
Conference Series LLC

Intrinsic Assessment, Anatomy, and Case Management



Conference Series LLC

Teton
Hand & Upper Extremity
Conference Series LLC

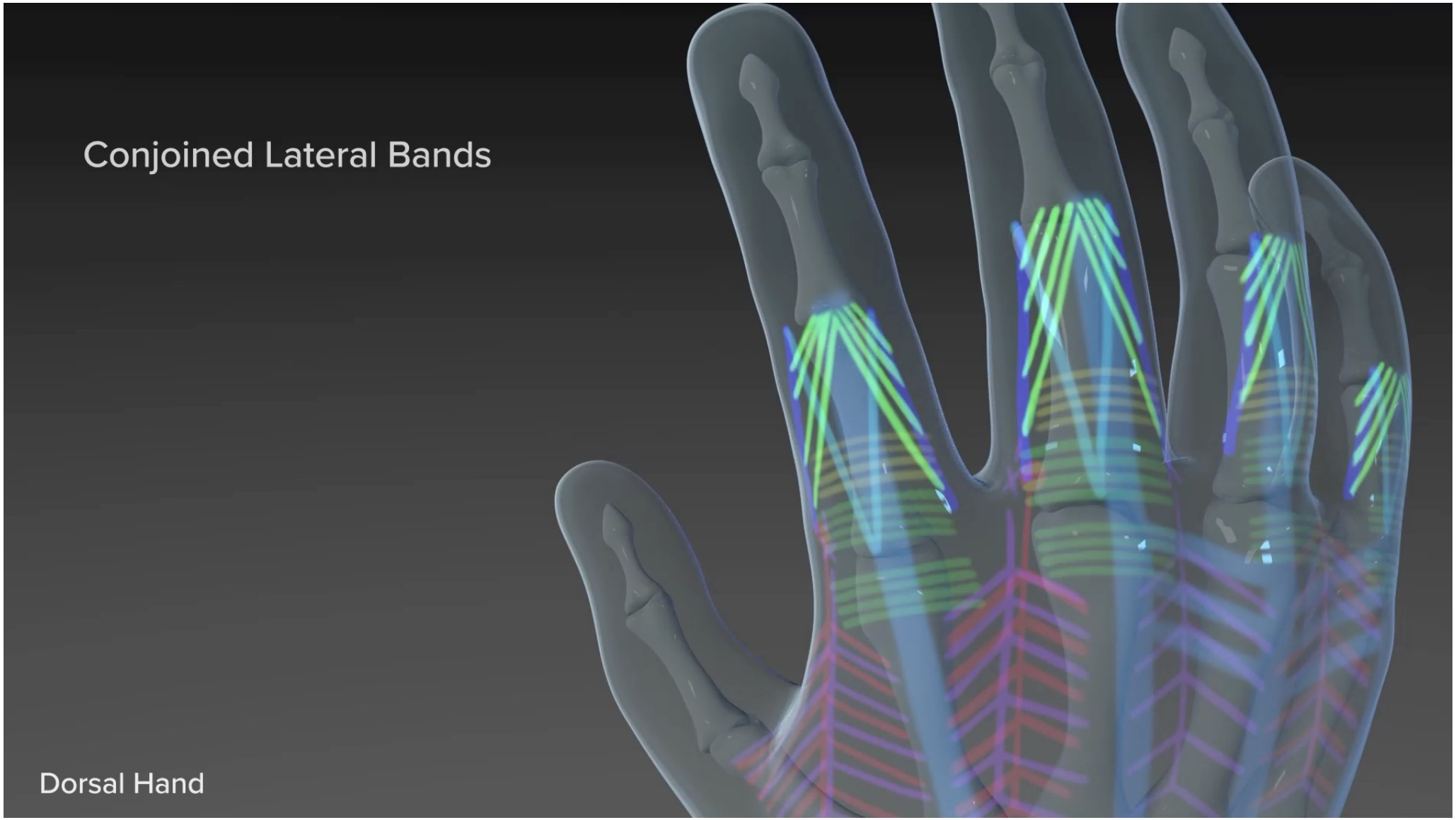
Conjoined Lateral Bands
Dorsal Hand

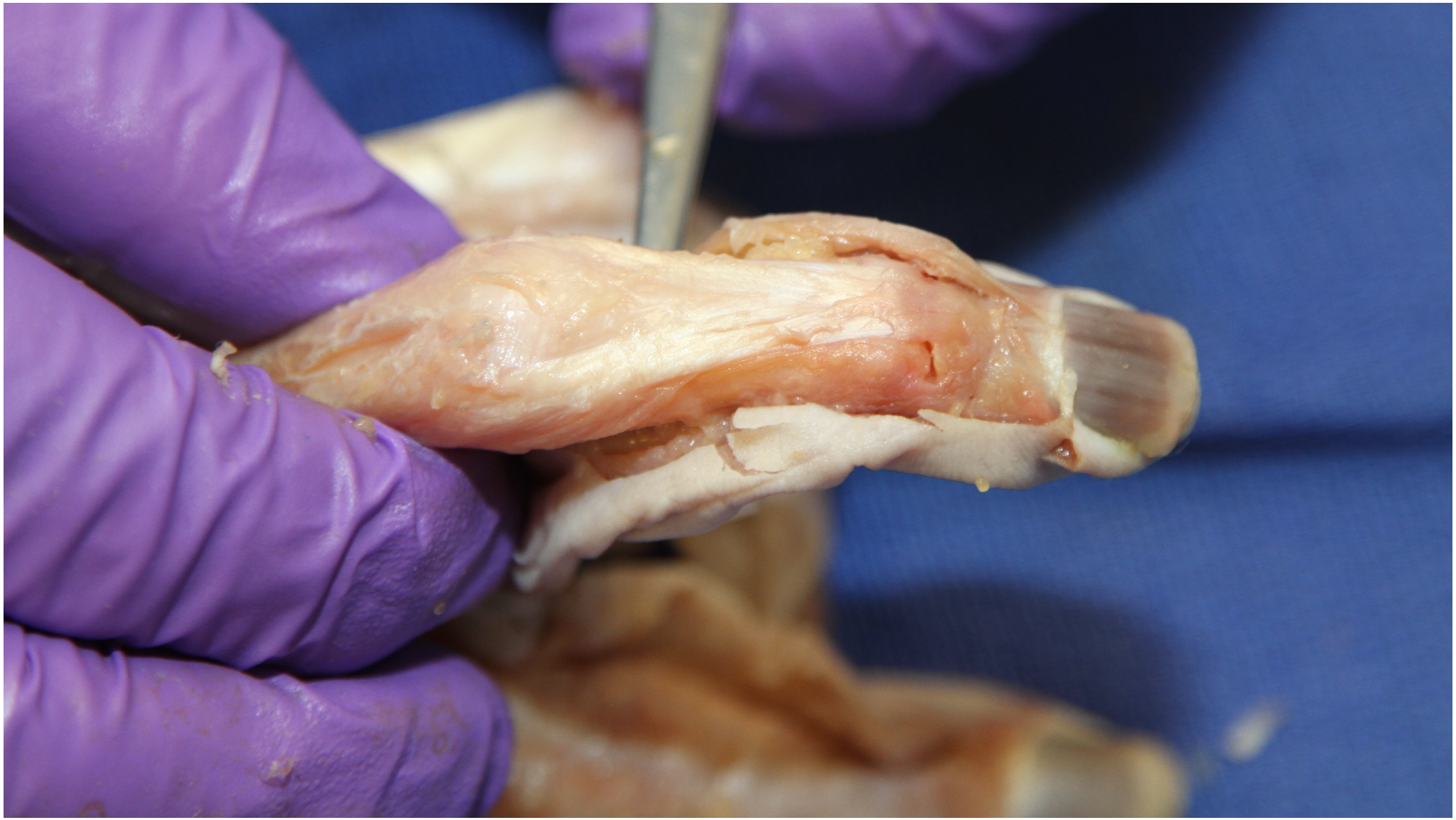

Intrinsic Assessment, Anatomy, and Case Management



Conference Series LLC

Teton
Hand & Upper Extremity
Conference Series LLC

Terminal Tendon



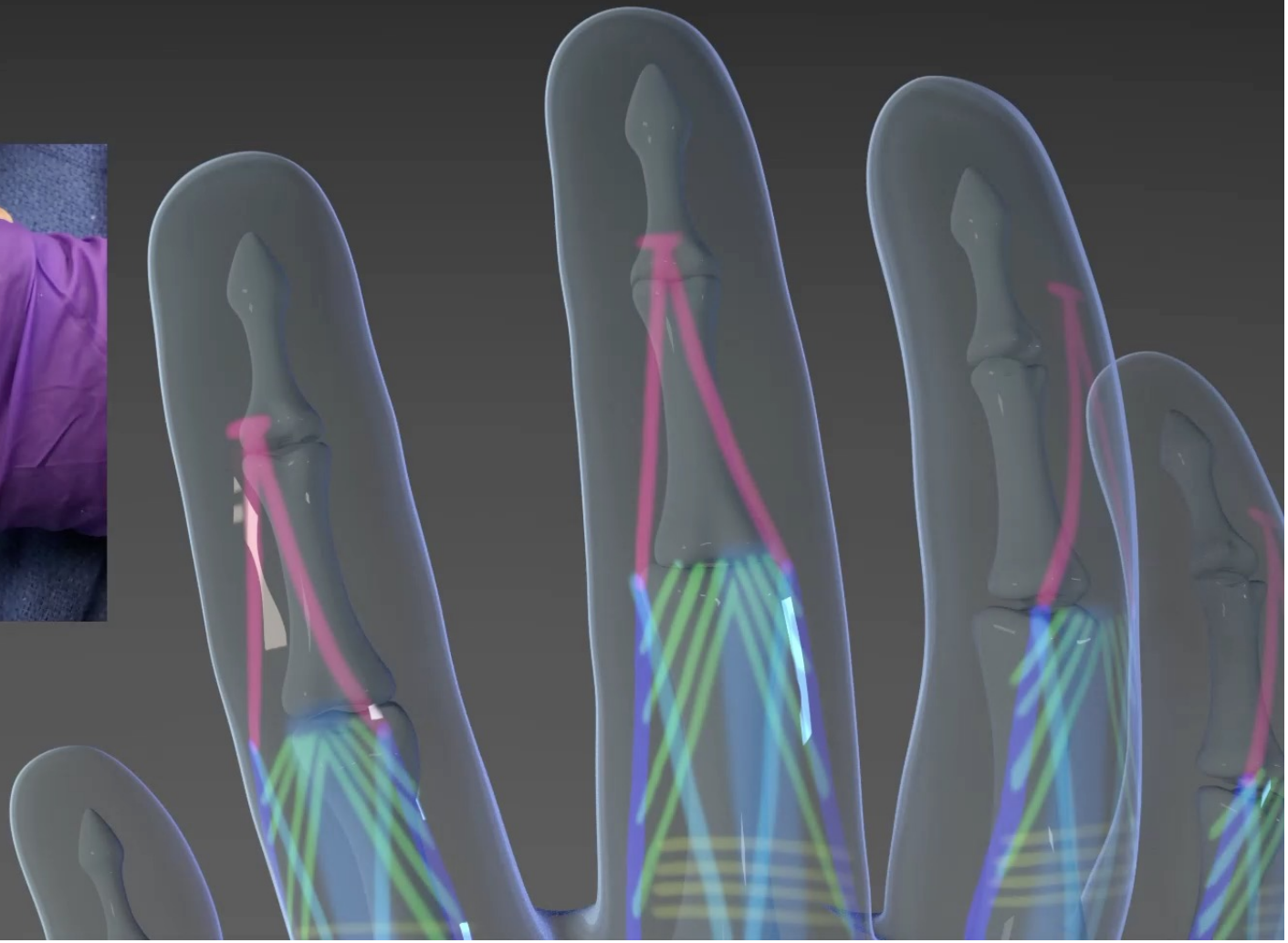

Dorsal Hand

Intrinsic Assessment, Anatomy, and Case Management



Conference Series LLC

Teton
Hand & Upper Extremity
Conference Series LLC

Intrinsic Assessment, Anatomy, and Case Management



Conference Series LLC

Teton
Hand & Upper Extremity
Conference Series LLC

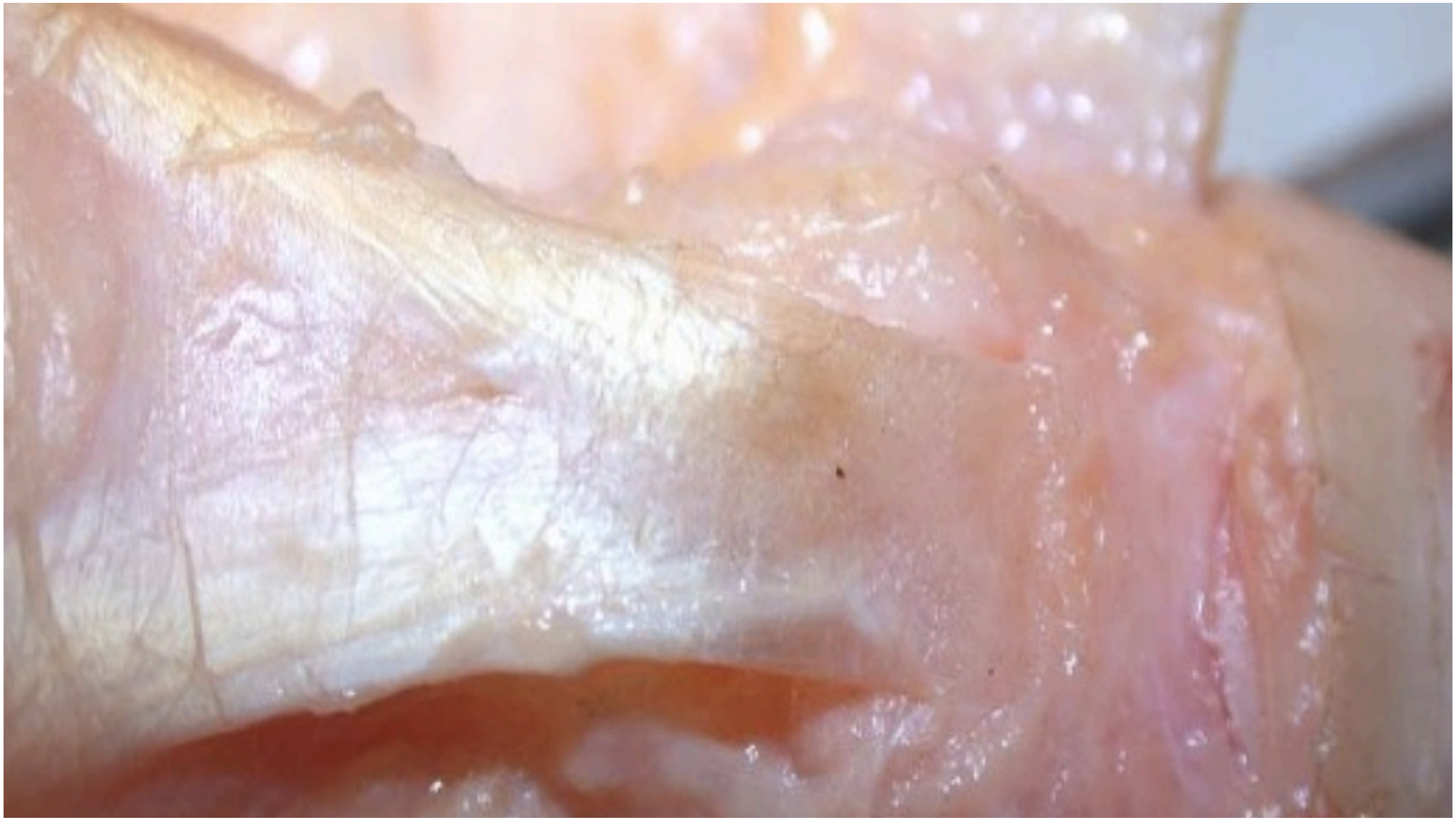


Teton
Hand & Upper Extremity
Conference Series LLC

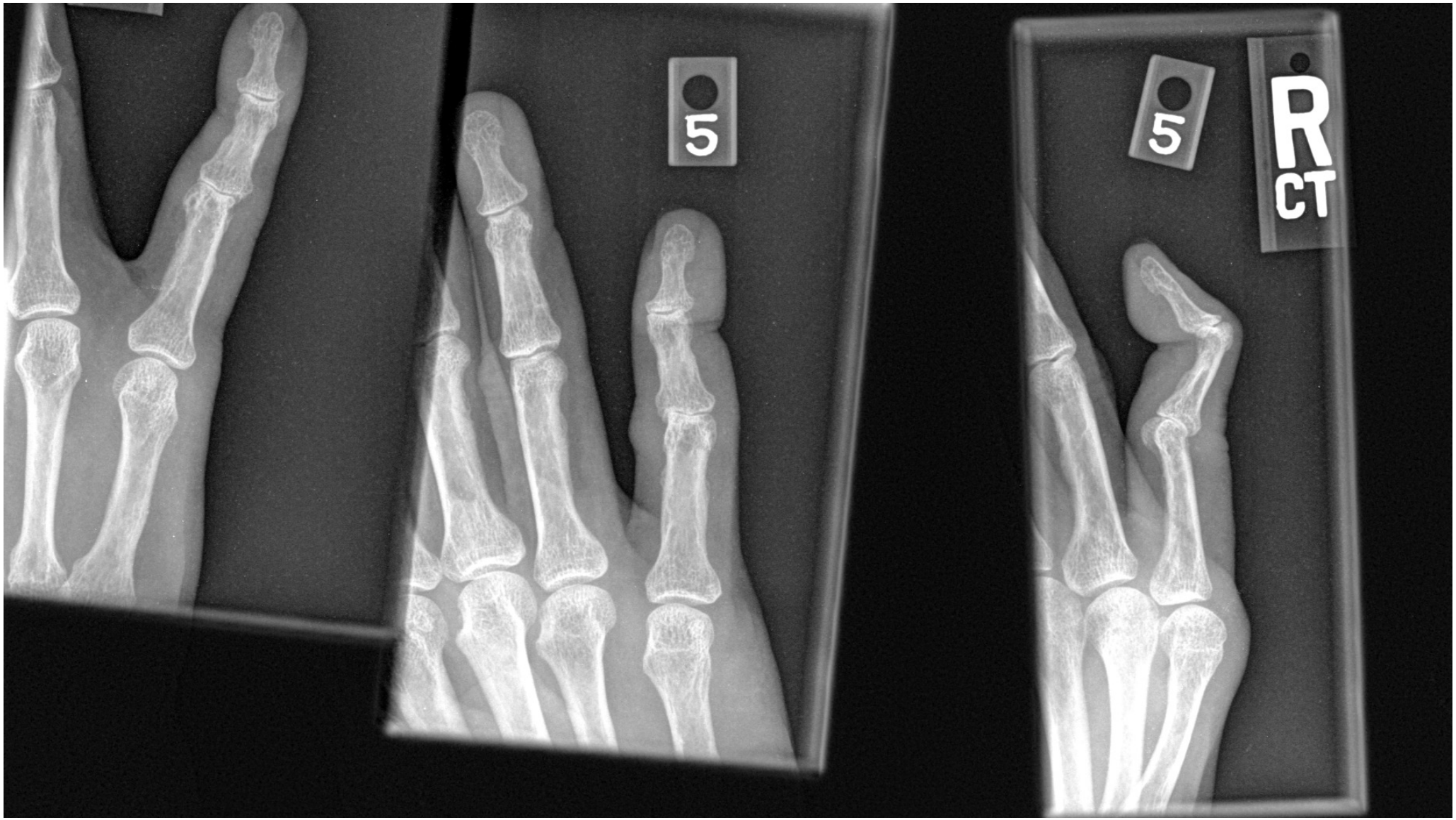
5
5
R
CT

Intrinsic Assessment, Anatomy, and Case Management

Hx: 72 y.o. right hand dominant male who presents with one day history of right little finger pain. He had immediate pain and deformity of his right little finger. DOI 11/19/2014. Mallet finger 20 years ago

Mechanism of injury: pt. tripped over flower pots on the concrete floor of his garage; landed on right SF.

Differential Dx: SF PIP joint dislocation; reduced at emergent care site, and buddy strapped

Teton
Hand & Upper Extremity
Conference Series LLC


Extremity
Series LLC

Intrinsic Assessment, Anatomy, and Case Management

- Following a mallet finger, the power of the long extensors and intrinsics may be disrupted
  - Power now concentrated on middle phalanx, pulling PIP into hyperextension



Hand & Upper Extremity
Conference Series LLC

Teton
Hand & Upper Extremity
Conference Series LLC

Intrinsic Assessment, Anatomy, and Case Management

- **Swan Neck Deformity:** conjoined lateral bands slipping dorsally
  - Hyperextension of PIP
  - Flexion of DIP



Teton Hand & Upper Extremity Conference Series LLC

Intrinsic Assessment, Anatomy, and Case Management

- Volar subluxation of P1 at MCP joint may increase the pull on the central slip



Teton
Hand & Upper Extremity
Conference Series LLC

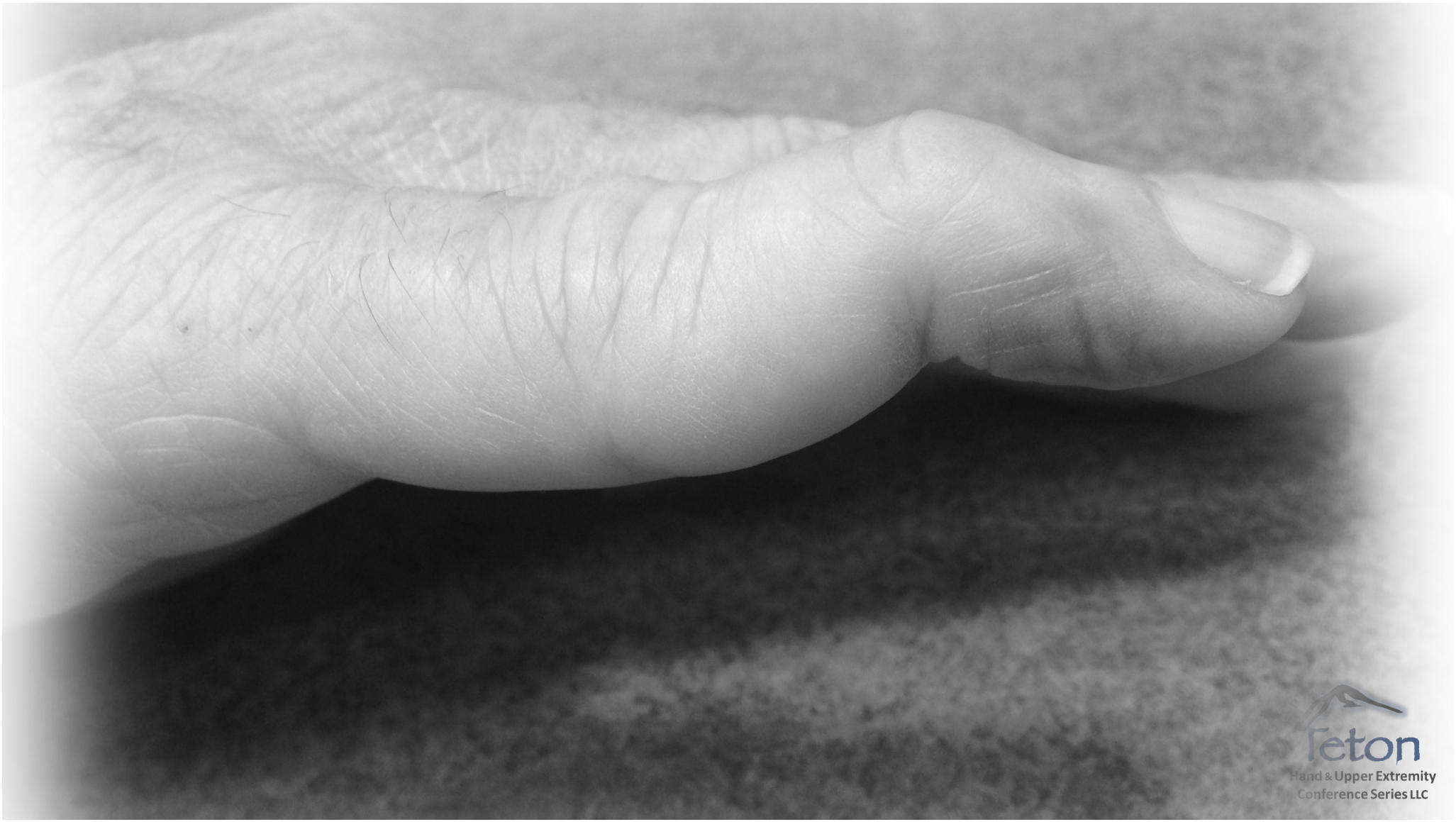
Teton
Hand & Upper Extremity
Conference Series LLC

Intrinsic Assessment, Anatomy, and Case Management

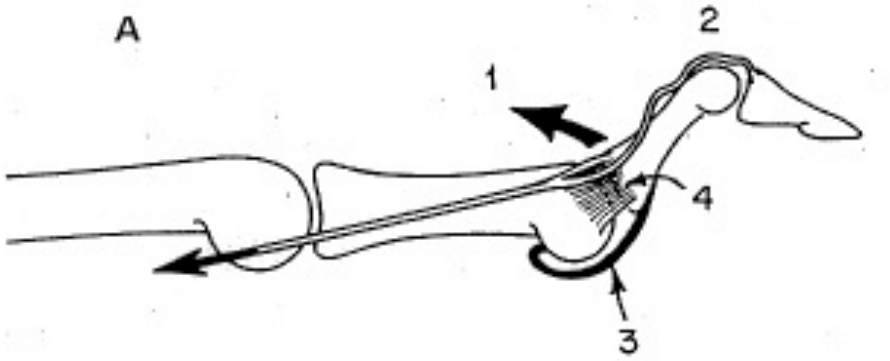

4 principle abnormalities that must be corrected:

- Tight intrinsics
- Dropped terminal phalanx
- Lax volar plate
- Contracted collateral ligaments at the PIP joint

Teton
Hand & Upper Extremity
Conference Series LLC

Intrinsic Assessment, Anatomy, and Case Management

- Correct deformity or developing deformity
- DIP extension Orthosis: approximate ends of terminal tendon
- PIP flexion orthosis: prevent lateral bands from riding dorsally; thus exacerbating swan neck deformity

Conference Series LLC

Teton
Hand & Upper Extremity
Conference Series LLC

Intrinsic Assessment, Anatomy, and Case Management

Diagnoses: right swan neck deformity from generalist

Order: OT/PT eval & Tx

"Hand-based 5th finger splint with PIP in flexion and DIP in extension; possibly evaluate for finger based splinting as above for showering"



Teton
Hand & Upper Extremity
Conference Series LLC






NEW



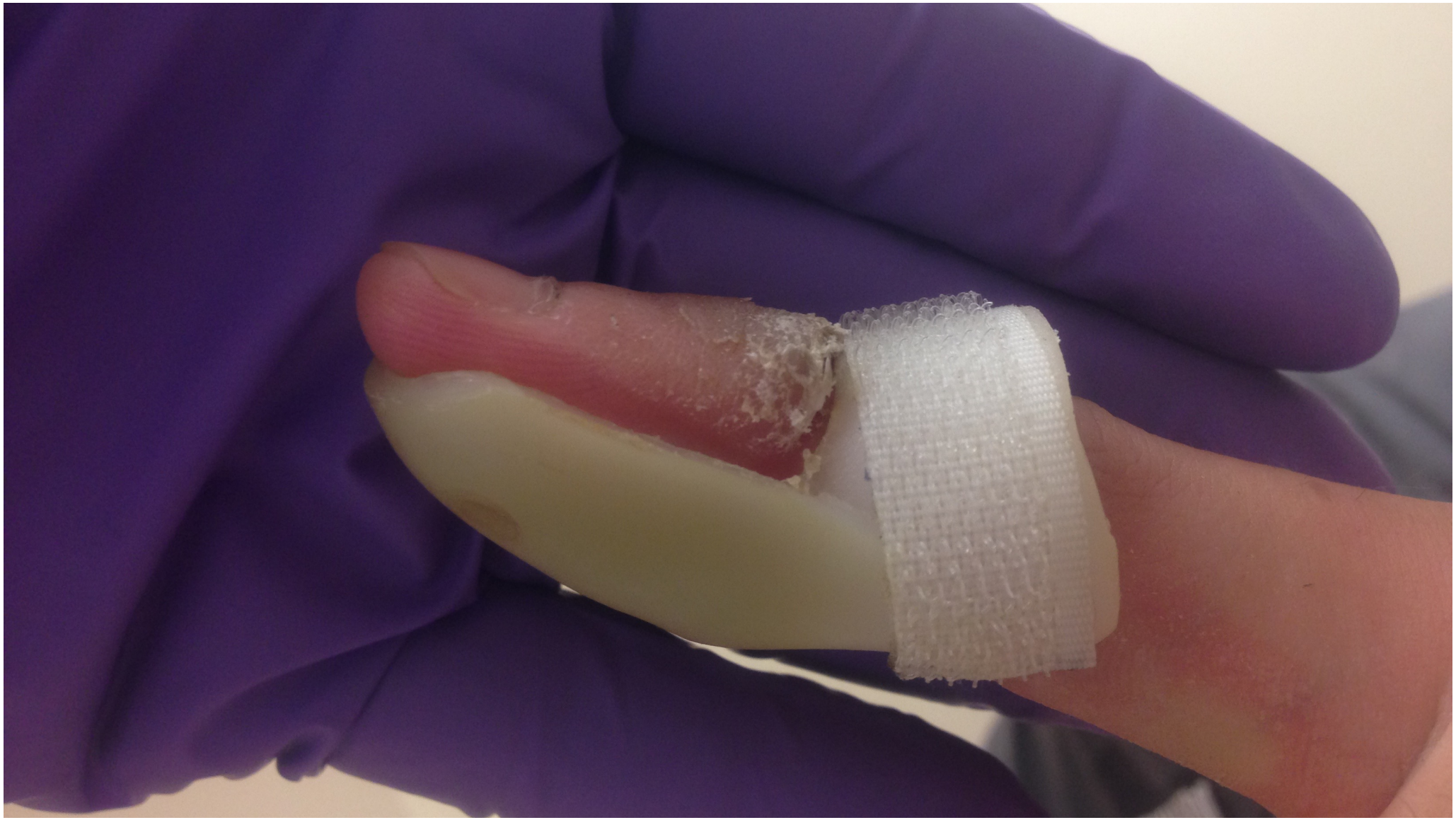






PLUS

Intrinsic Assessment, Anatomy, and Case Management

5th

Section:

Static Stabilizers: Oblique retinacular ligament (ORL), Transverse retinacular ligament (TRL), Triangular ligament (TL)

Hand & Upper Extremity
Conference Series LLC

Teton
Hand & Upper Extremity
Conference Series LLC

Intrinsic Assessment, Anatomy, and Case Management

3 sets of ligaments *(static stabilizers)* assist in controlling **POSITION** of dorsal apparatus on the finger

Oblique retinacular ligament	Transverse retinacular ligament	Triangular ligament

Conference Series LLC

Teton
Hand & Upper Extremity
Conference Series LLC

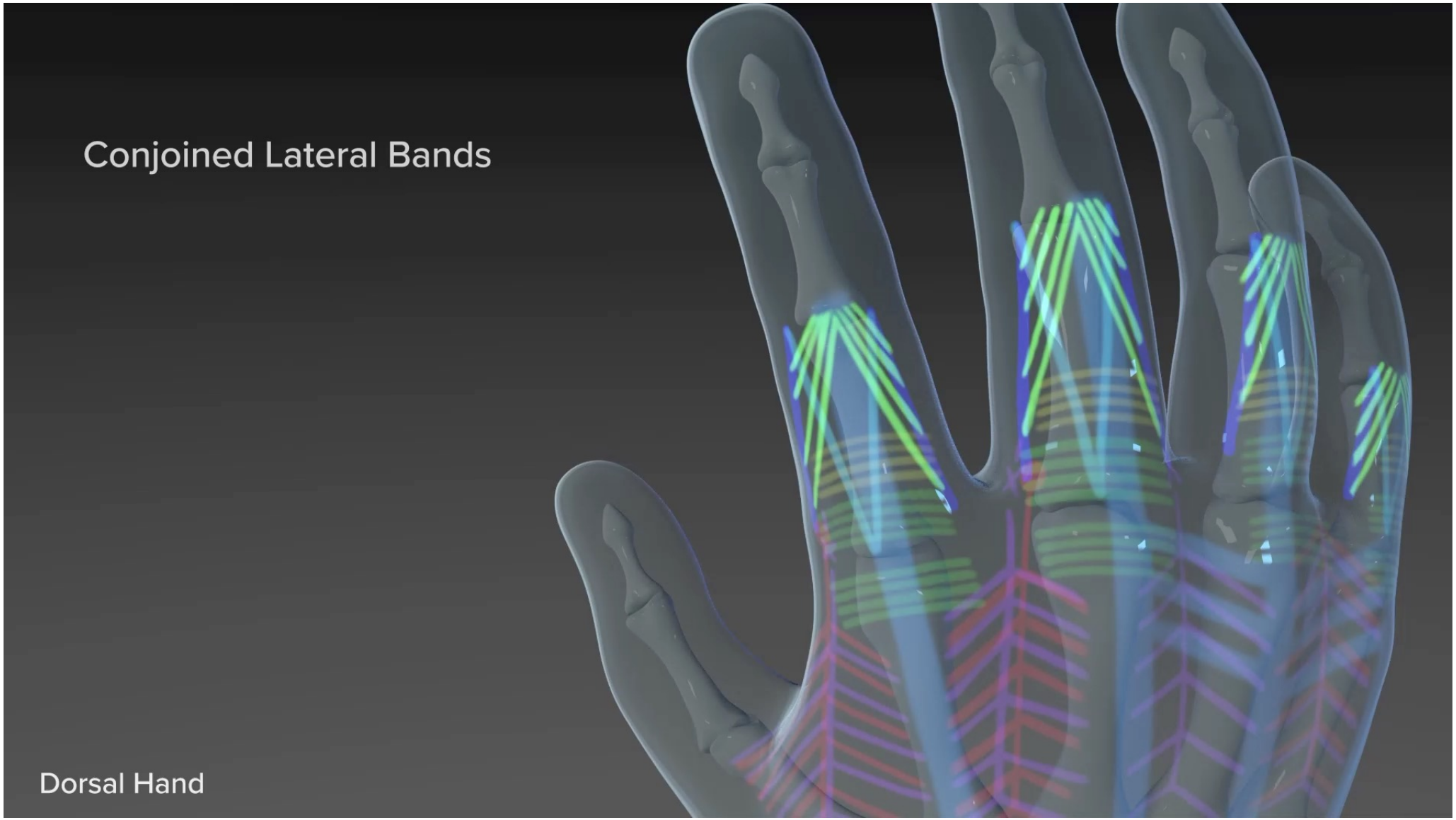
Conjoined Lateral Bands
Dorsal Hand

Intrinsic Assessment, Anatomy, and Case Management

Runs from the flexor pulley and inserts at terminal tendon

Volar to the PIP axis terminating dorsal to DIP

Action: When PIP extends:

- ORL tightens and pulls the terminal tendon proximally to cause DIP extension

"Link ligament"

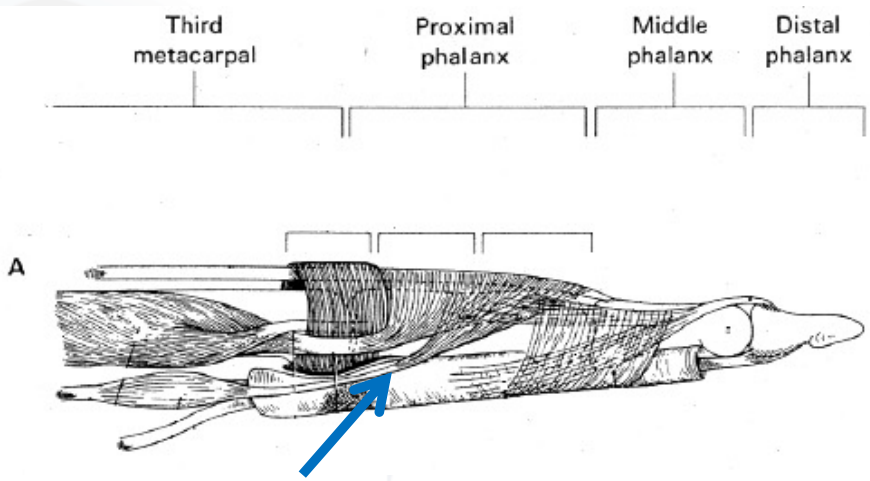

Hand & Upper Extremity Conference Series LLC

Intrinsic Assessment, Anatomy, and Case Management

Runs from lateral edges of conjoined lateral bands to edge of flexor tendon sheath at PIP joint

Action: prevents **excessive dorsal dislocation** and "bowstringing" of the conjoined lateral bands when the PIP joint is extended

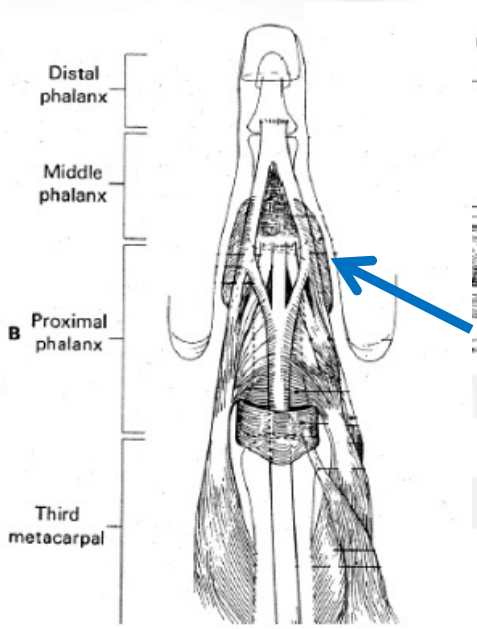

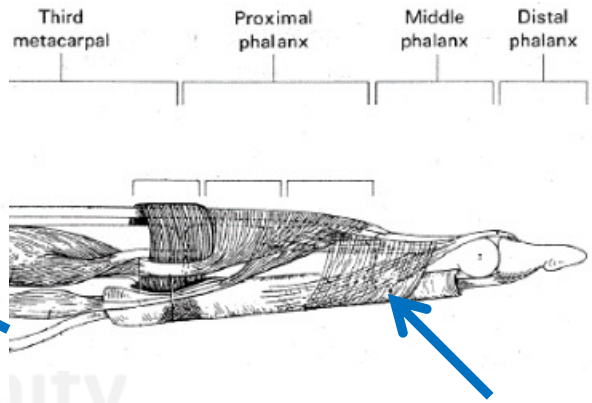

Teton
Hand & Upper Extremity Conference Series LLC

Transverse Retinacular Ligament



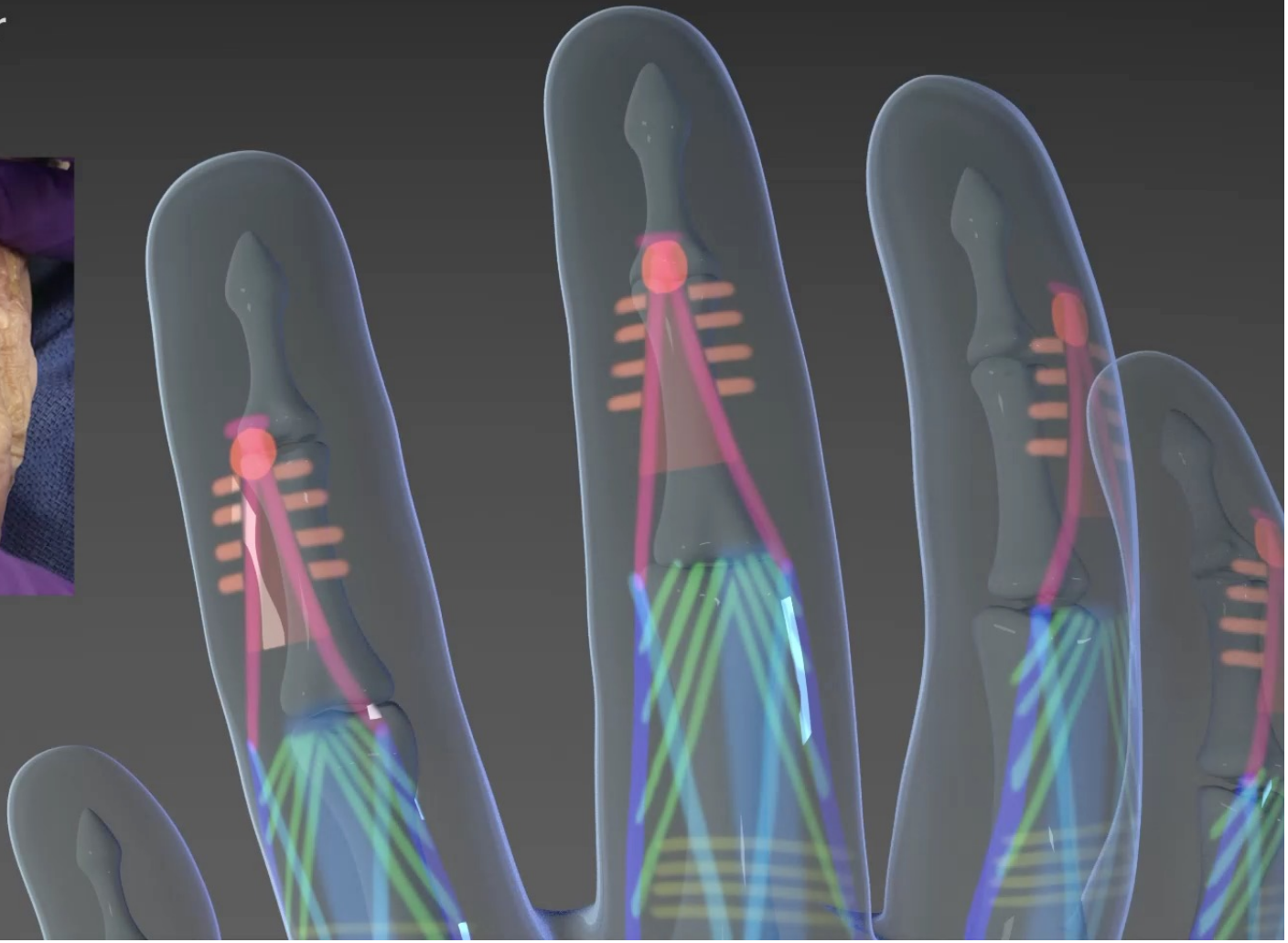

Dorsal Hand

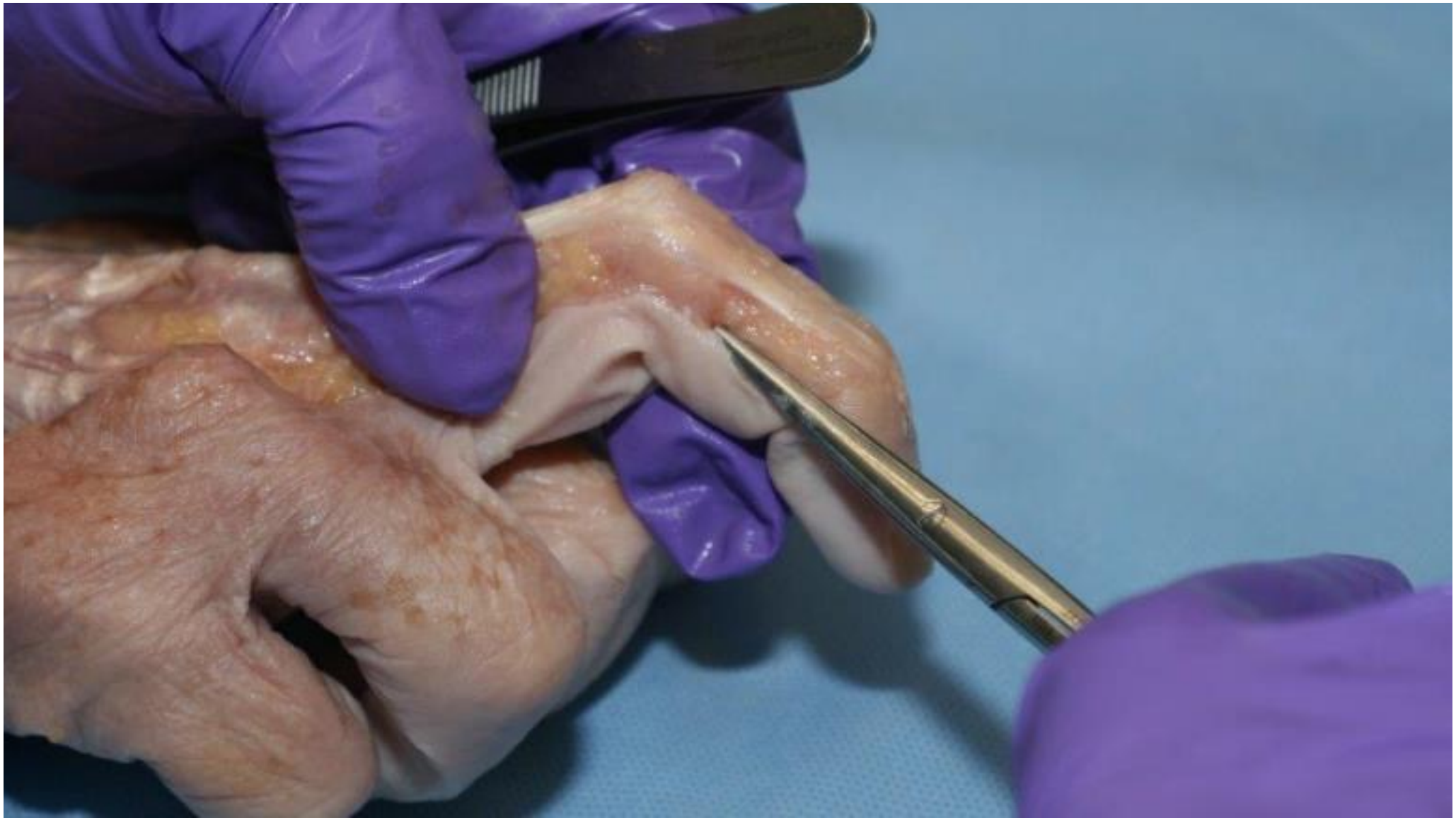

Triangular Ligament



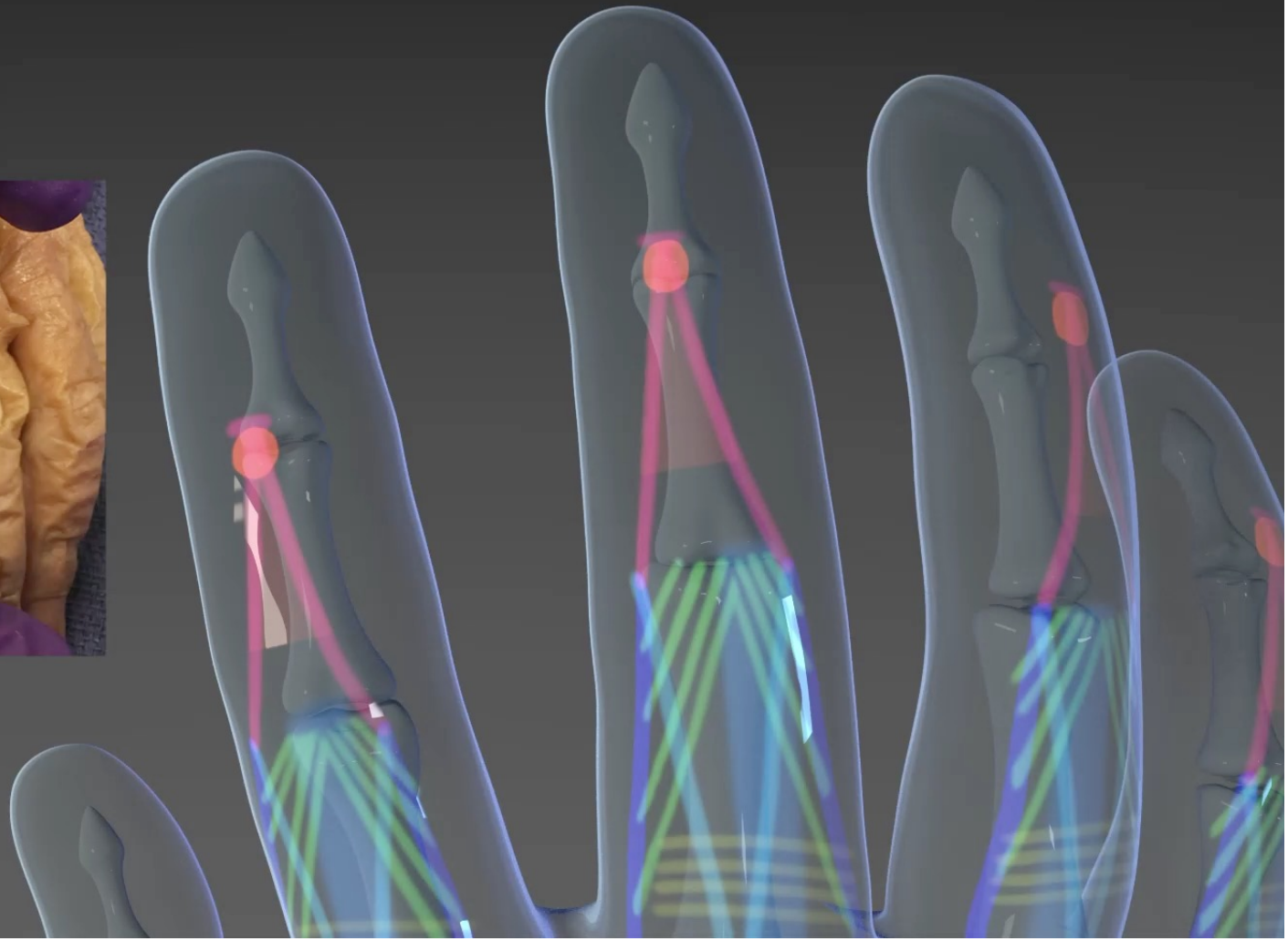

Dorsal Hand



Intrinsic Assessment, Anatomy, and Case Management

- Base: central slip attachment to middle phalanx
- Sides: conjoined lateral bands
- Apex: proximal edge of the terminal tendon

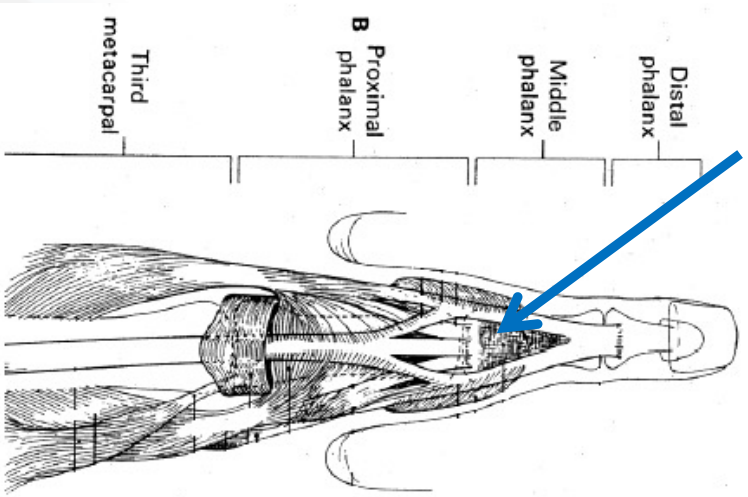

Teton
Hand & Upper Extremity Conference Series LLC

Intrinsic Assessment, Anatomy, and Case Management

Action: prevents excessive volar subluxation of the conjoined lateral bands with flexion of the middle phalanx

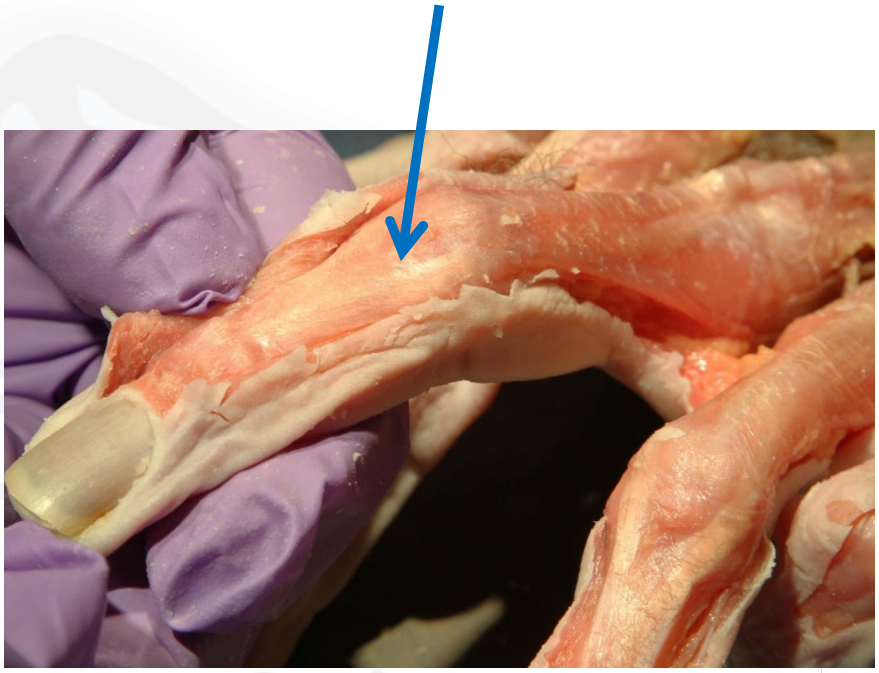

Teton
Hand & Upper Extremity
Conference Series LLC

Intrinsic Assessment, Anatomy, and Case Management

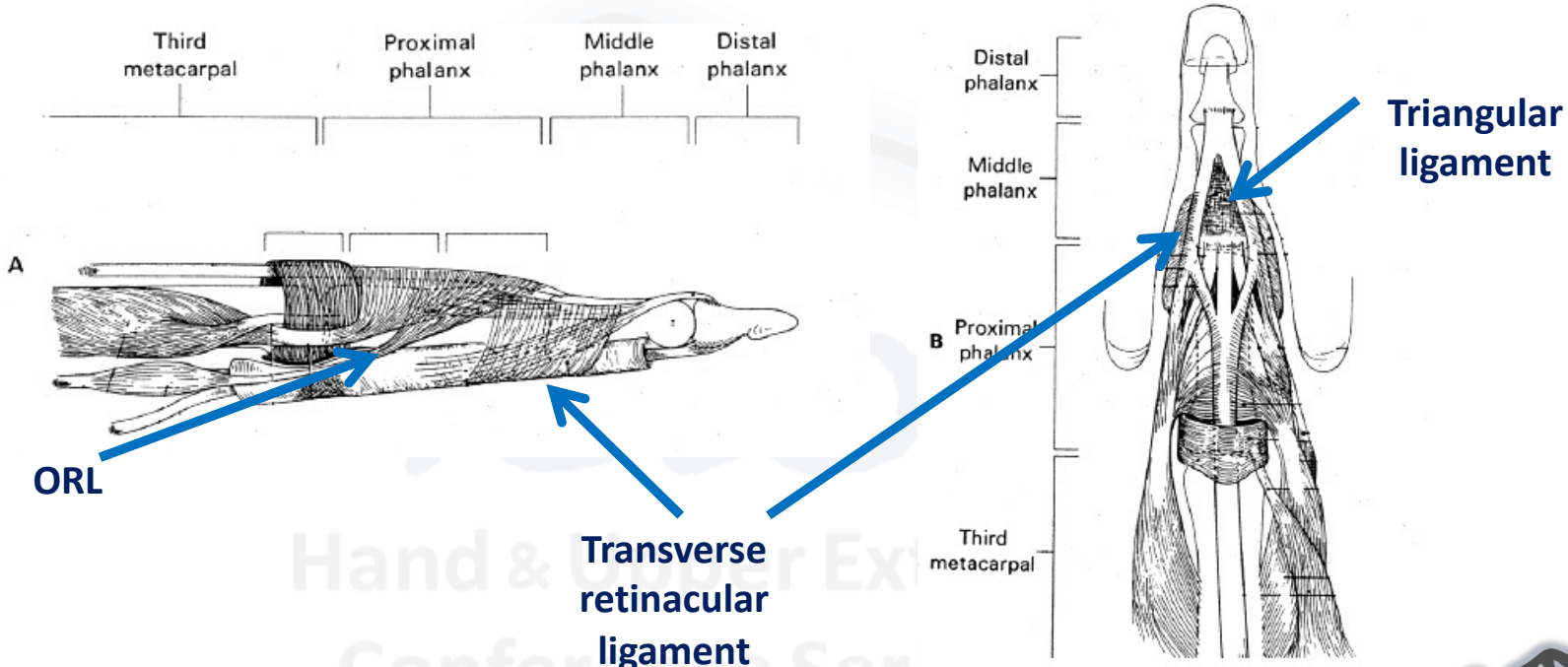

Hand & Upper Extremity Conference Series LLC

Intrinsic Assessment, Anatomy, and Case Management







IF	MF	RF	SF
EDC & EI	EDC	EDC	EDC & EDM
SB, TF, OF	SB, TF, OF	SB, TF, OF	SB, TF, OF
same	same	same	same

Teton
Hand & Upper Extremity
Conference Series LLC



Teton
Hand & Upper Extremity
Conference Series LLC










Flex-MT

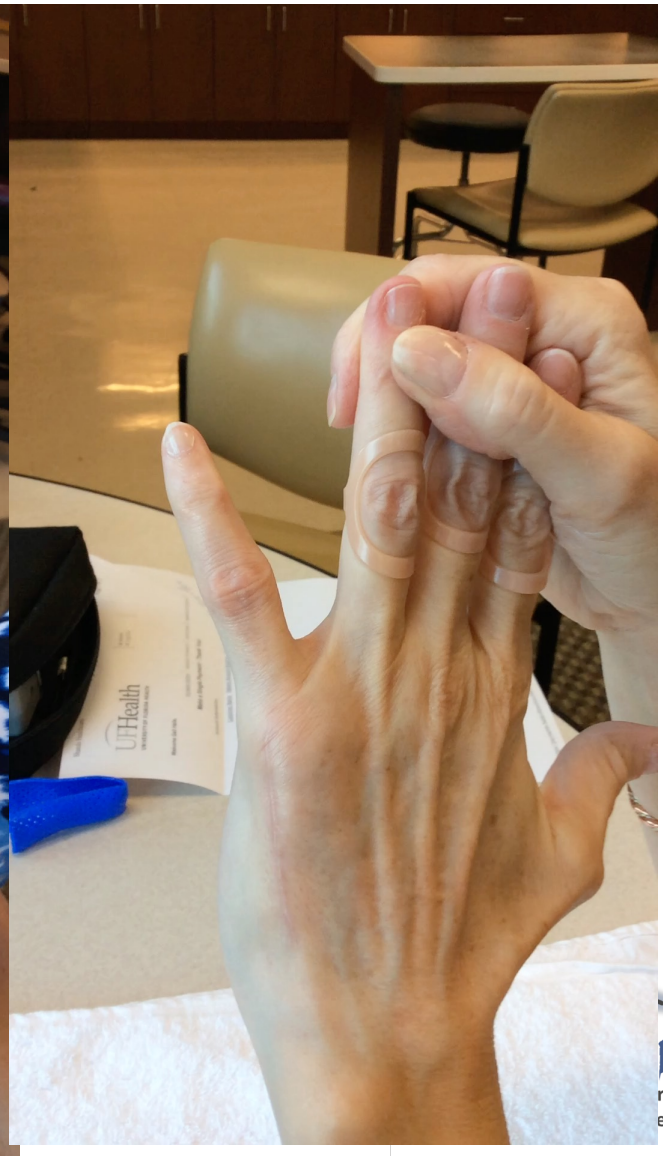
UFHealth



Teton
Hand & Upper Extremity
Conference Series LLC



Teton
Hand & Upper Extremity
Conference Series LLC



Intrinsic Assessment, Anatomy, and Case Management

6th Section

Drawing Lab:

Extensor Mechanism and Static Stabilizers

Hand & Upper Extremity Conference Series LLC

Teton
Hand & Upper Extremity
Conference Series LLC




OpticShop

Intrinsic Assessment, Anatomy, and Case Management

- Lateral Slips (EDC)
- Lateral bands
- Oblique fibers
- Conjoined Lateral Bands
- Terminal Tendon(s)
- Transverse Retinacular Ligaments
- Triangular Ligament

Teton
Hand & Upper Extremity
Conference Series LLC

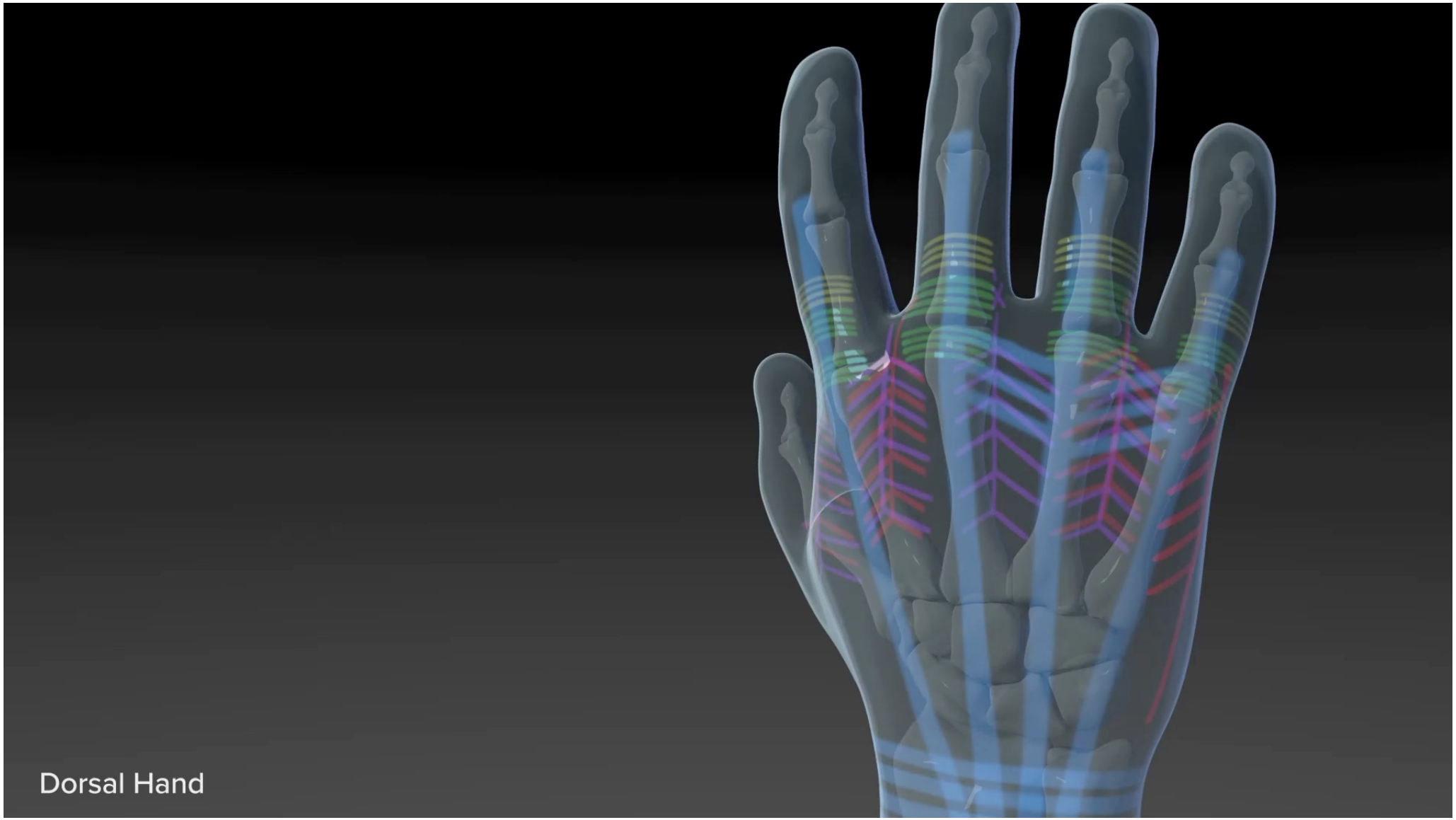
Dorsal Hand

Lateral Slips



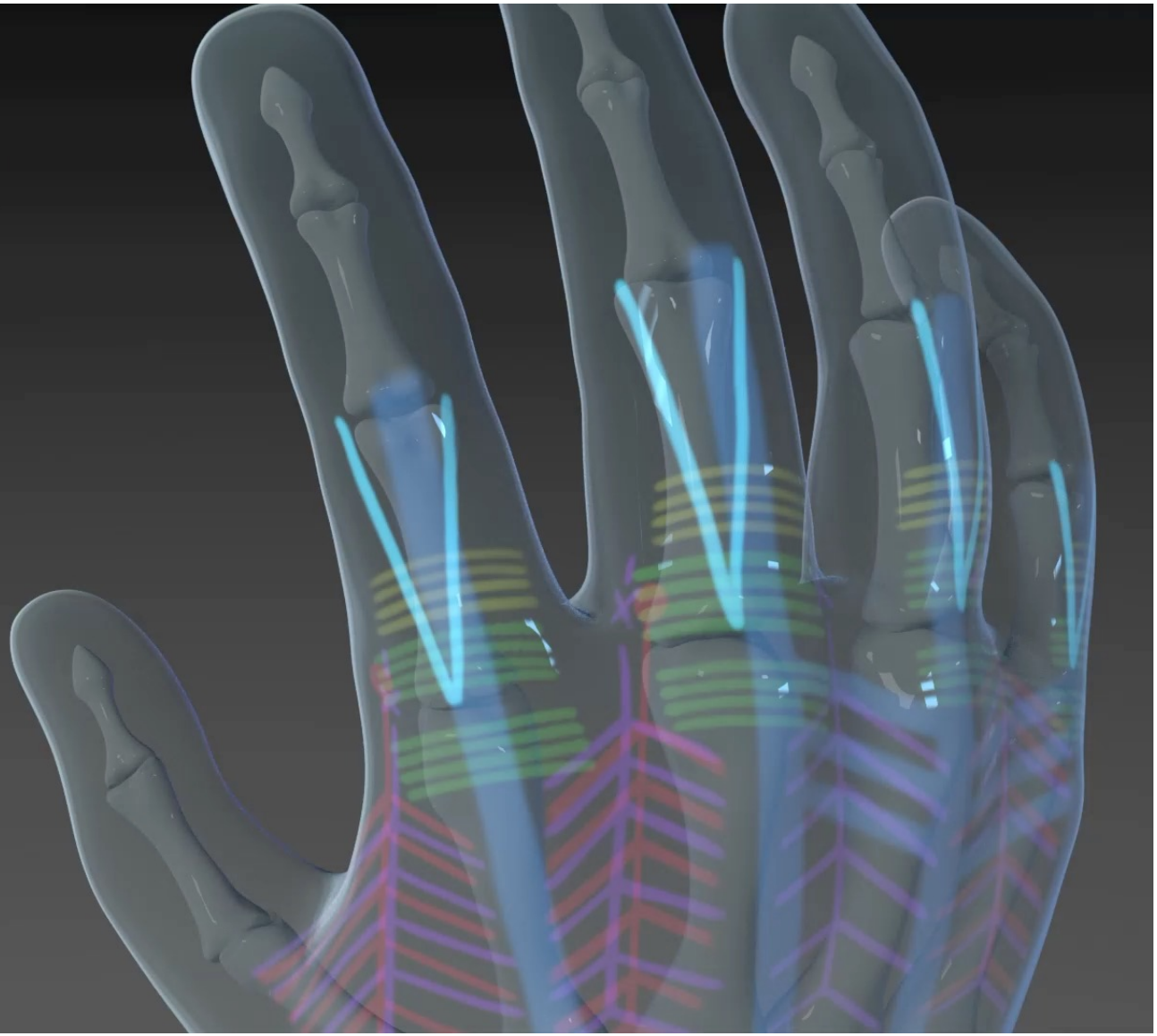

Dorsal Hand

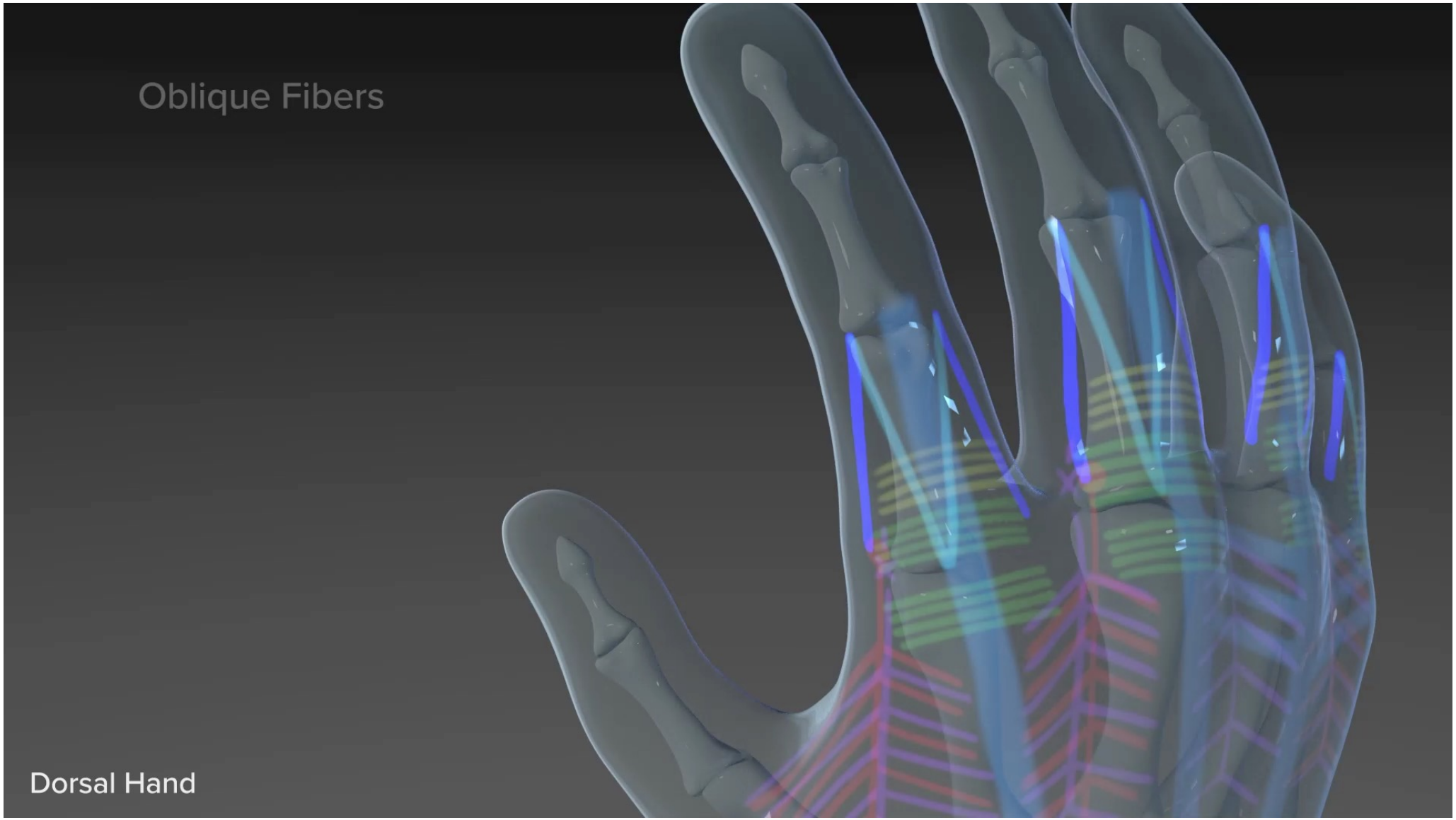
Oblique Fibers
Dorsal Hand

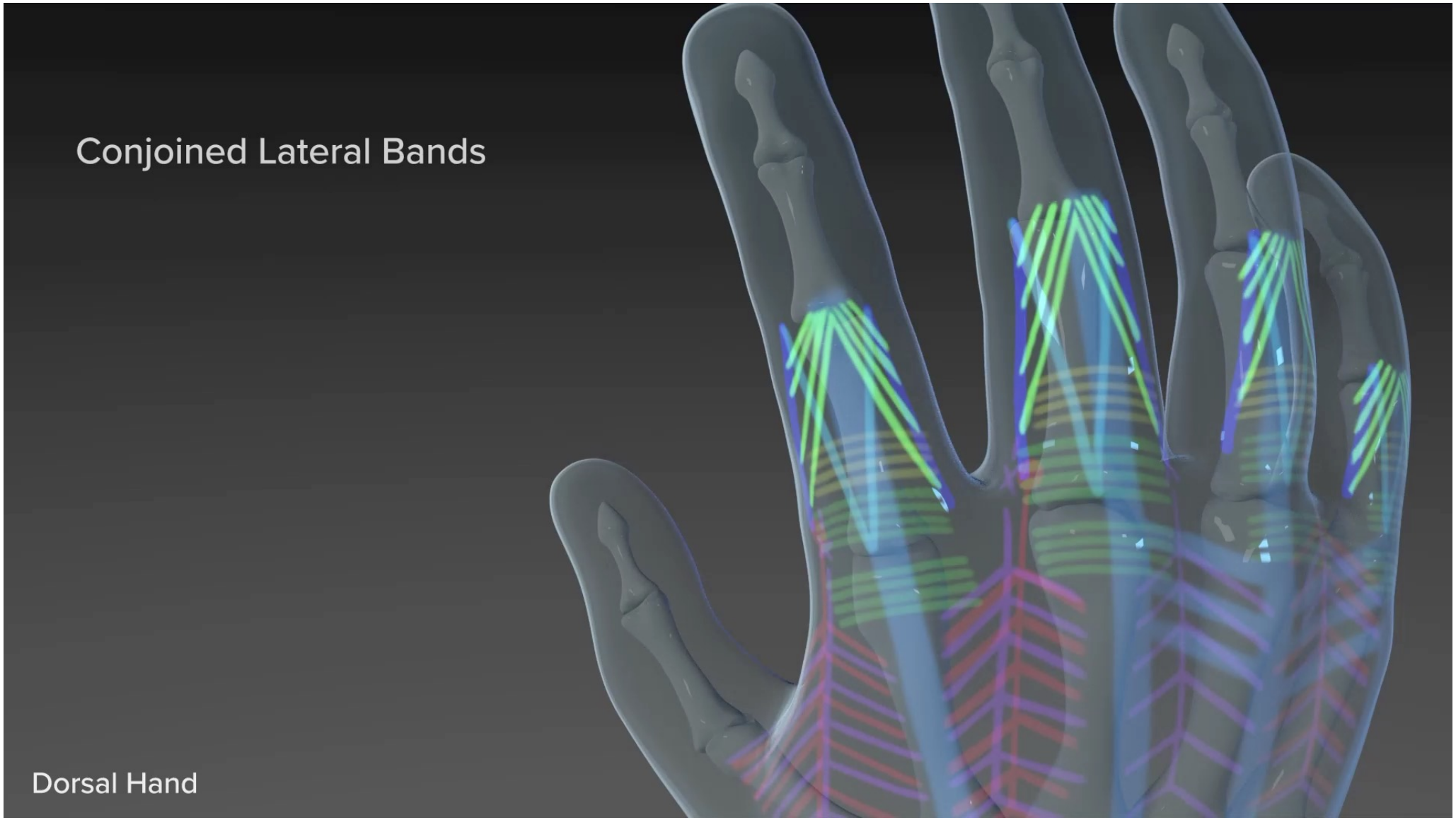
Conjoined Lateral Bands
Dorsal Hand

Terminal Tendon



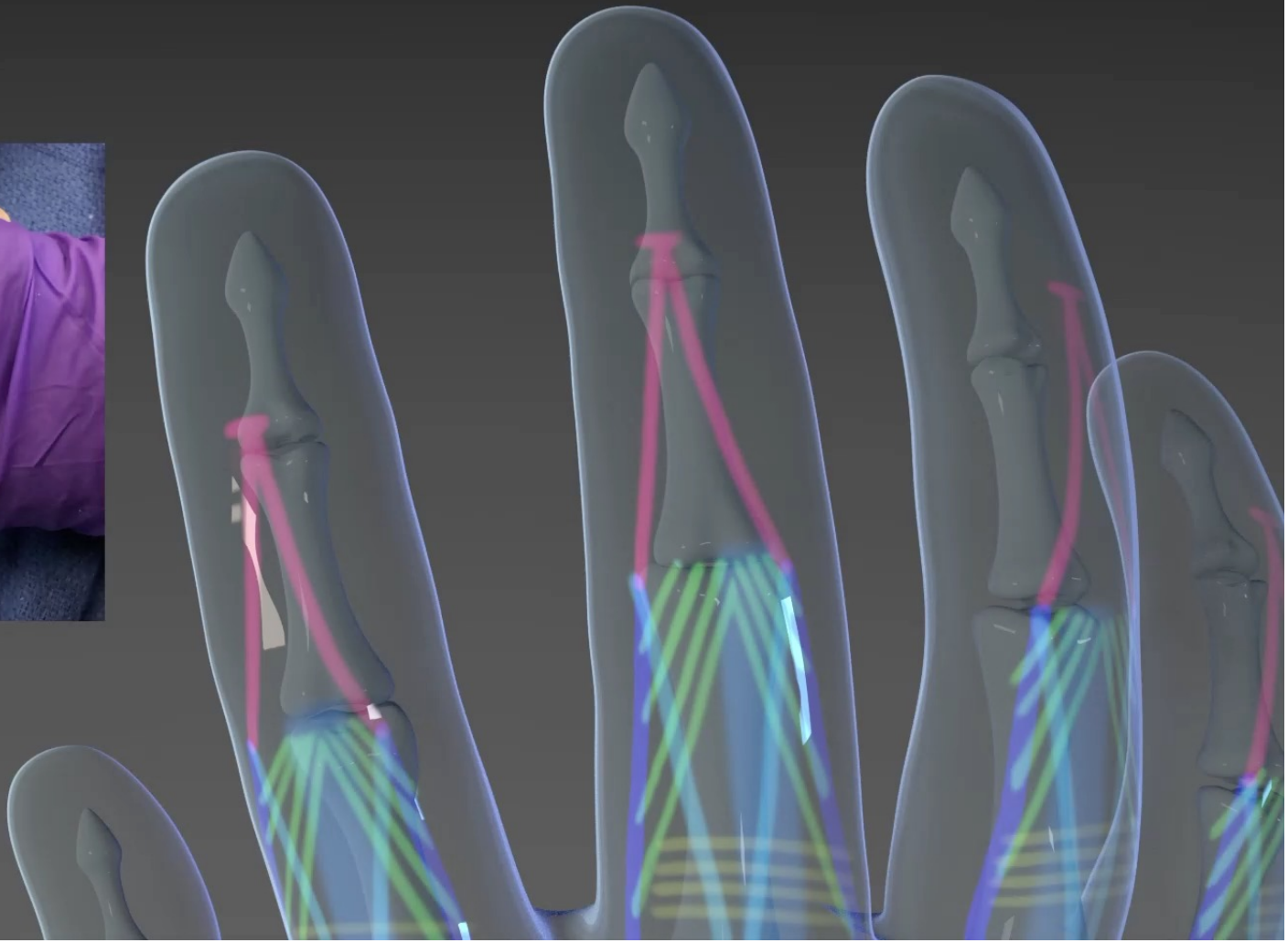

Dorsal Hand

Transverse Retinacular Ligament



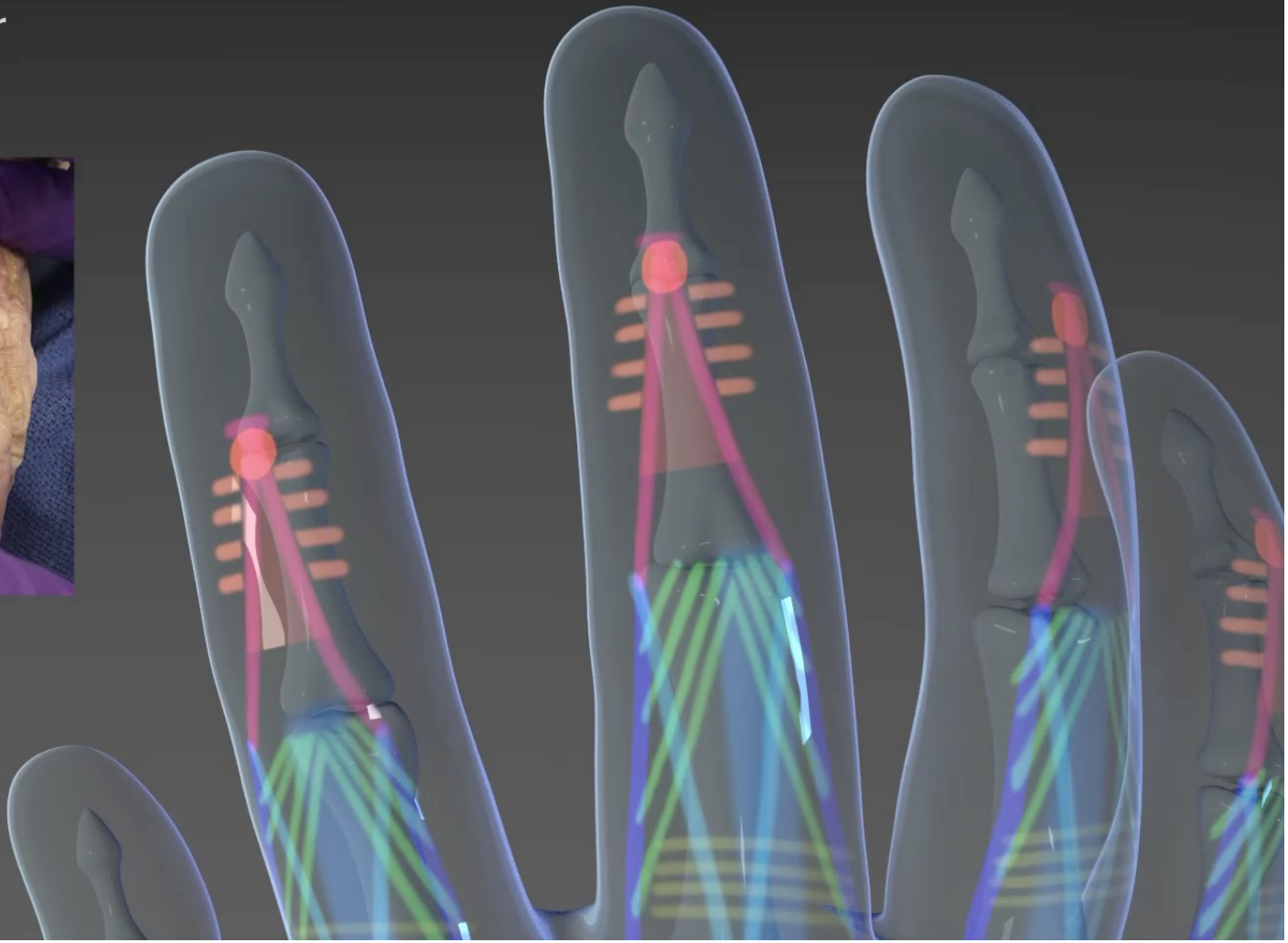

Dorsal Hand

Triangular Ligament



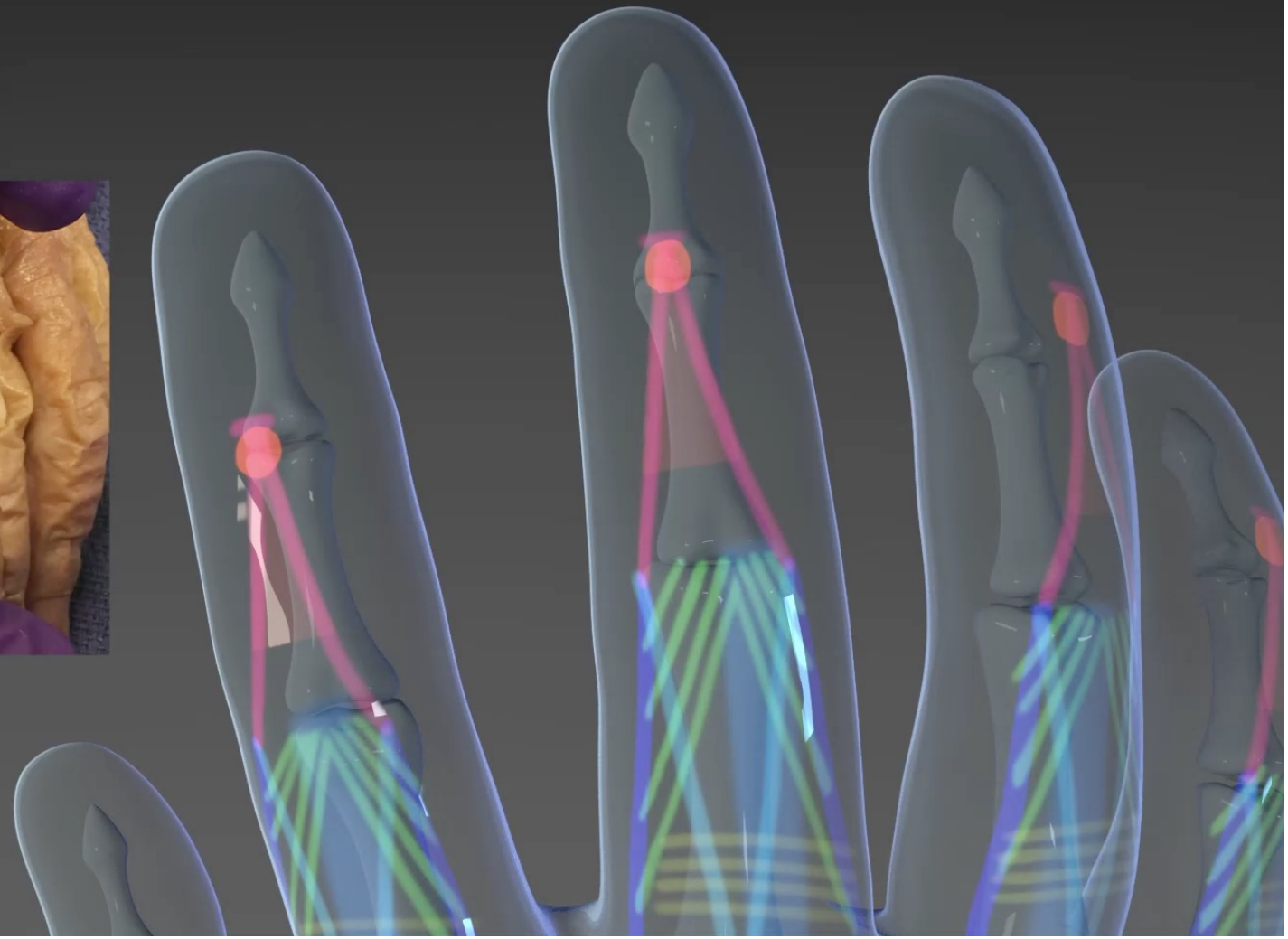

Dorsal Hand



Intrinsic Assessment, Common Diagnoses, Case Management

7th Section

Clinical Competence:
Drawing by Memory

Hand & Upper Extremity
Conference Series LLC

Teton
Hand & Upper Extremity
Conference Series LLC

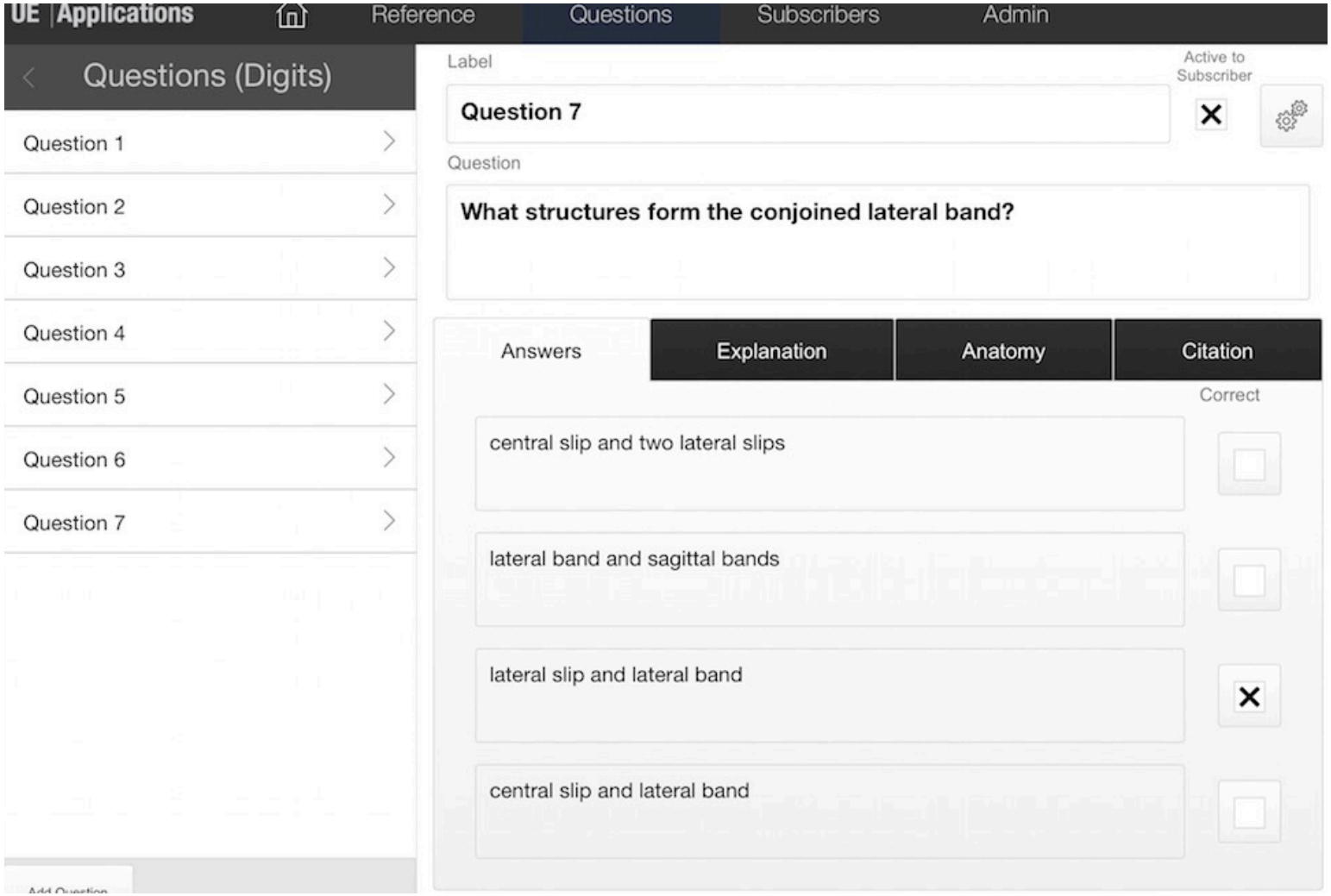

Copyright 2015 University of Florida Research Foundation. All Rights Reserved

Teton
Hand & Upper Extremity
Conference Series LLC

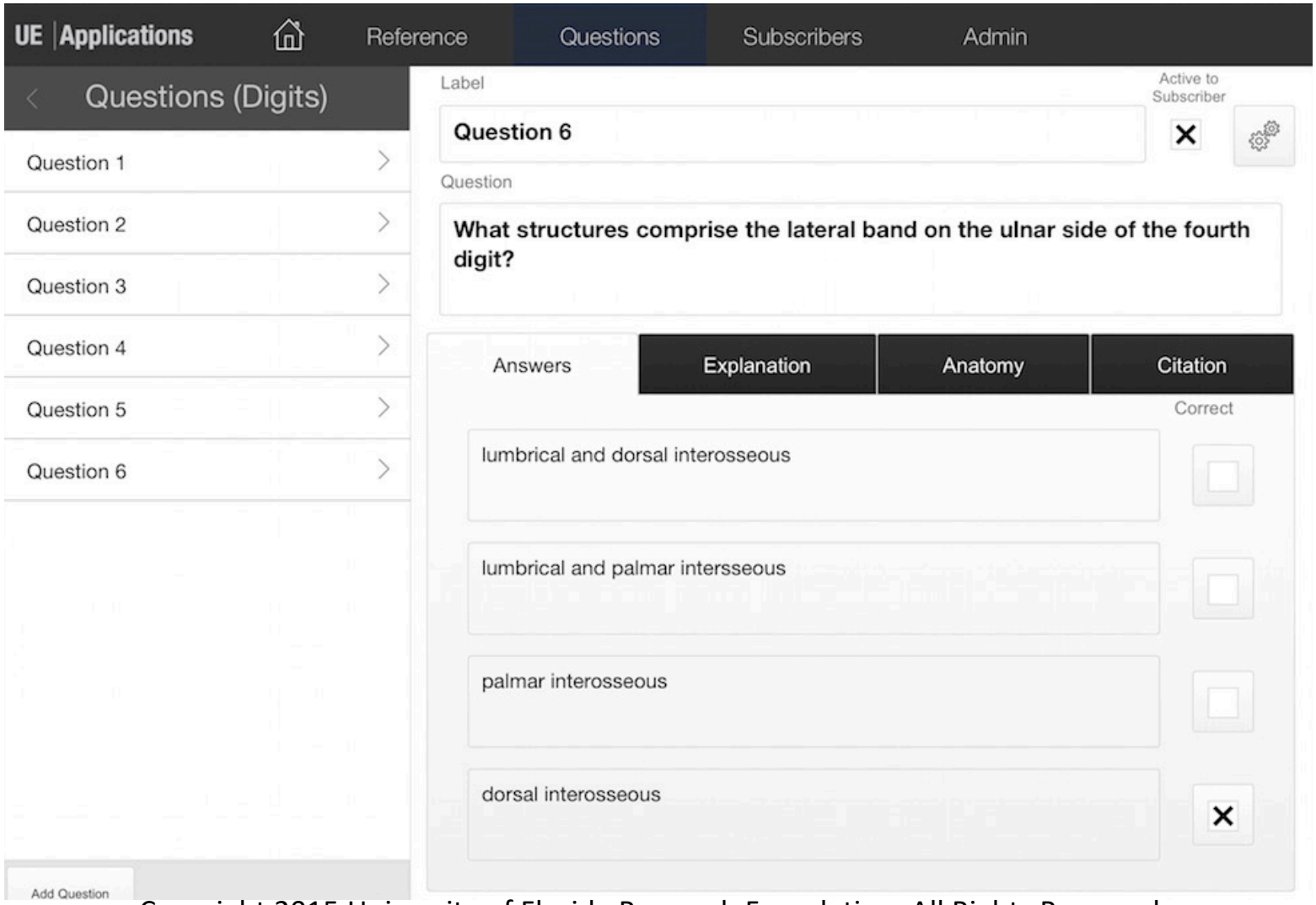

Copyright 2015 University of Florida Research Foundation. All Rights Reserved

Teton
Hand & Upper Extremity
Conference Series LLC

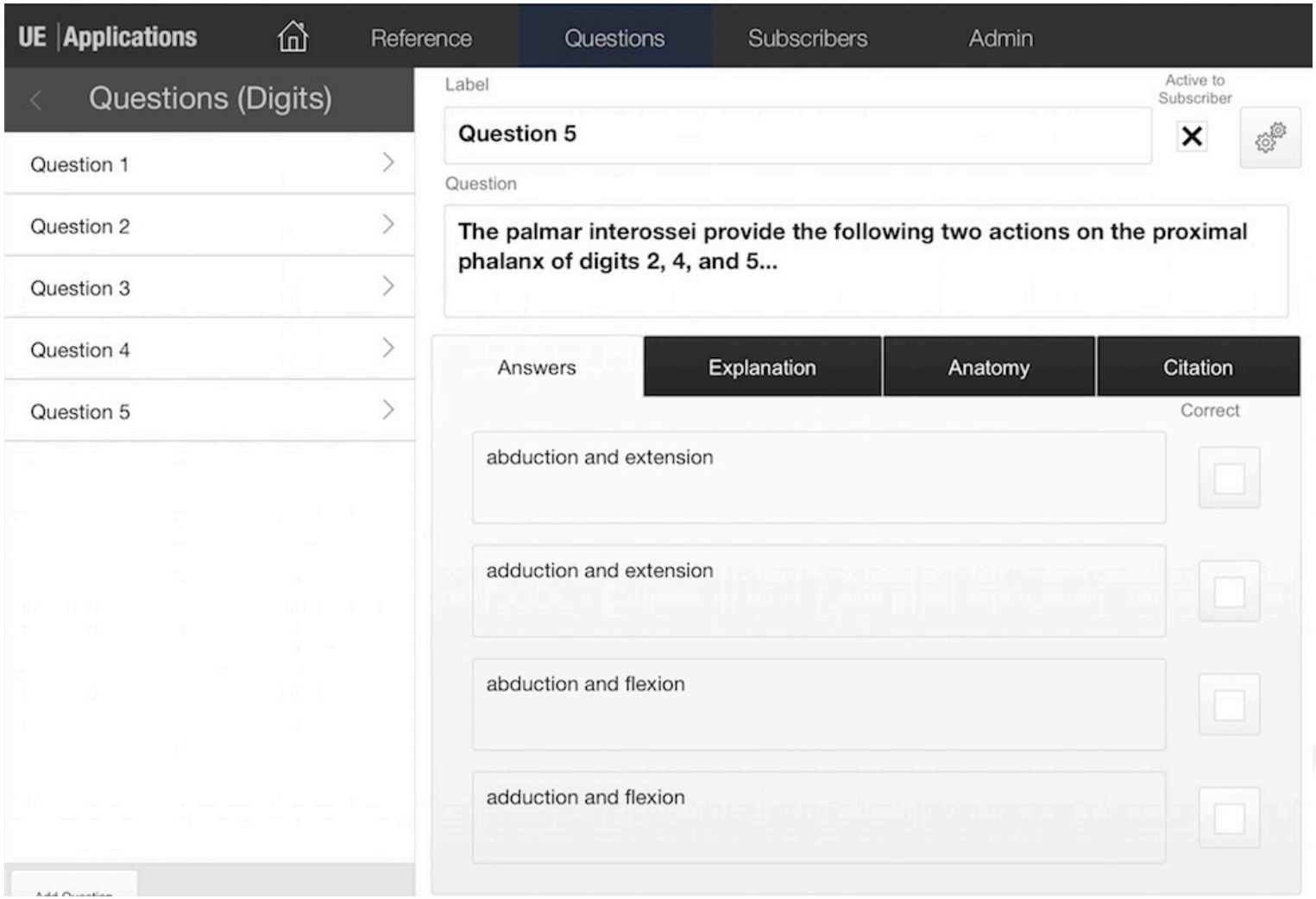

Copyright 2015 University of Florida Research Foundation. All Rights Reserved

Teton
Hand & Upper Extremity
Conference Series LLC

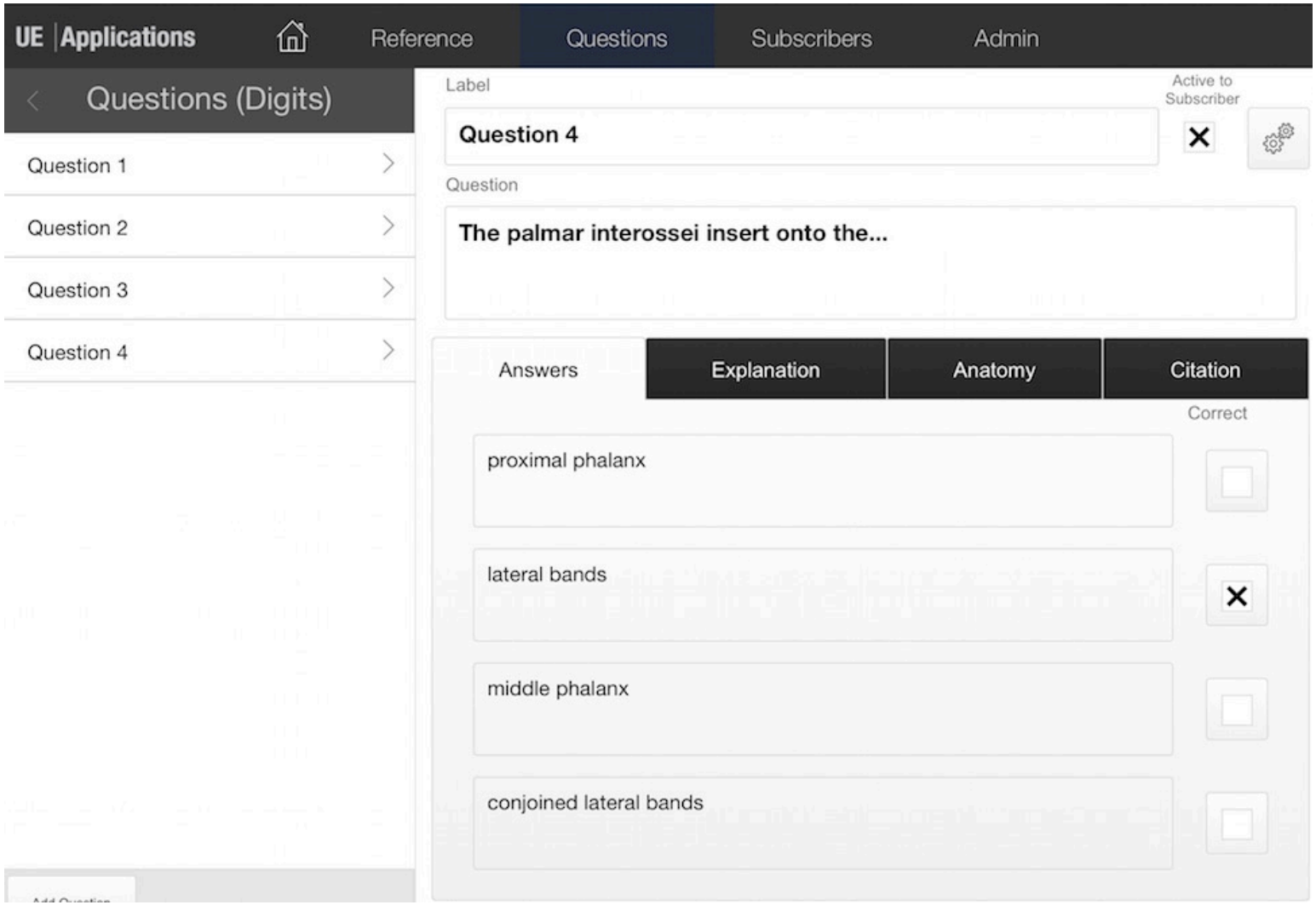

Copyright 2015 University of Florida Research Foundation. All Rights Reserved

Teton
Hand & Upper Extremity
Conference Series LLC

References

- Boyer, M. I. & Gelberman, R. H. (1999). Operative correction of swan-neck and boutonniere deformities in the rheumatoid hand. *Journal of the American Academy of Orthopaedic Surgeons, 7* (2), 92-100.
- Brand, Paul W. Biomechanics of Balance in the Hand. J Hand Therapy. 247-251, 1993.
- Brand, Paul W. Lessons from Hot Feet: A Note on Tissue Remodeling. J Hand Therapy. 133-135, 2002.
- Brand, Paul W. Mechanical Factors in Joint Stiffness and Tissue Growth. J Hand Therapy. 91-96, 1995.
- Brand, Paul W. Pain-It's All in Your Head: A Philosophical Essay. J Hand Therapy. 10:59-63, 1997.
- Brand, Paul W. The Mind and Spirit in Hand Therapy. J Hand Therapy. 145-147, 1988.
- Dell, P. C. & Sforzo, C. R. (2005). Ulnar intrinsic anatomy and dysfunction. *Journal of Hand Therapy, 18*, 198-207.
- Elson, R. A. (1986). Rupture of the central slip of the extensor hood of the finger. A test for early diagnosis. *Journal of Bone & Joint Surgery, British Volume*, *68*(2), 229-231.
- Glasgow C, Tooth LR, Fleming J. Mobilizing the Stiff Hand: Combining Theory and Evidence to Improve Clinical Outcomes. J Hand Therapy. 23:392-401, 2010.

Teton
Hand & Upper Extremity
Conference Series LLC

References

- Gruber, J. S., Bot, A. G. J., & Ring, D. (2014). A prospective randomized controlled trial comparing night splinting with no splinting after treatment of mallet finger. *Hand, 9*, 145-150.
- Hollister A, Giurintano DJ. Thumb Movements, Motions, and Moments. J Hand Therapy. 8:106-114, 1995.
- Leversedge, F. J., Goldfarb, C. A., Boyer, M. I. (2010). A pocketbook manual of hand and upper extremity anatomy. Philidephia, PN: Williams & Wilkins.
- Leversedge, Fraser J. Anatomy and Pathomechanics of the Thumb. Hand Clinics. 24:219-229, 2008.
- Mackin, Callahand, Skerven, Schneider, Osterman (2002). *Rehabilitation of the hand and upper extremity.* Saint Louis, Missouri: Mosby.
- Moore, K. L. (1992). Clinically oriented anatomy. Baltimore, Maryland: Williams & Wilkins.
- Smith, R. J. (1975). Intrinsic muscles of the fingers: Function, dysfunction, and surgical reconstruction. *AAOS: Instructional Course Lecture*, *24*, 200-220.
- Smith, Richard J. Balance and Kinetics of the Fingers Under Normal and Pathological Conditions. Clinical Orthopaedics and Related Research. 104:92-111, 1974.
- Smith, Richard J. Intrinsic Muscles of the Fingers: Function, Dysfunction, and Surgical Reconstruction. A.A.O.S: Instructional Course Lectures. 12:200-219.

Teton
Hand & Upper Extremity
Conference Series LLC