

Animated Intrinsic of the Hand

(Master Edition)

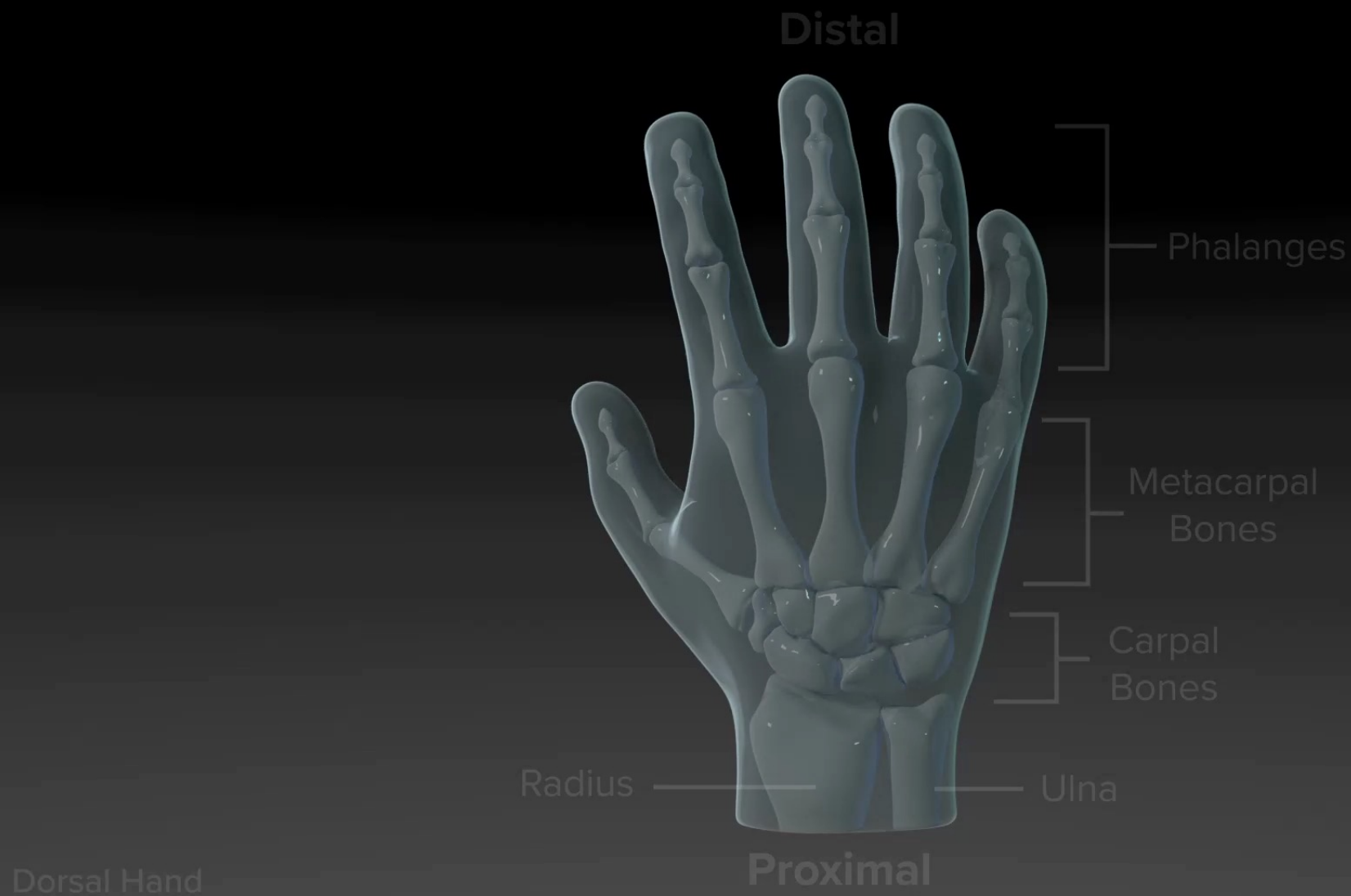
Presented by:

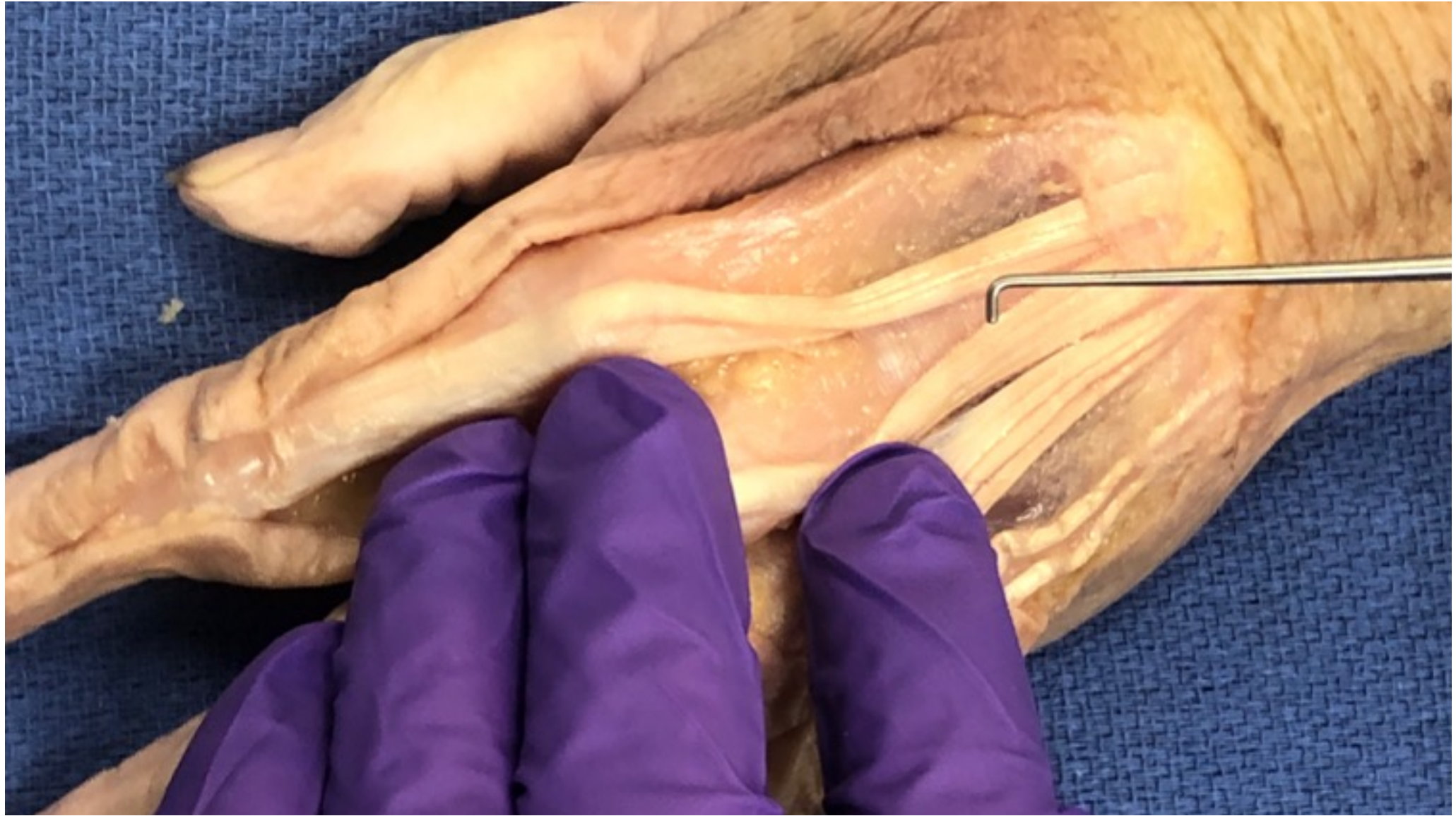Mike Cricchio, MBA, OT/L, CHT

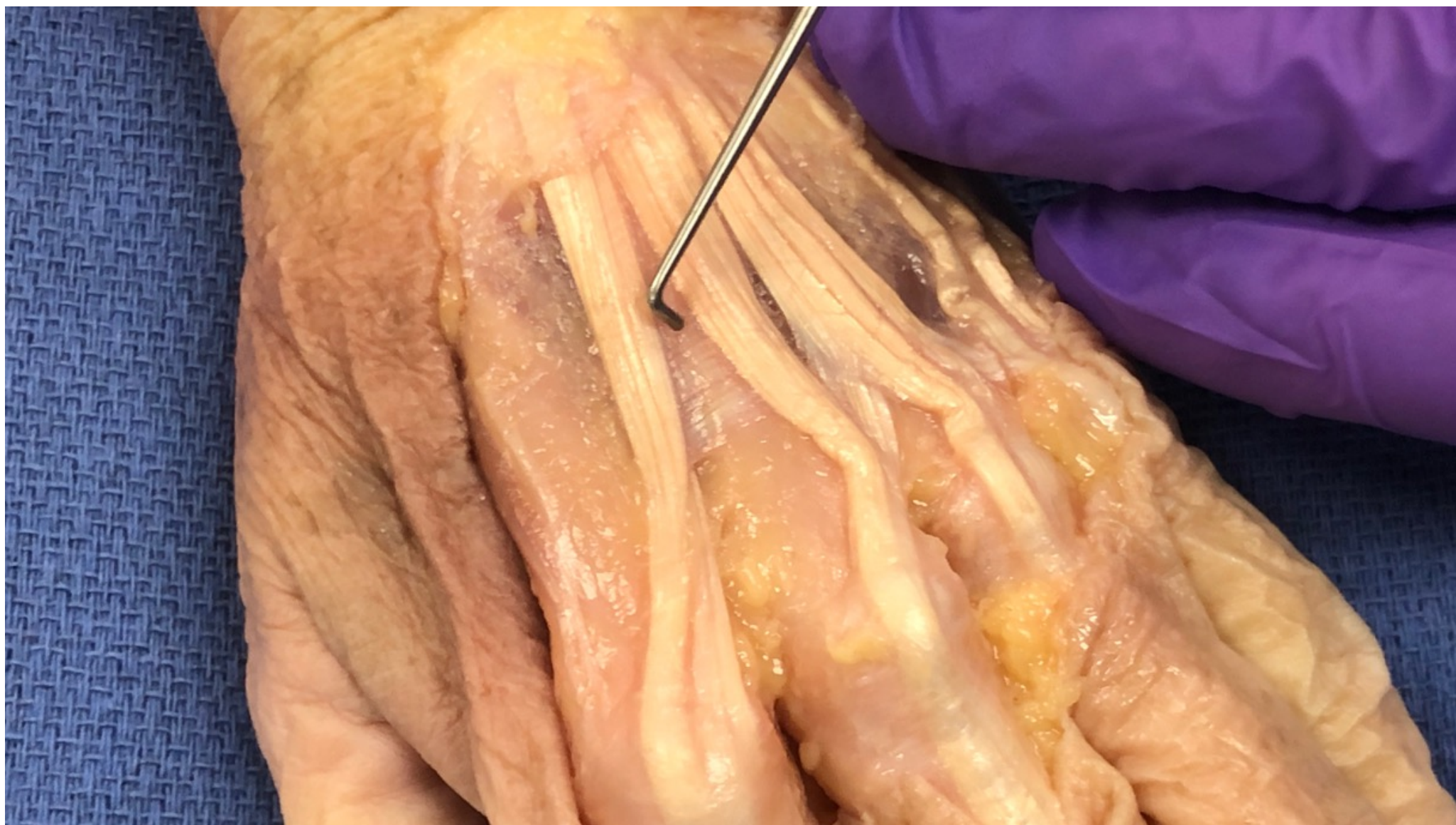Hand & Upper Extremity
Conference Series LLC

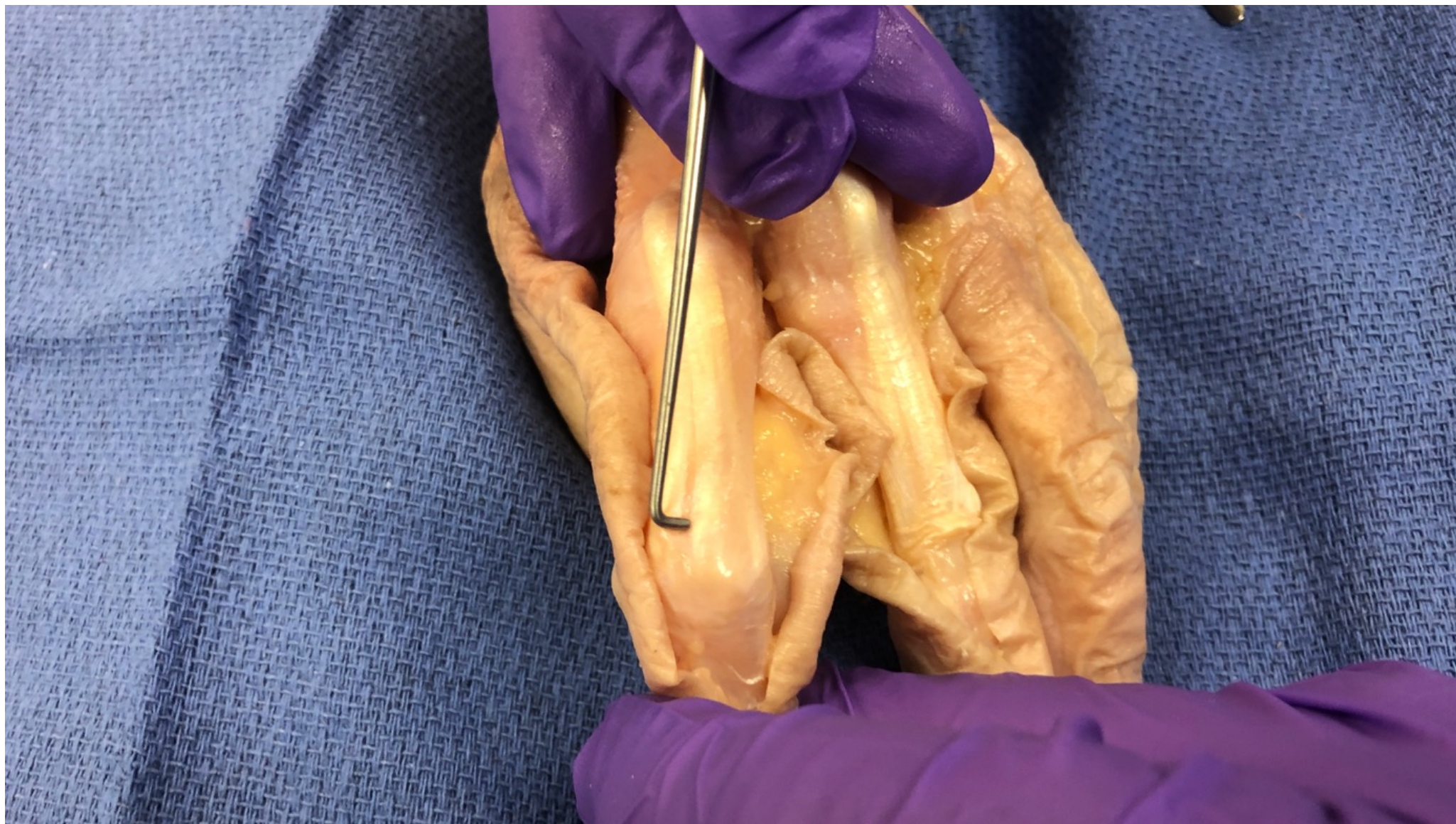


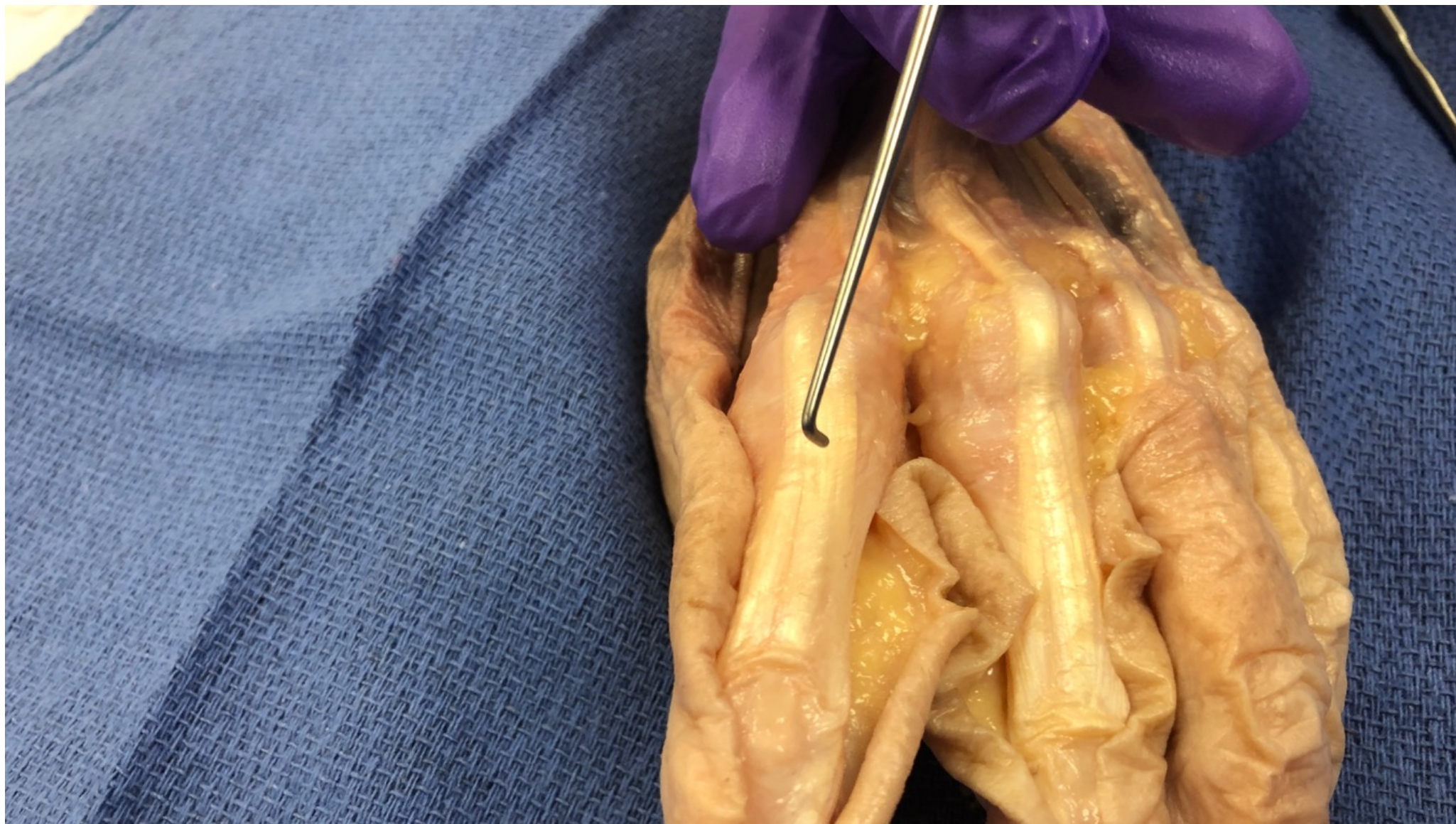
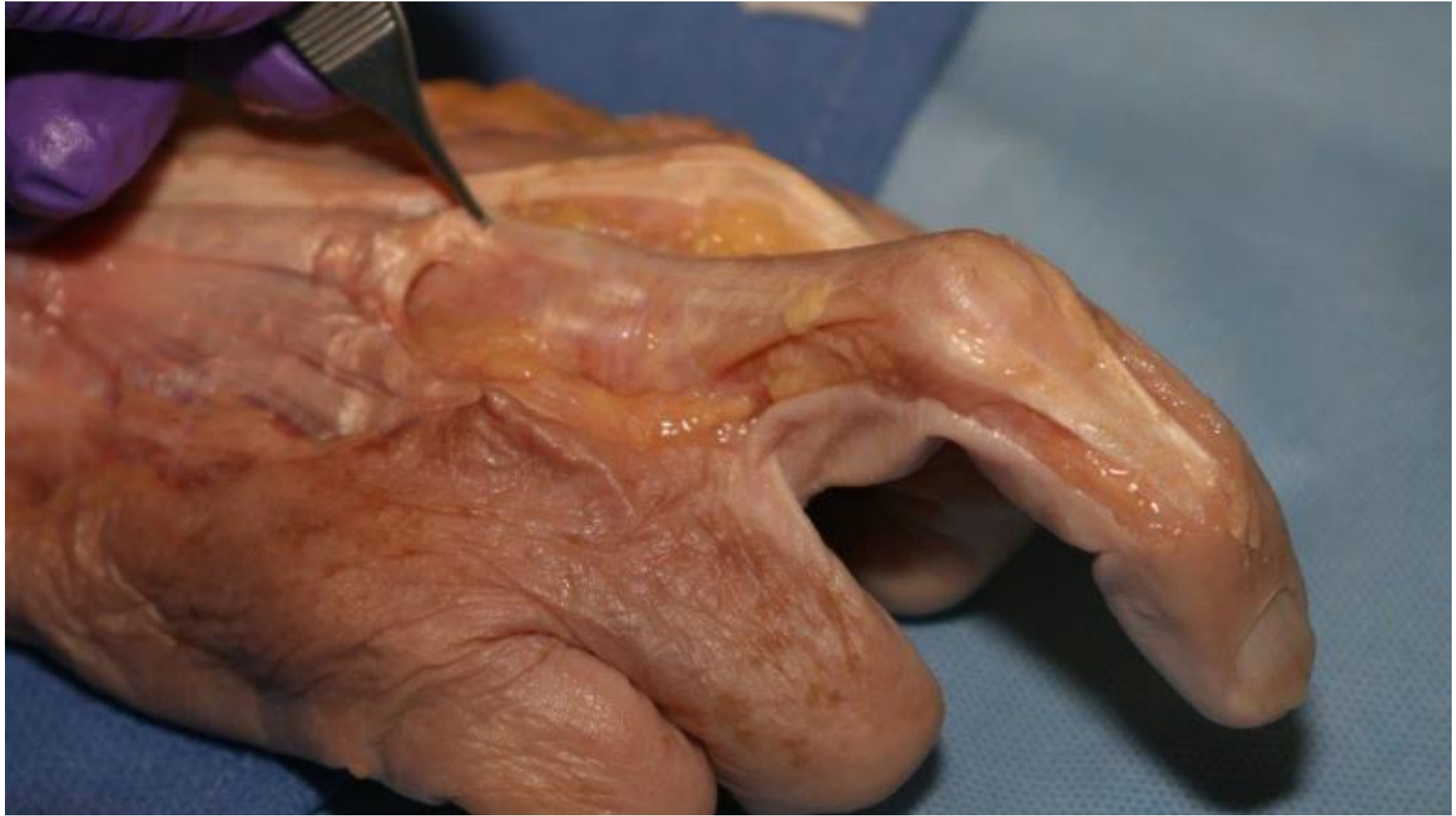




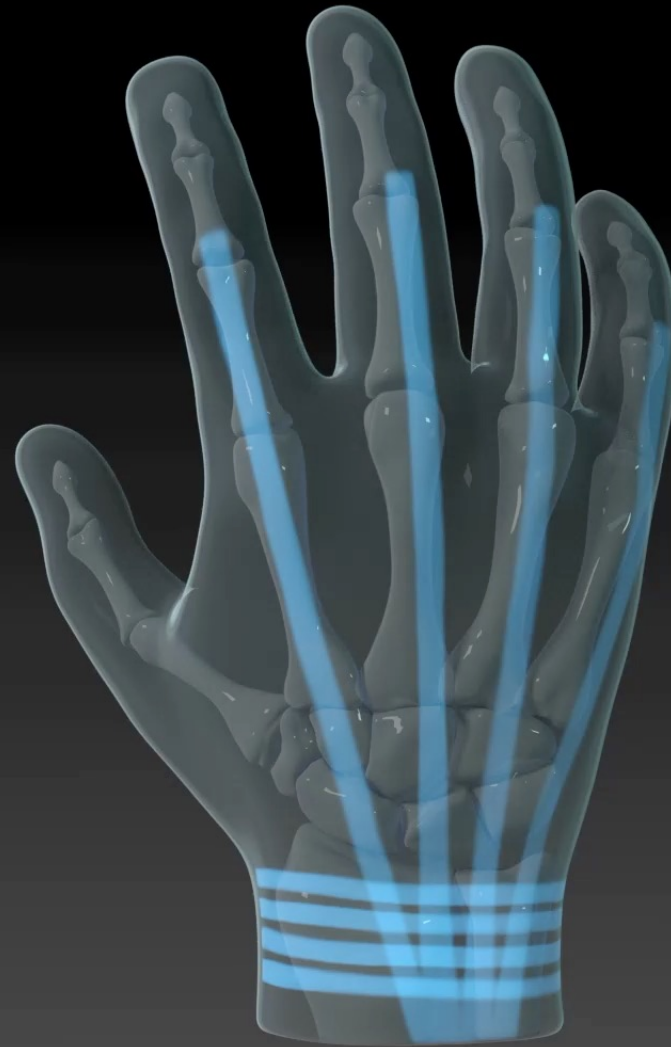








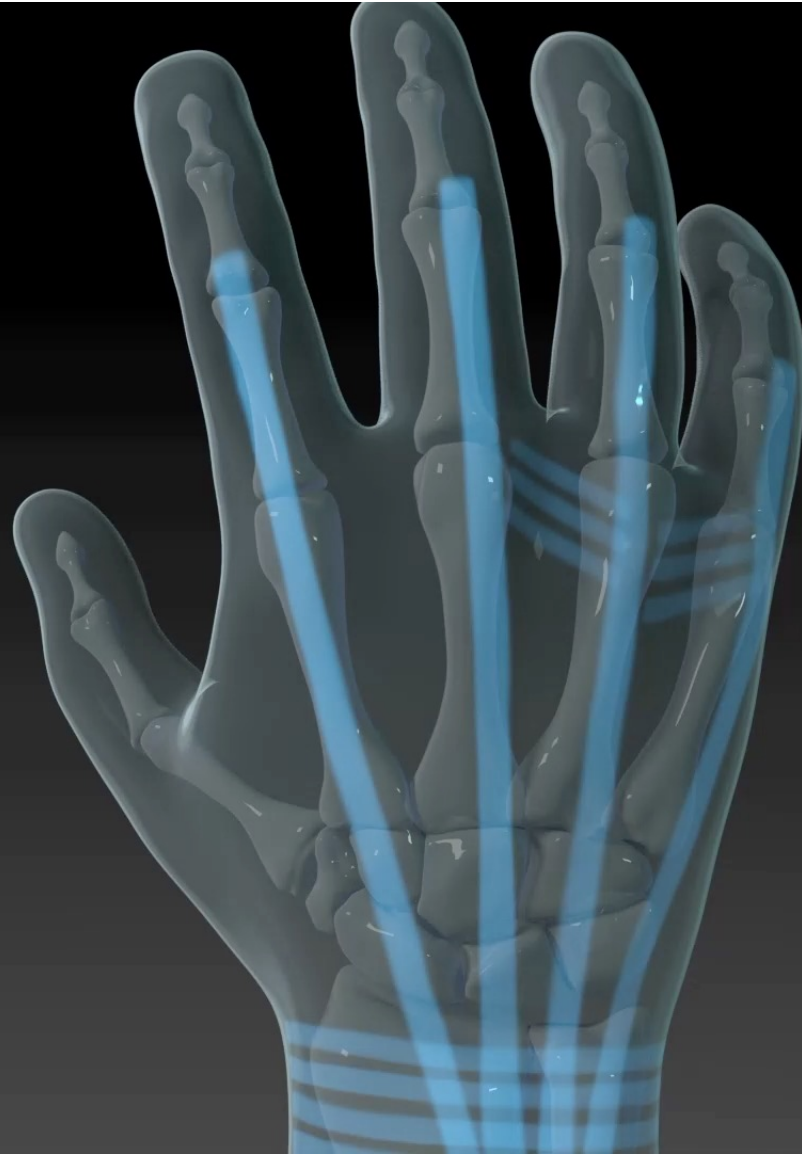Extensor Retinaculum

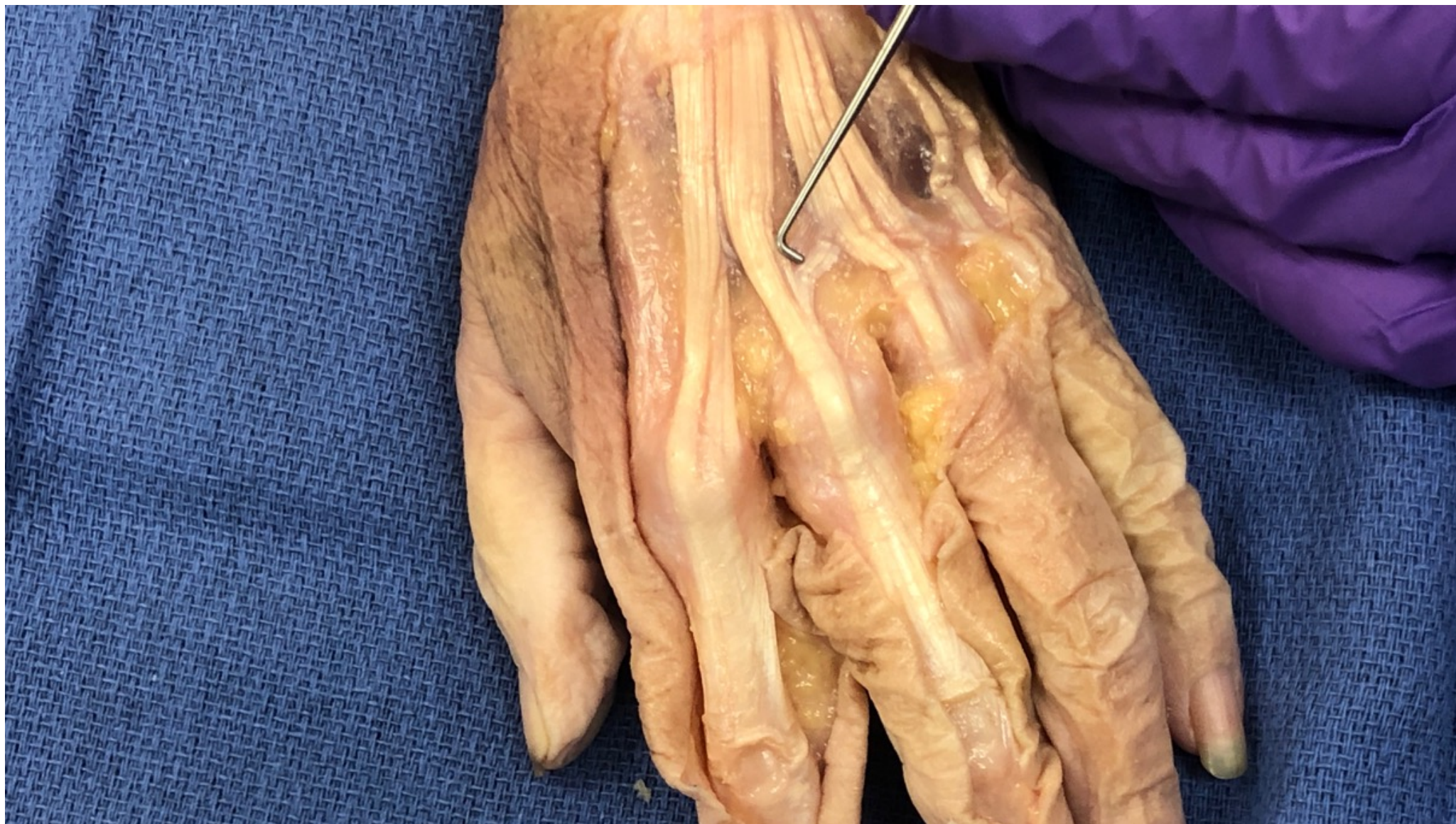

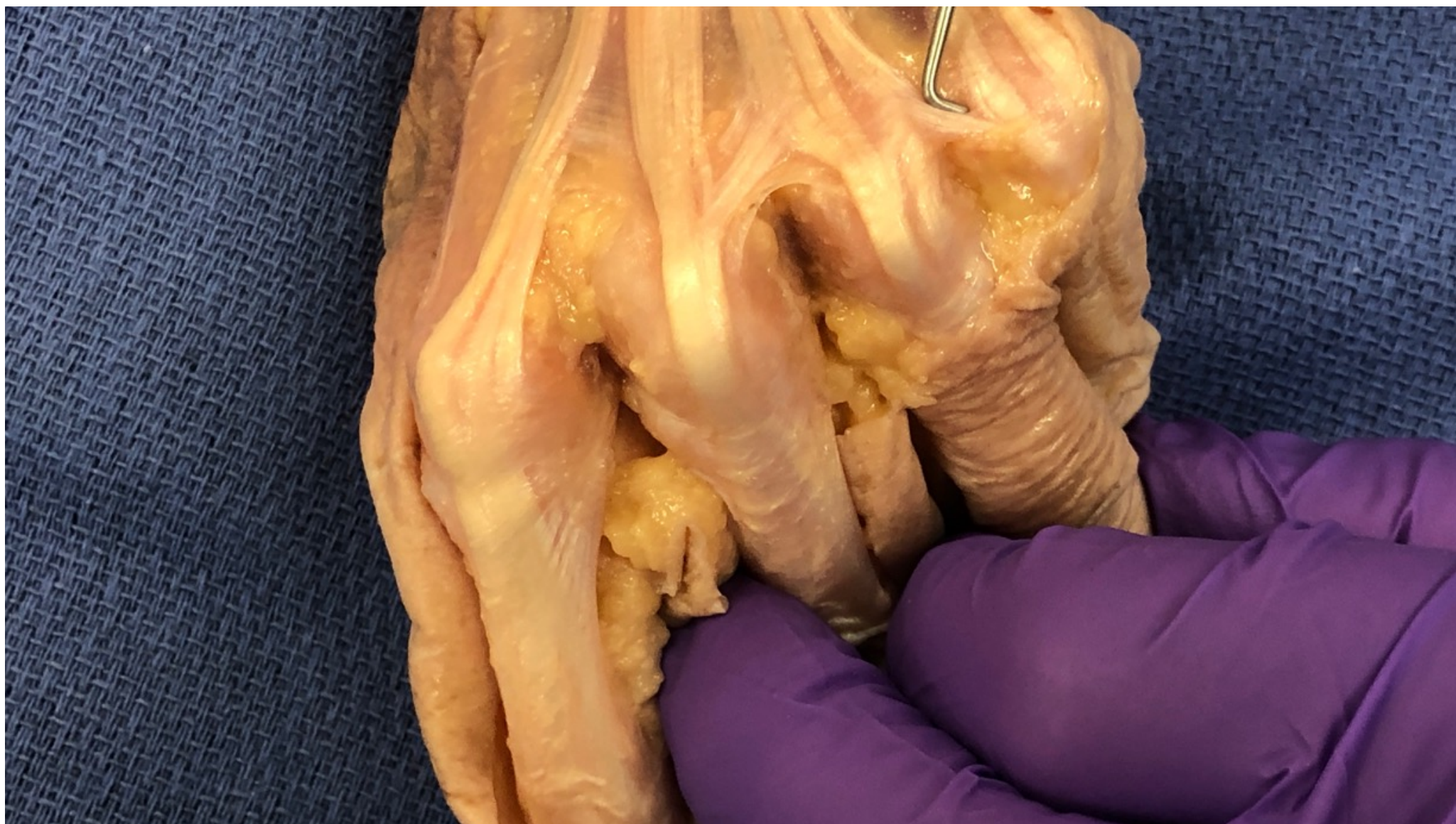Dorsal Hand

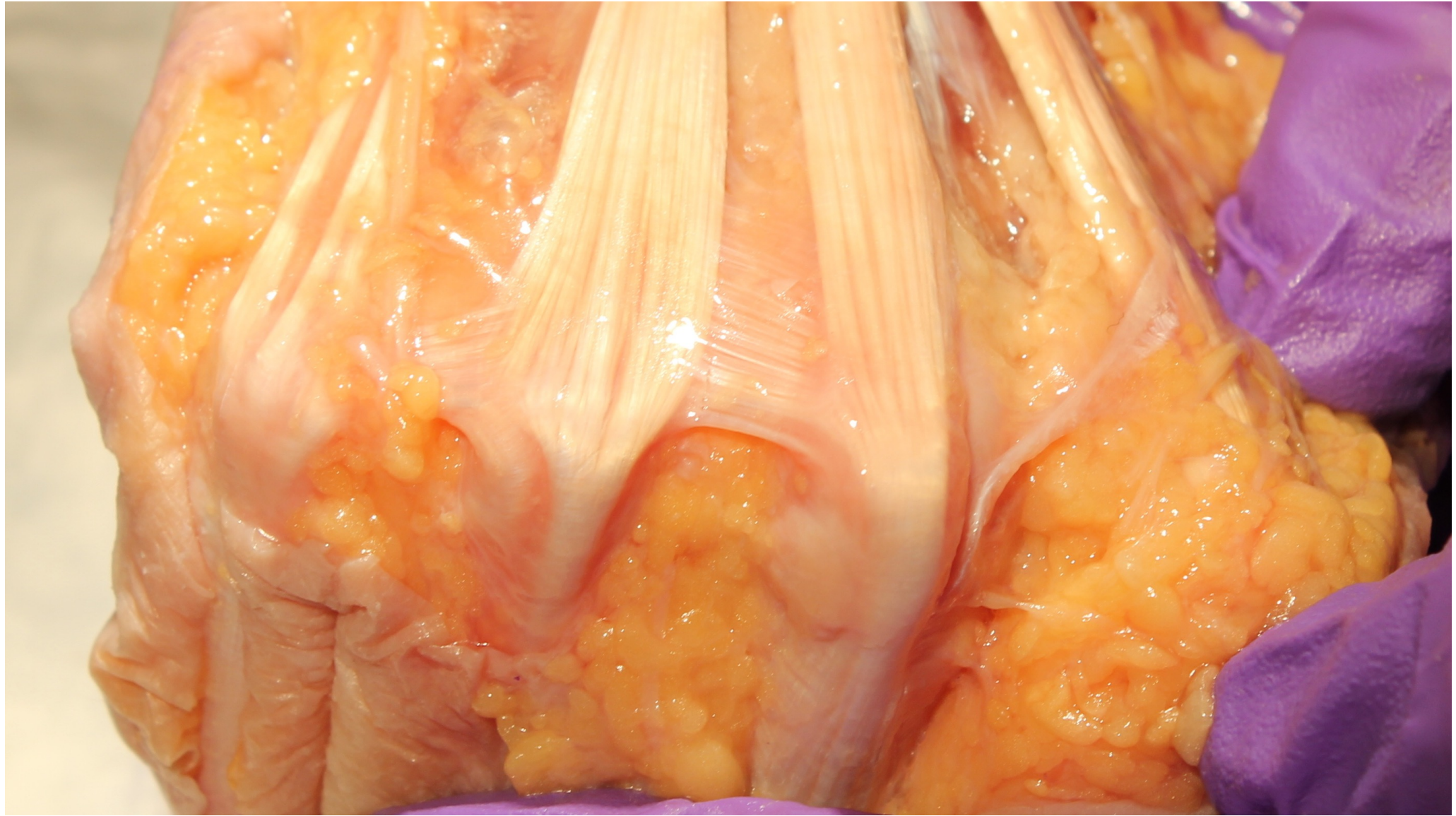Juncturae Tendium

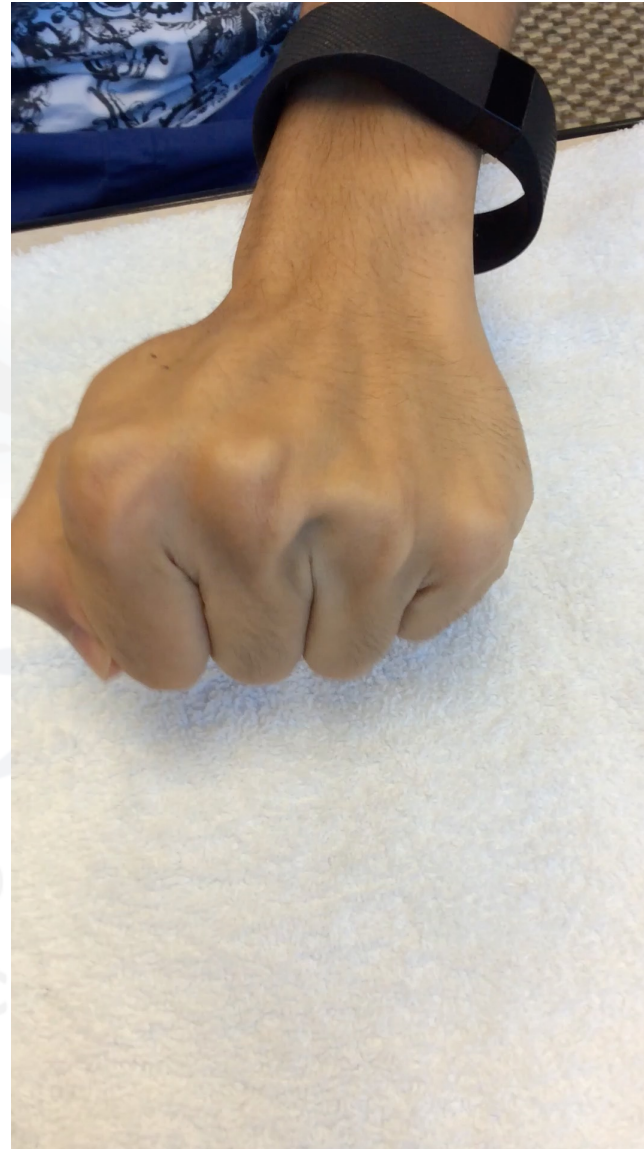
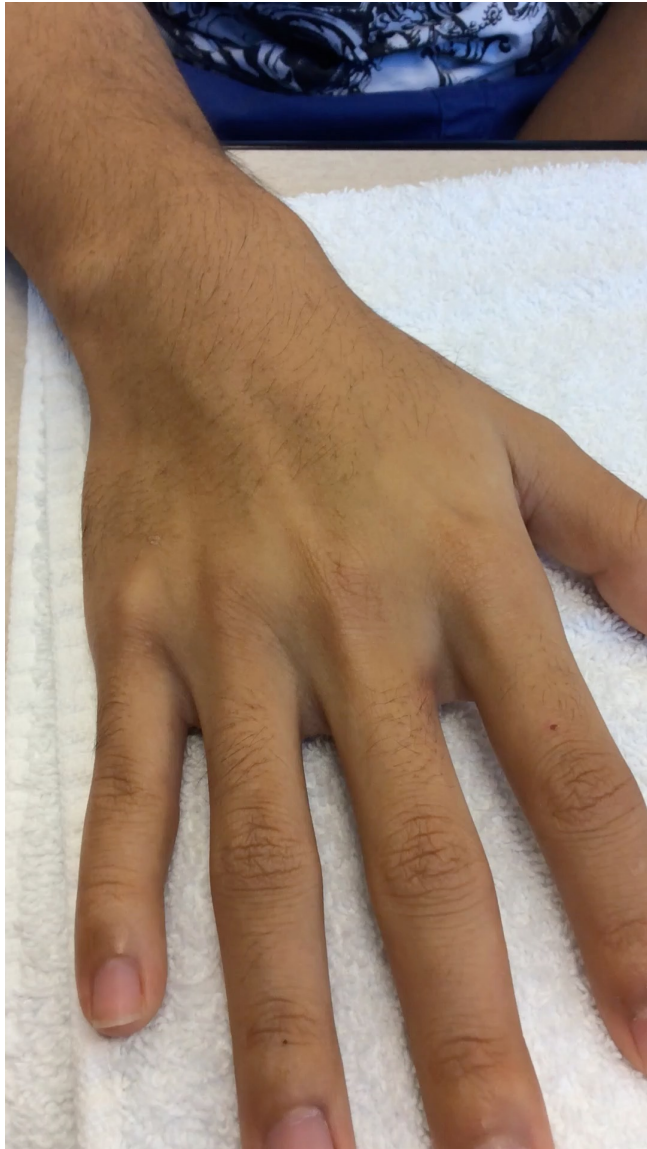
Dorsal Hand



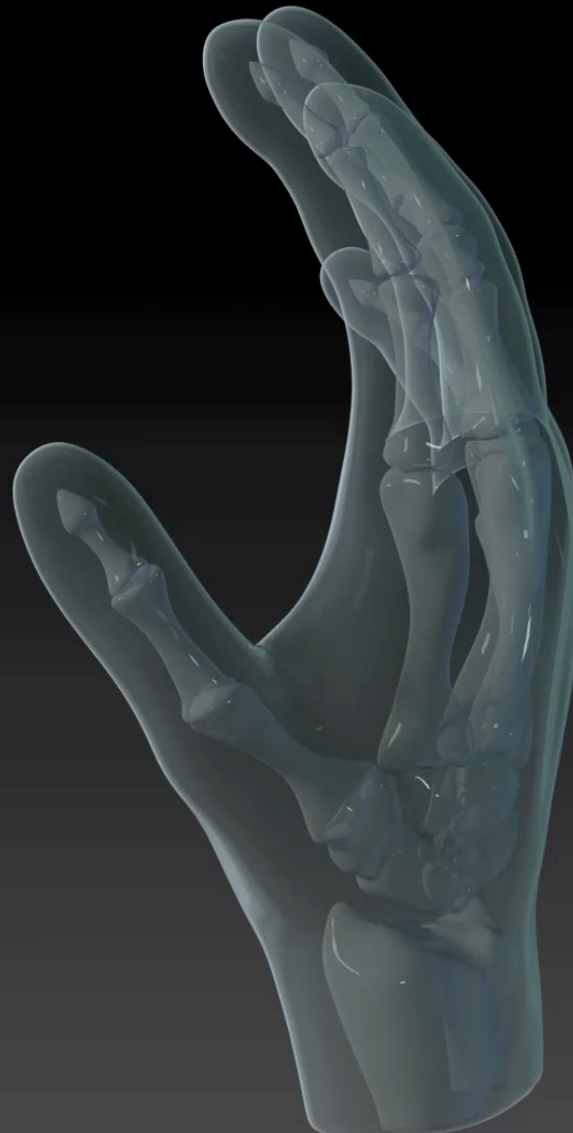




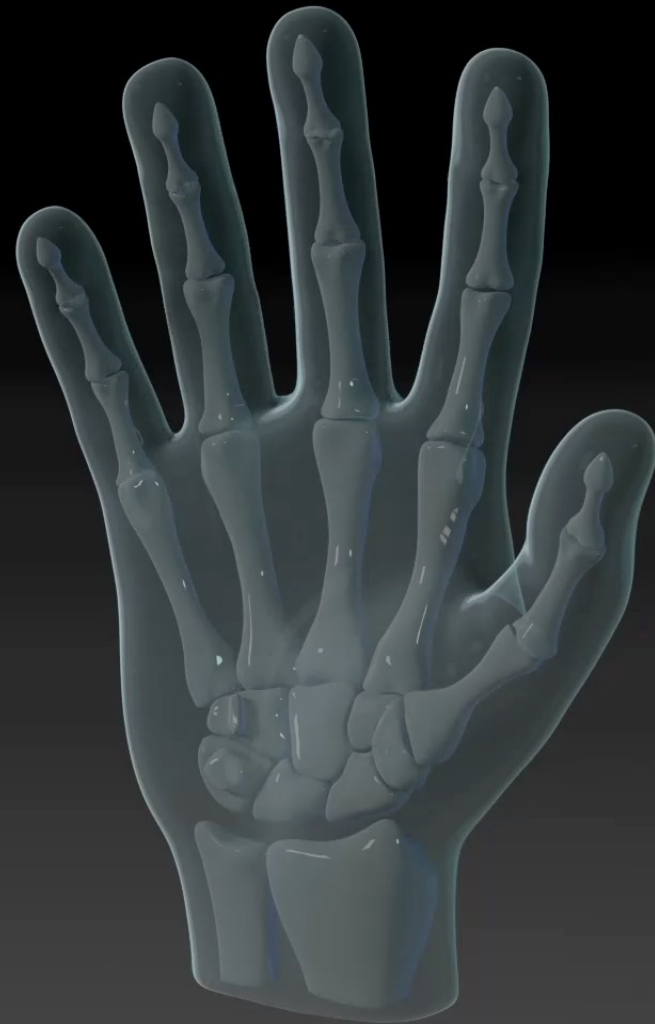

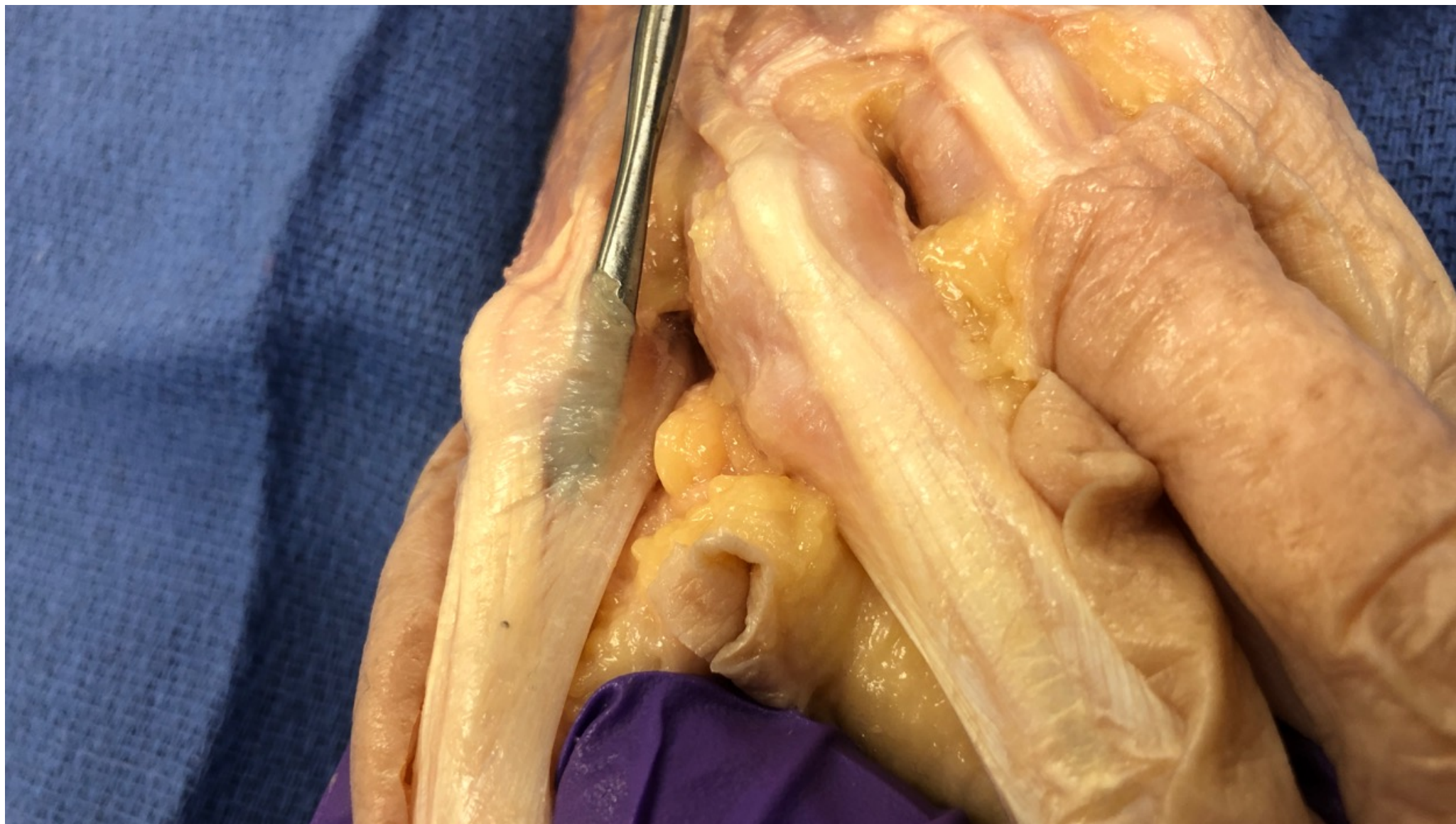
Teton
& Upper
Extremity
Conference Series LLC

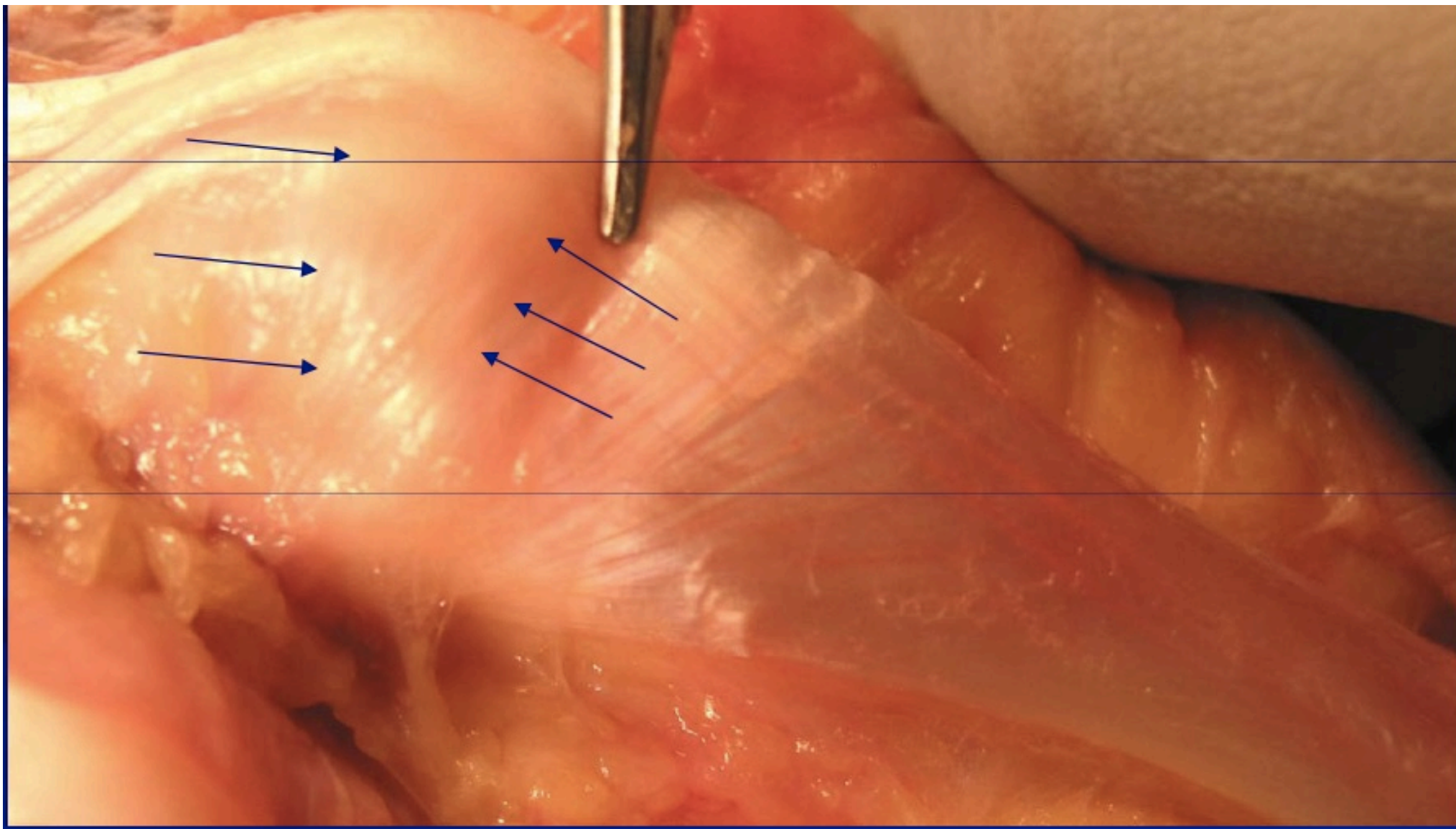
Volar Plates of Metacarpal Phalangeal Joint

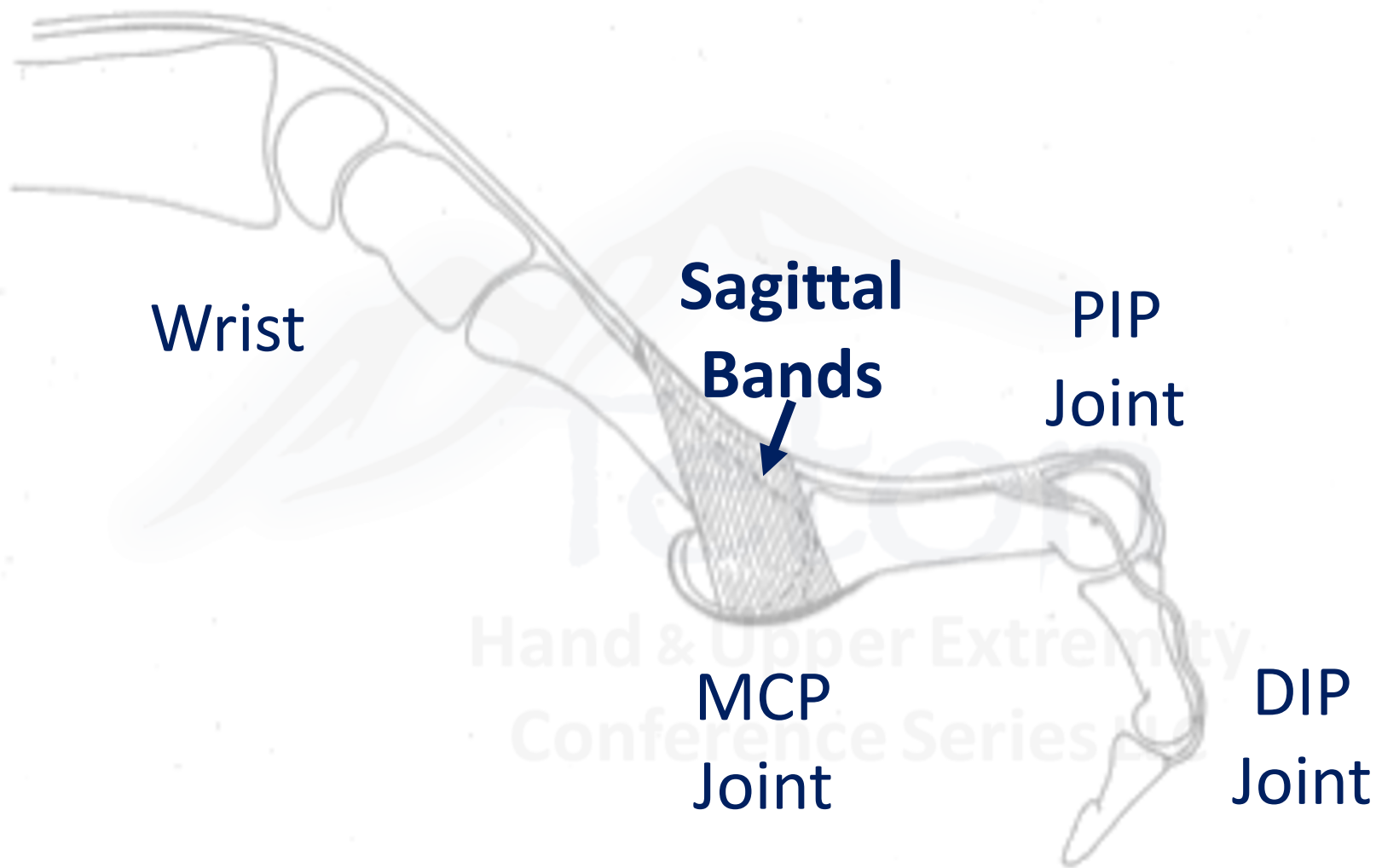


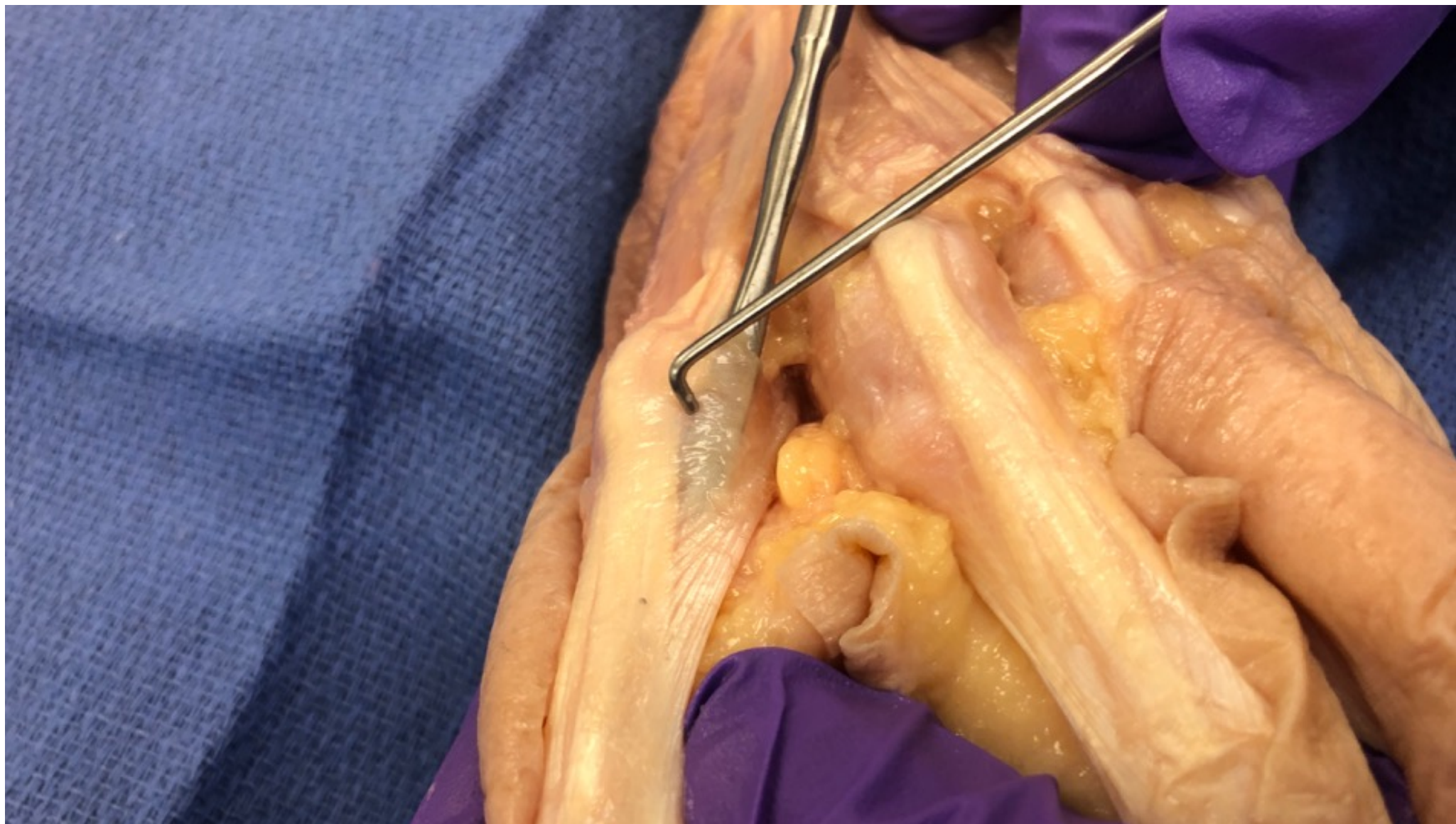
Palmar Hand

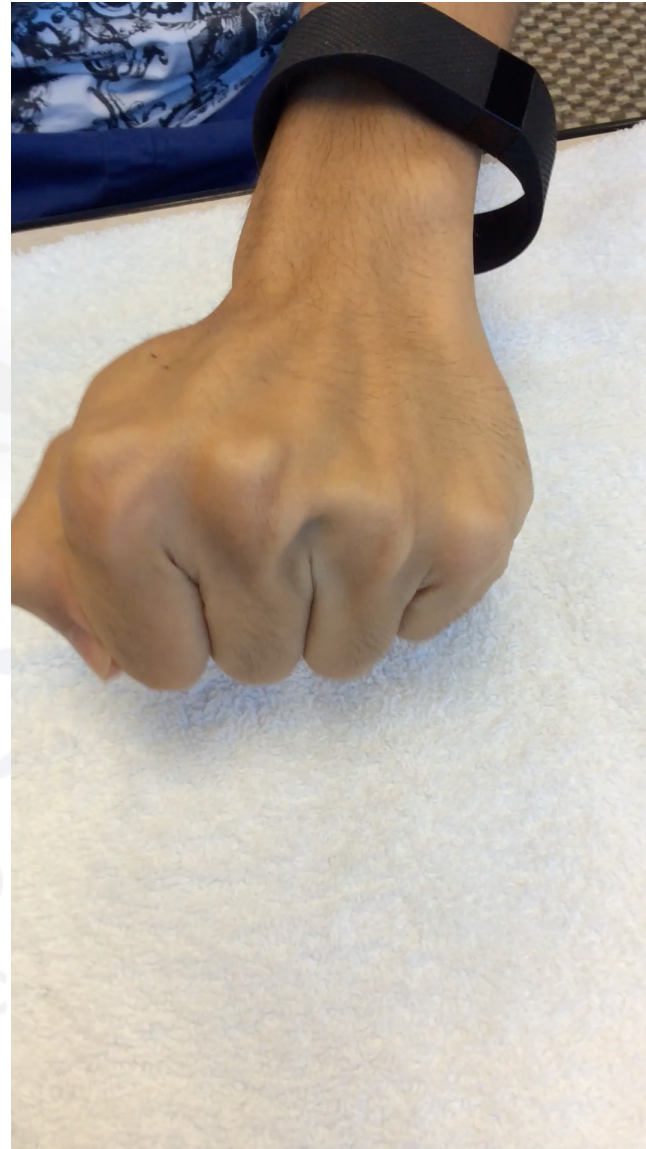



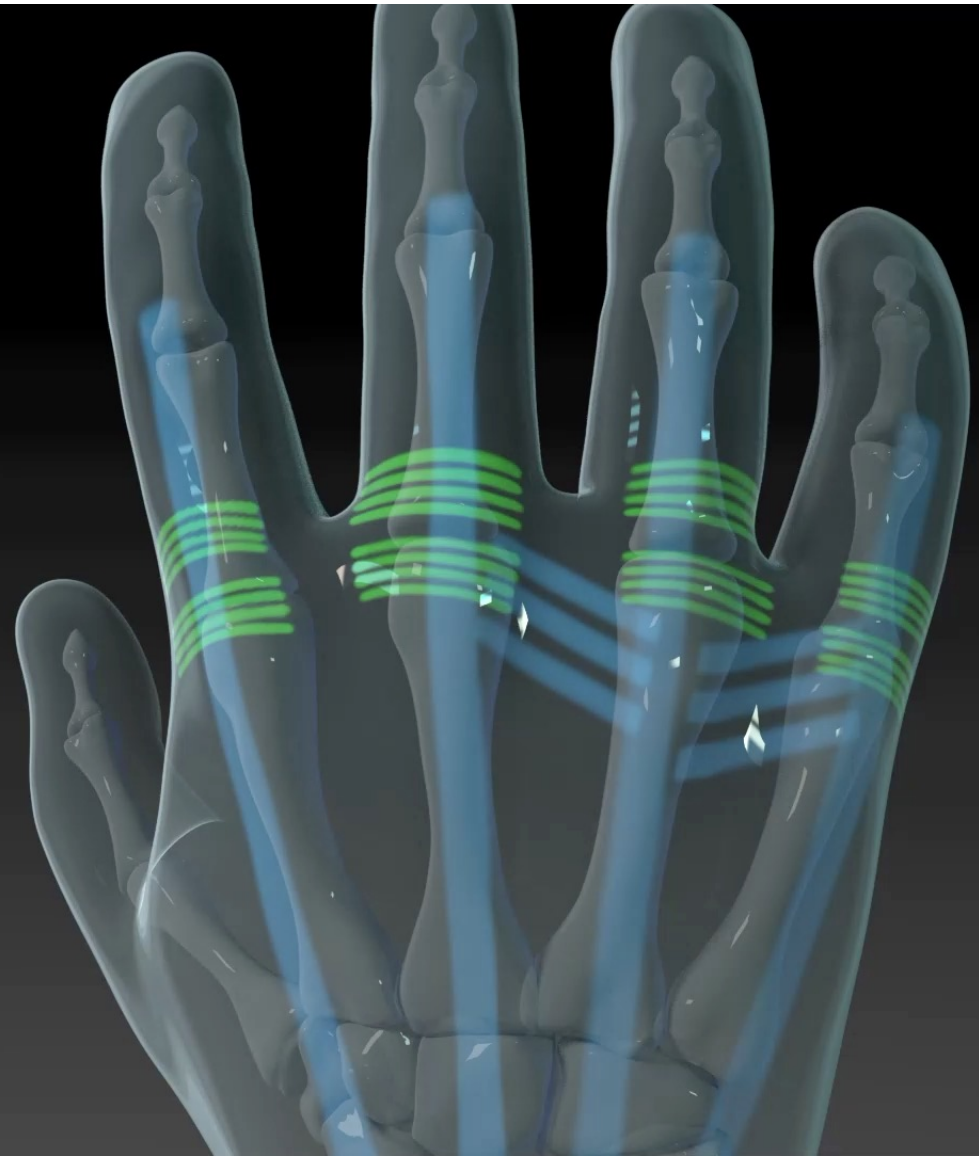






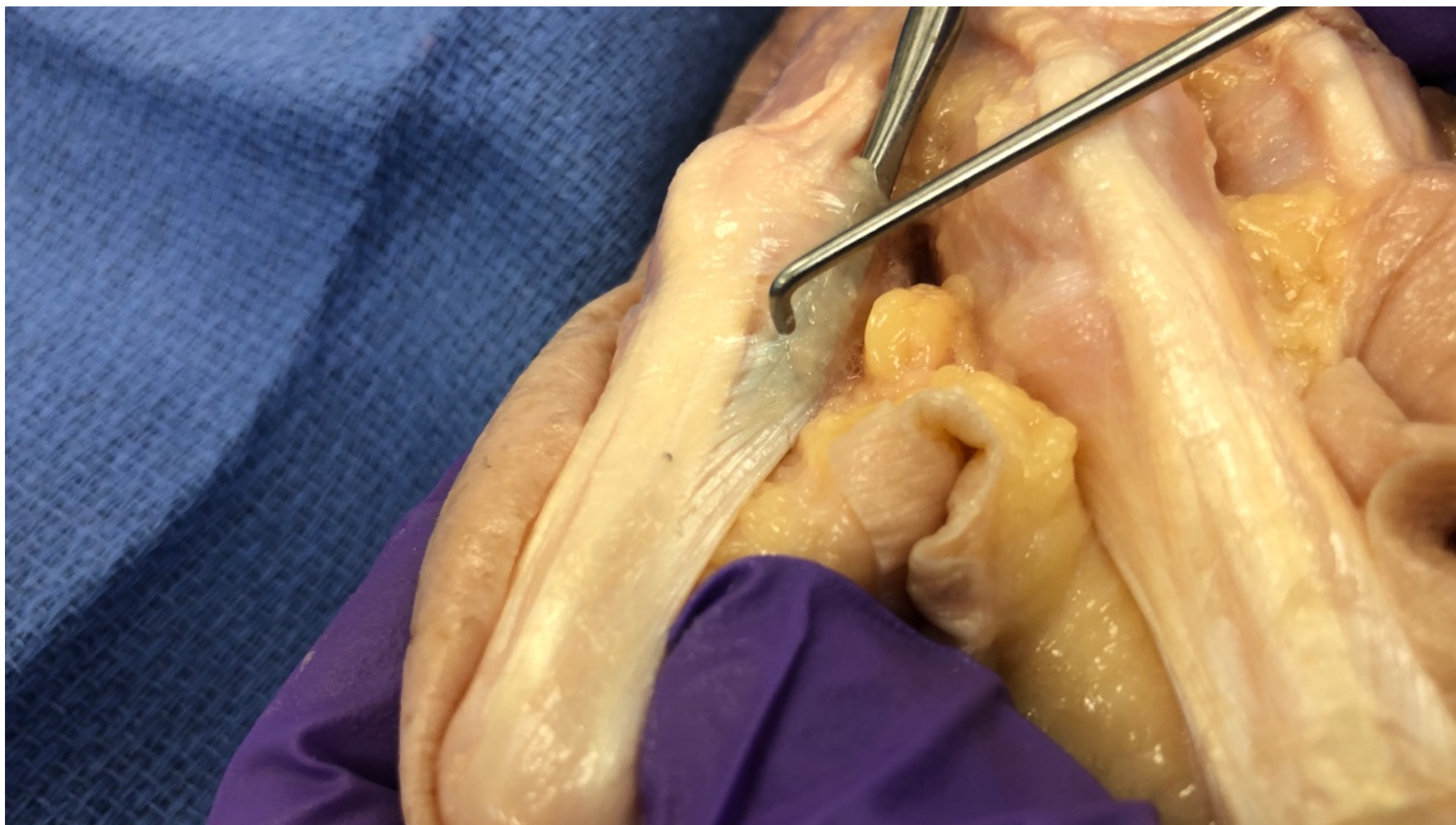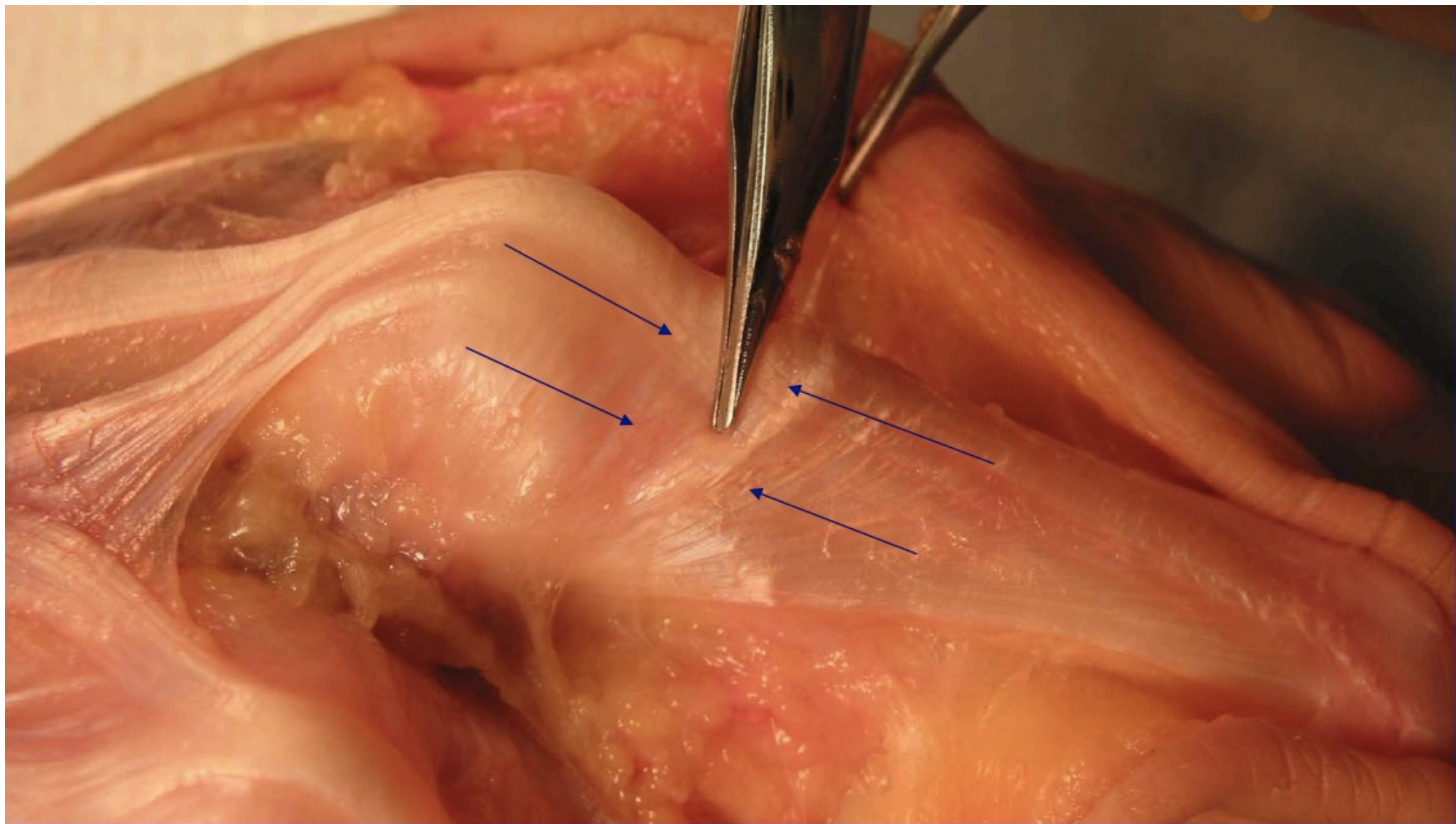


Transverse Fibers



Dorsal Hand





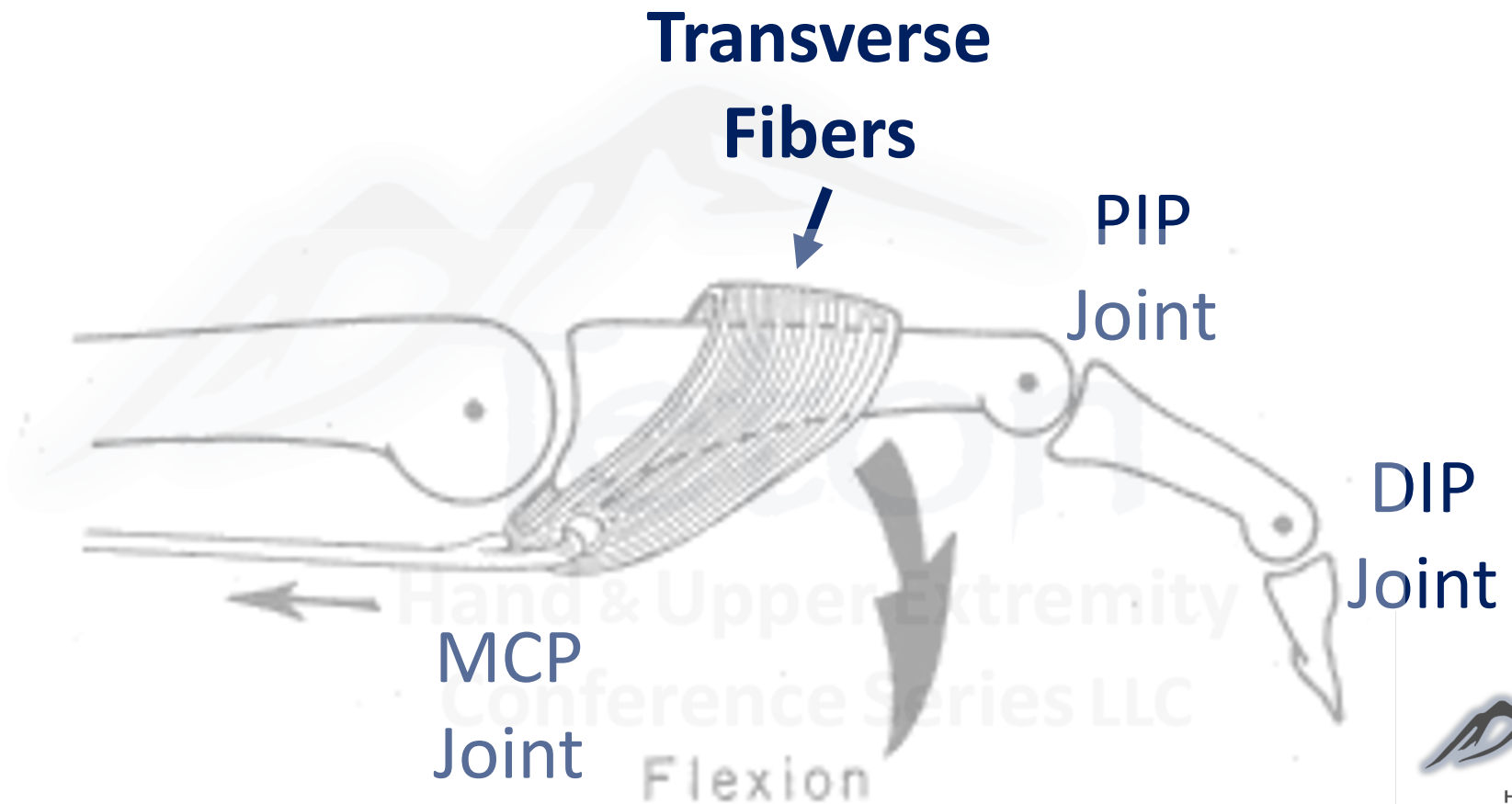
**Transverse
Fibers**

**PIP
Joint**

**DIP
Joint**

**MCP
Joint**

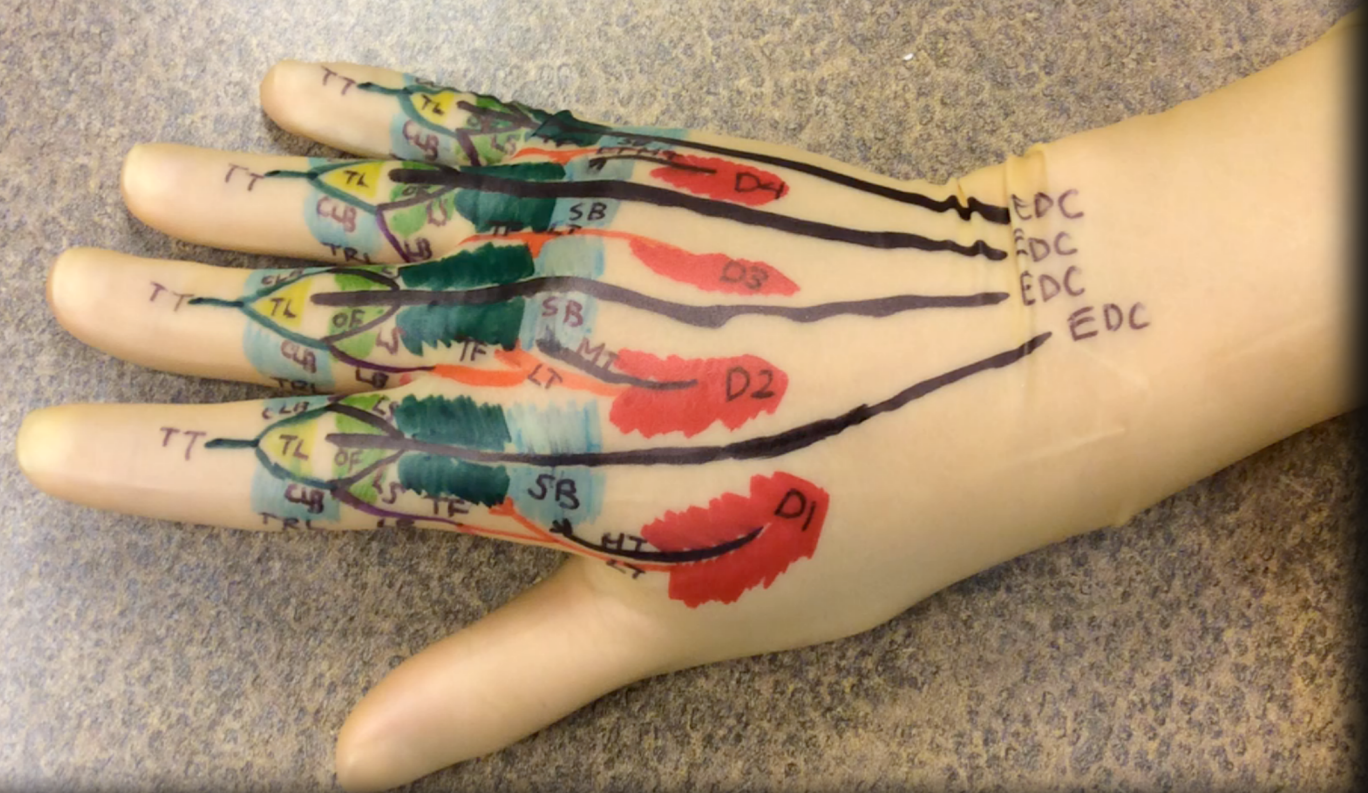Flexion



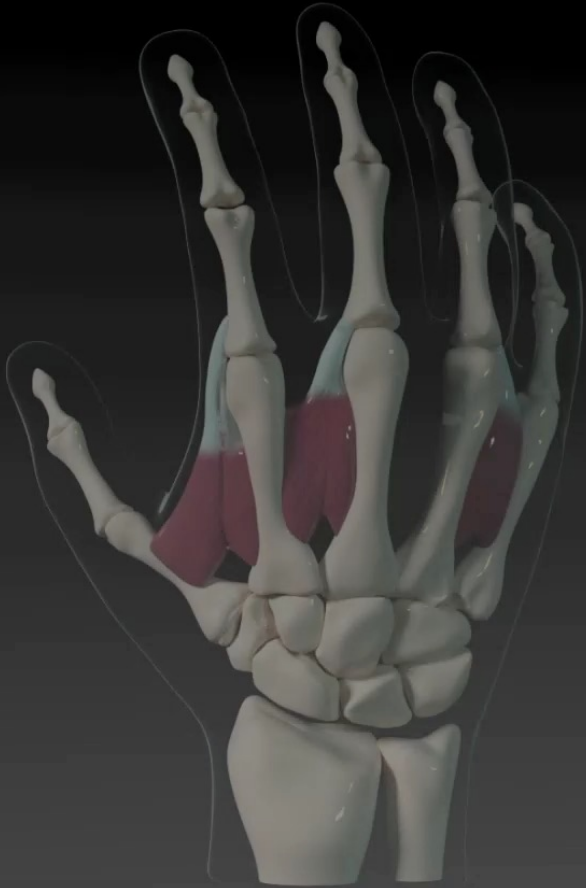


Superficial muscle bellies
of DI

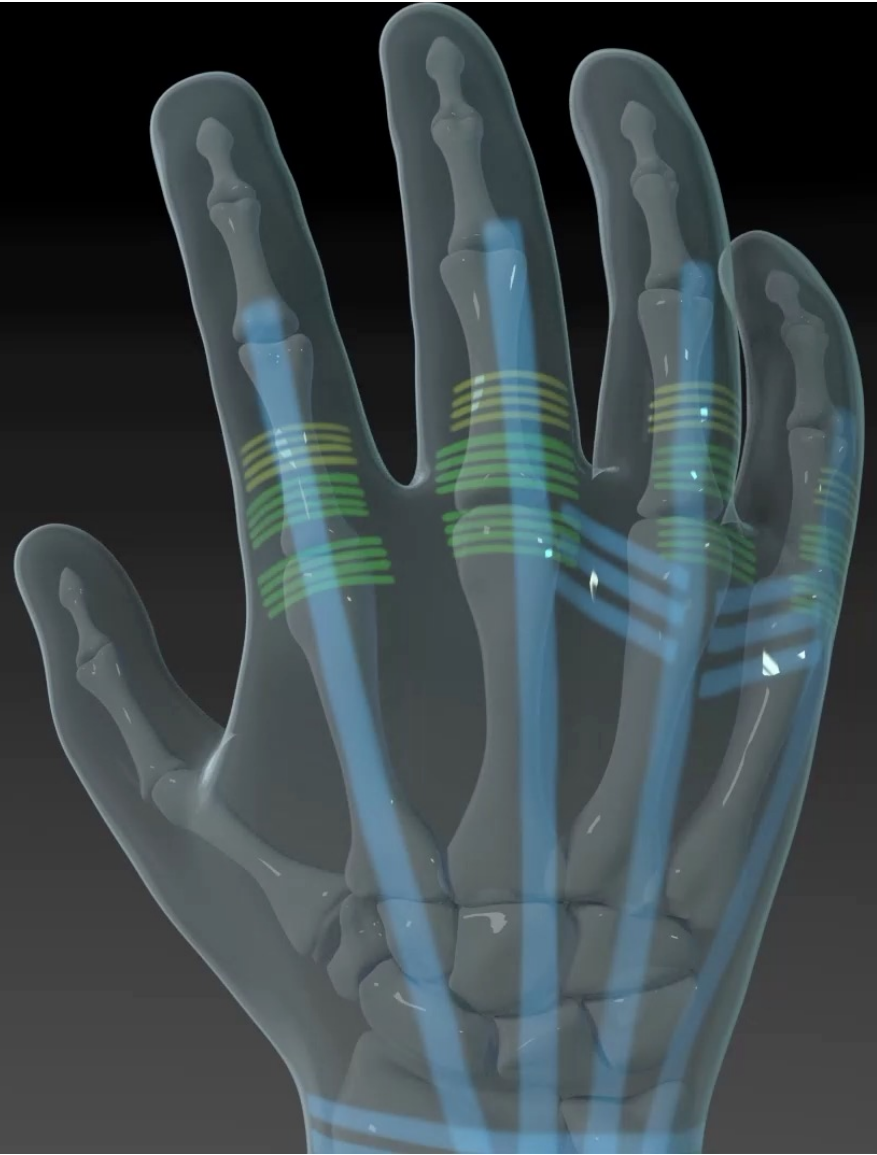
This is a photograph of a pig's back, specifically the area between the ribs, which has been surgically opened to reveal the underlying muscles. The muscles are arranged in a series of parallel, fan-shaped segments. A blue arrow points from the text label to the first of these muscle segments. A blue surgical drape is visible on the right side of the image, partially covering the dissection. The background is a blue surgical cloth.

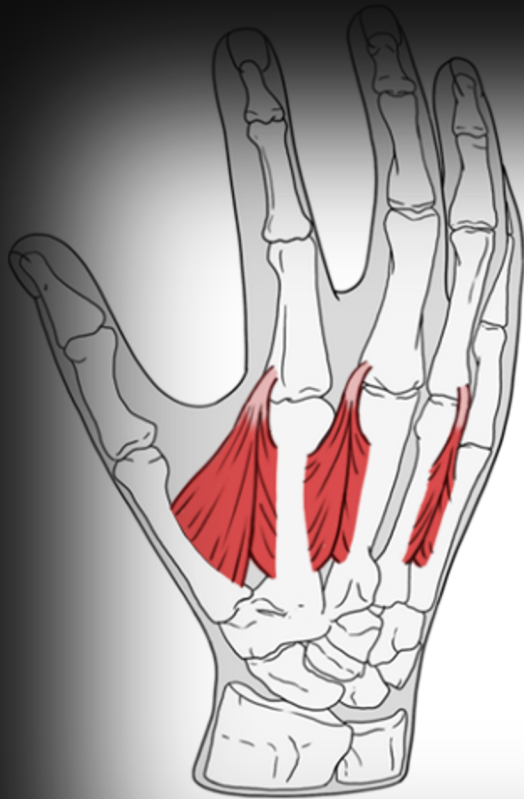

Superficial Dorsal Interossei

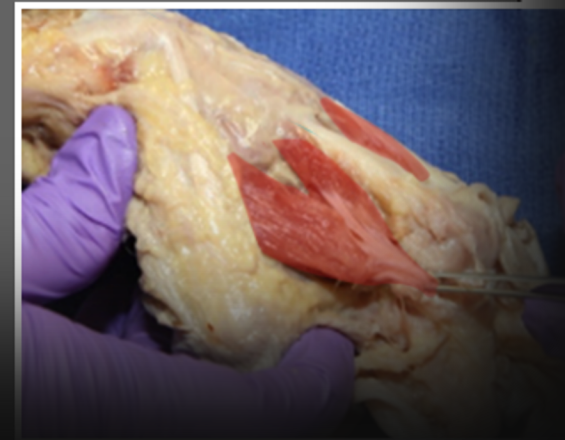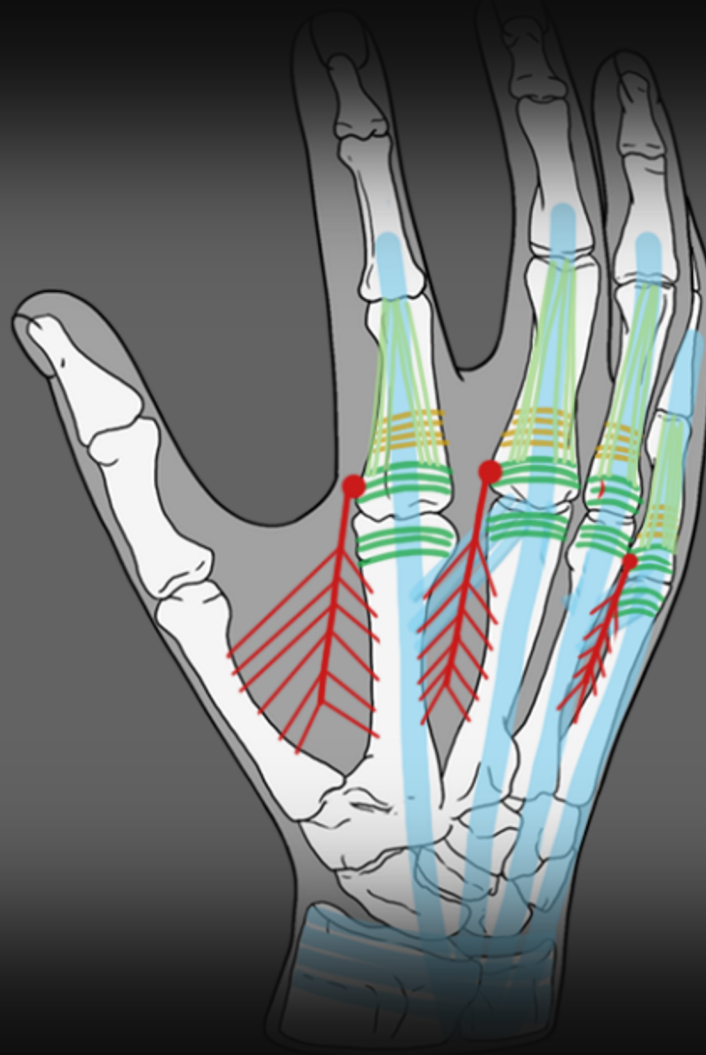


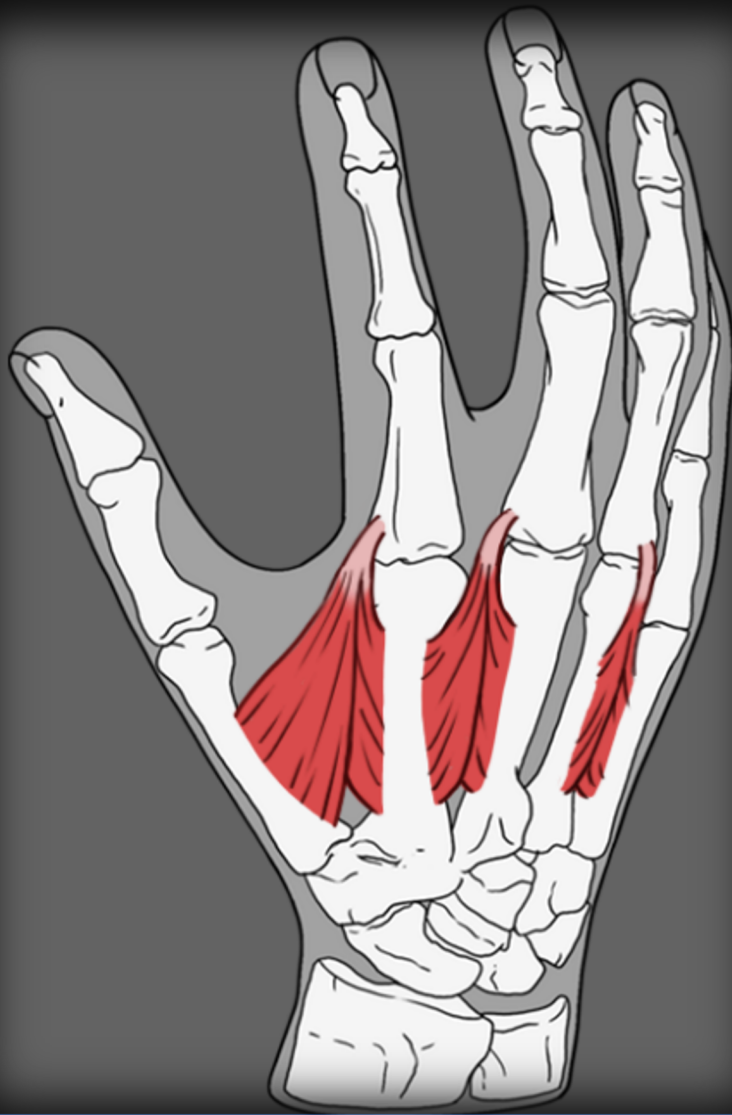
Dorsal Hand

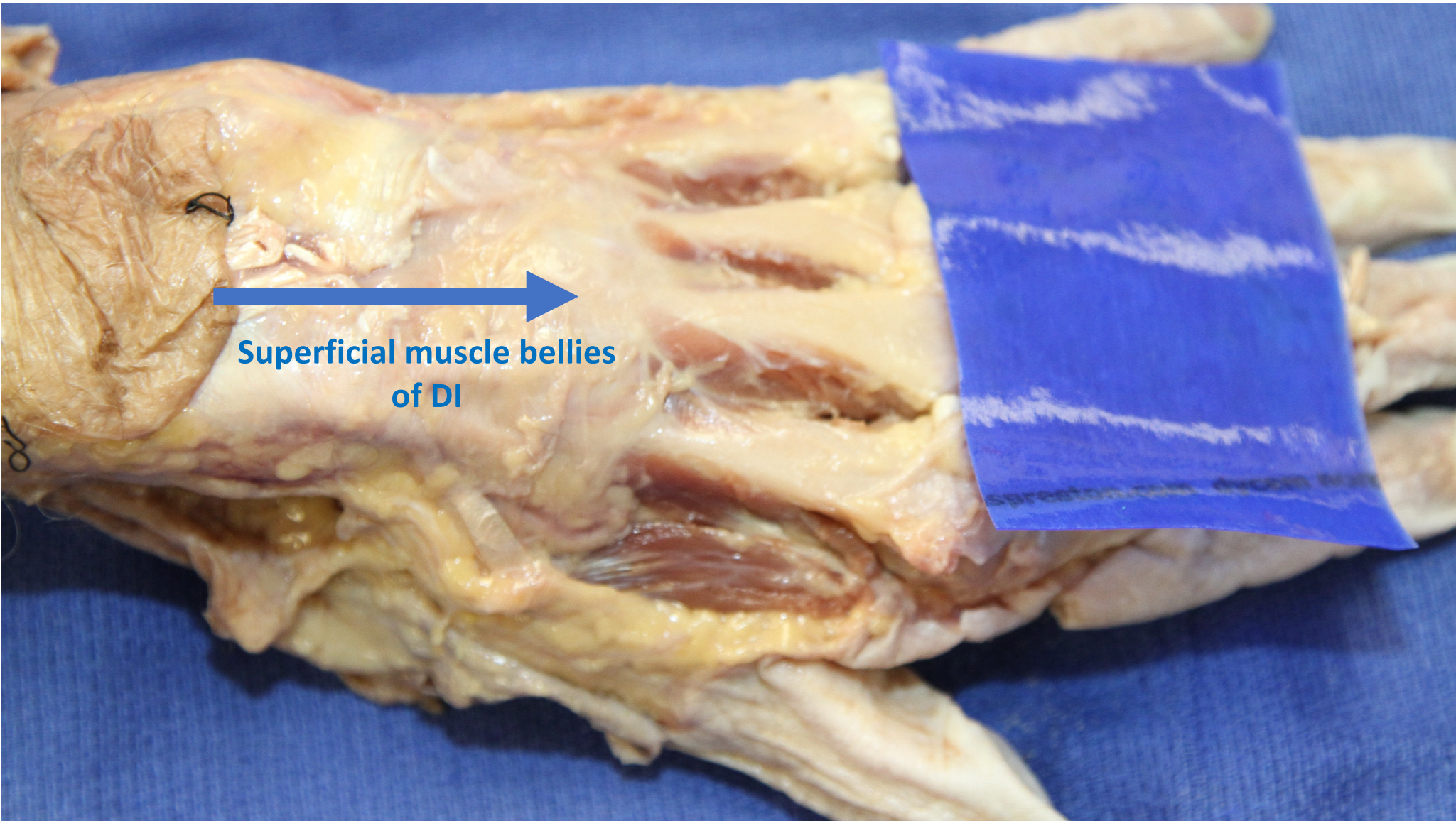




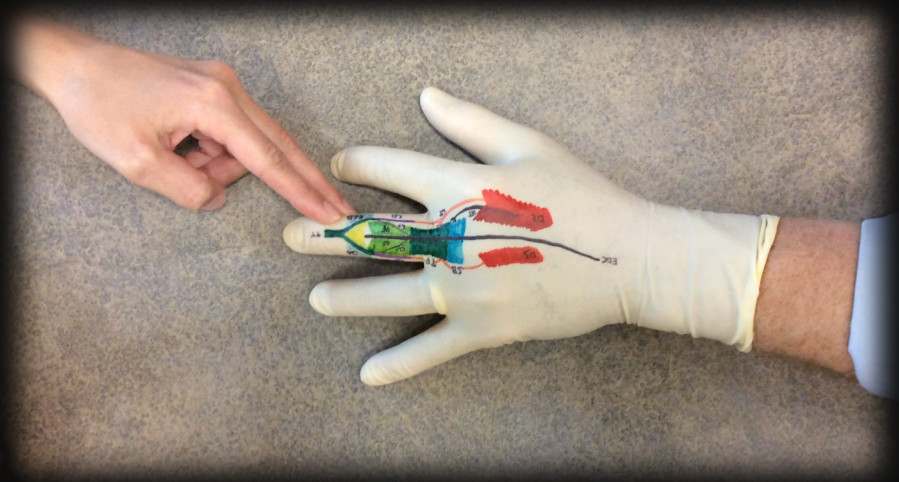
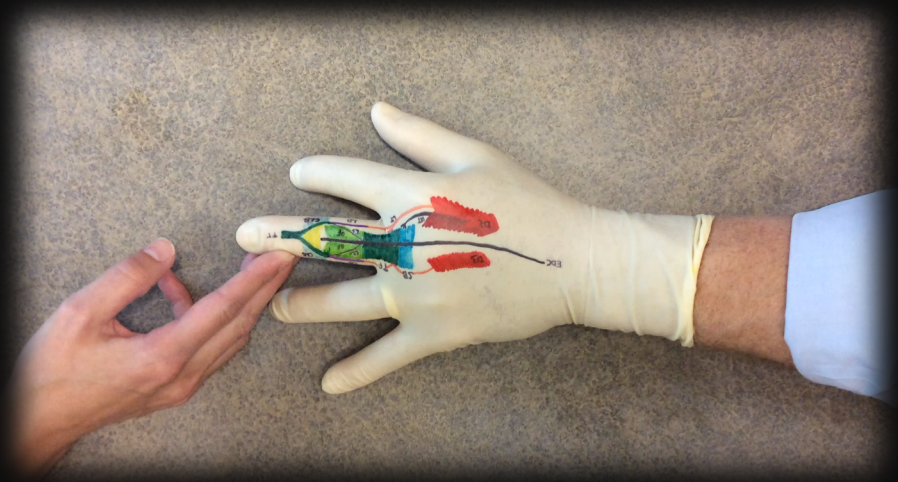
O - Insert into bone

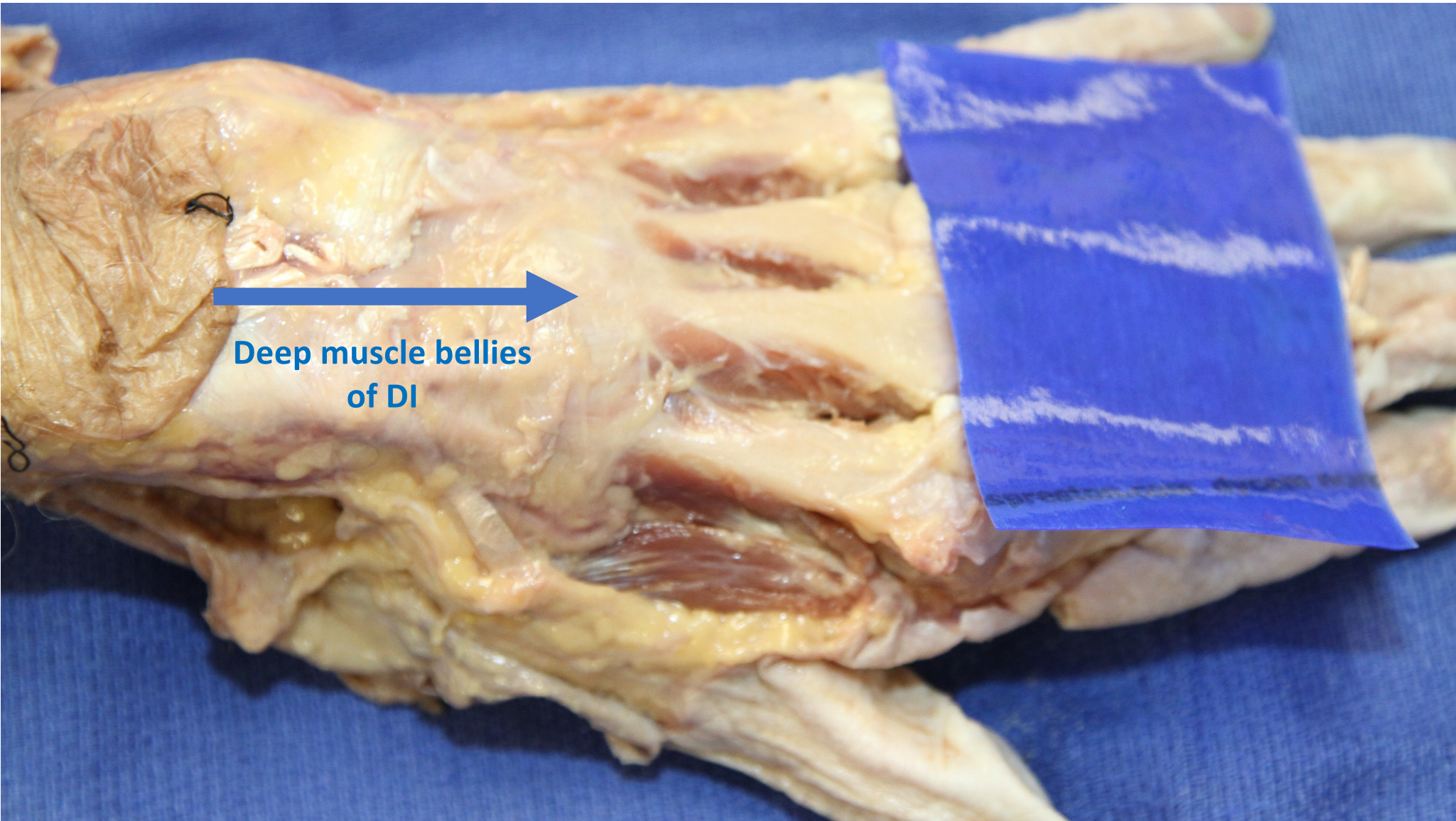




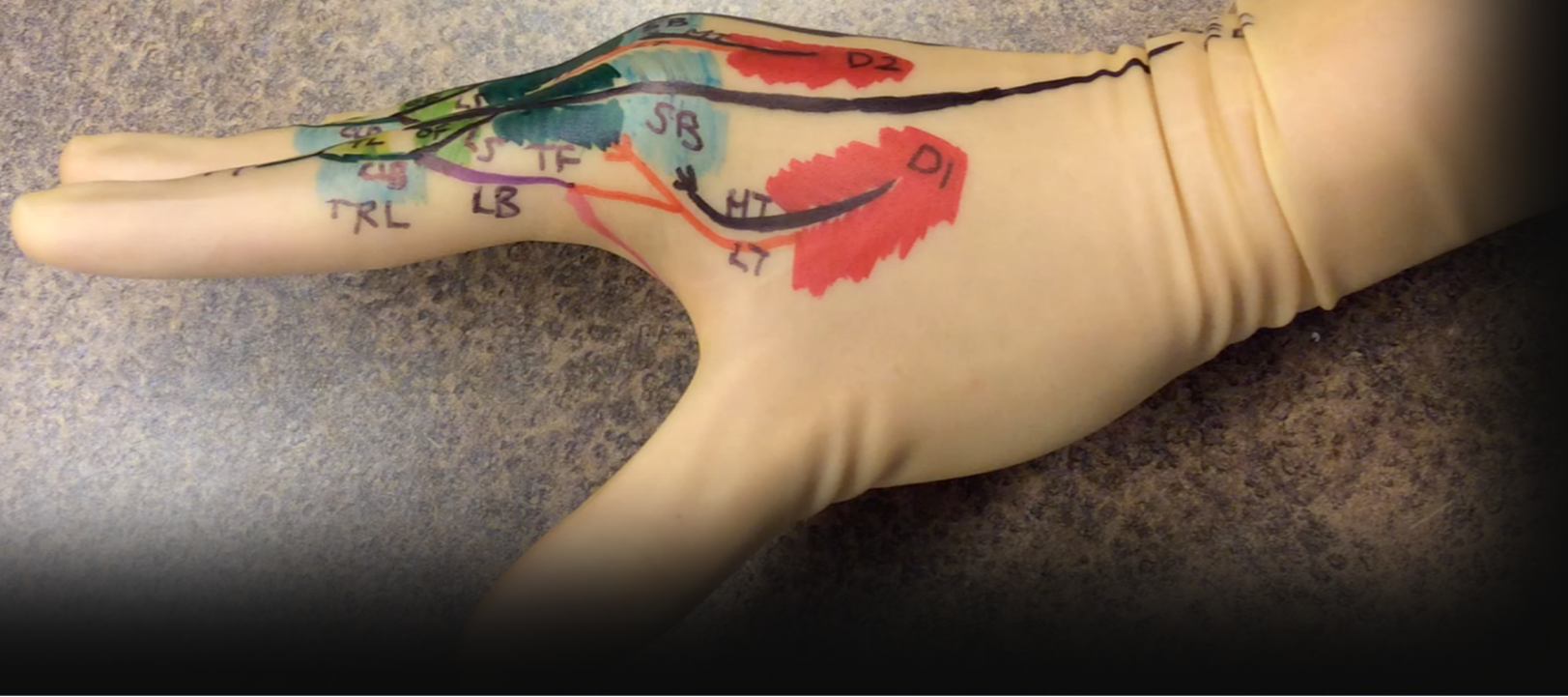

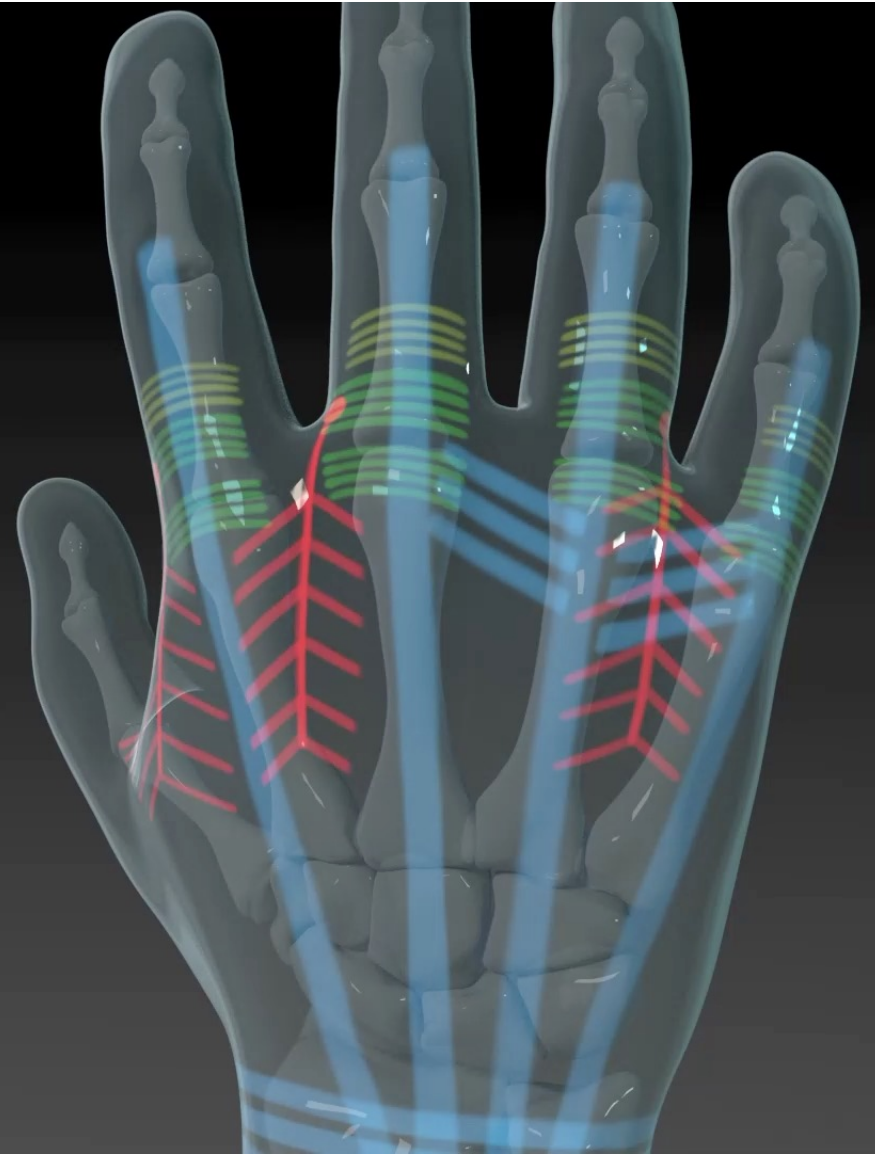
Superficial muscle bellies
of DI



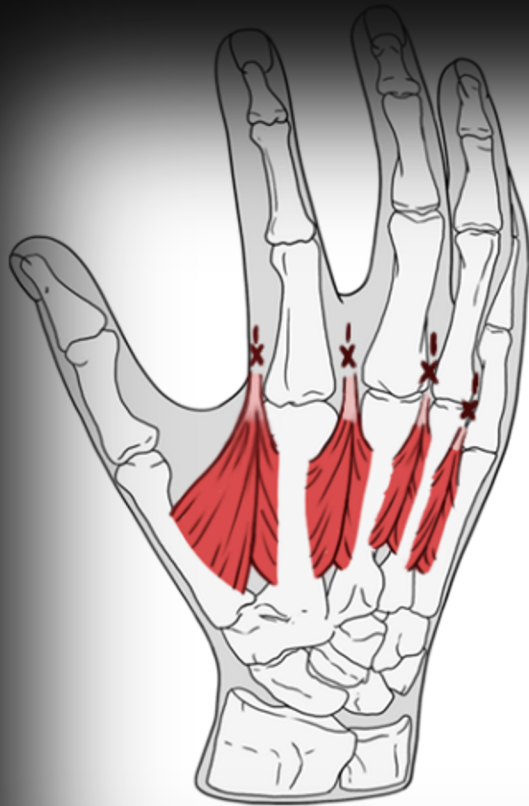

Deep muscle bellies
of DI

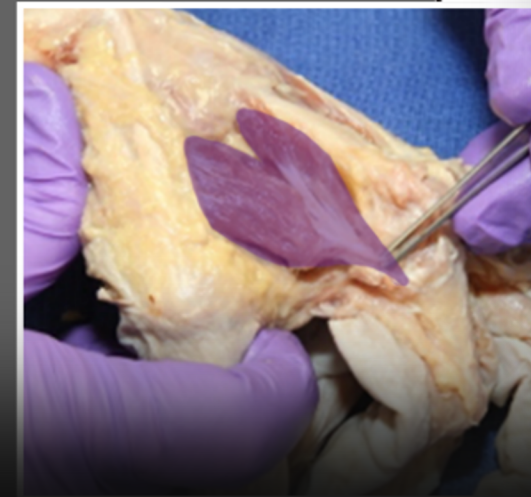
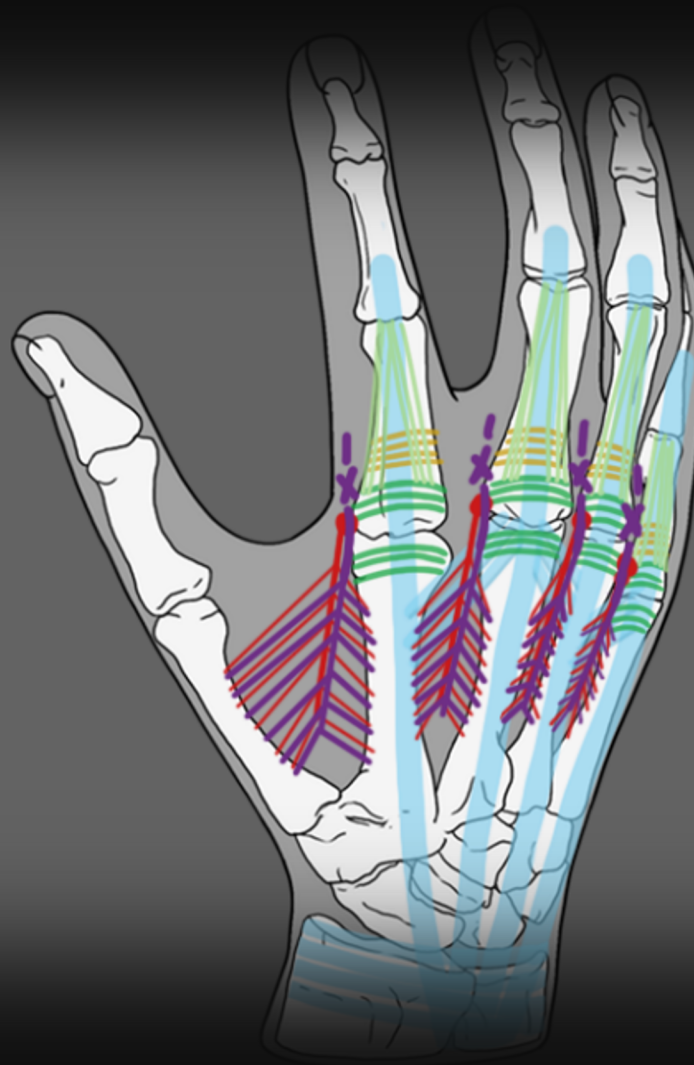


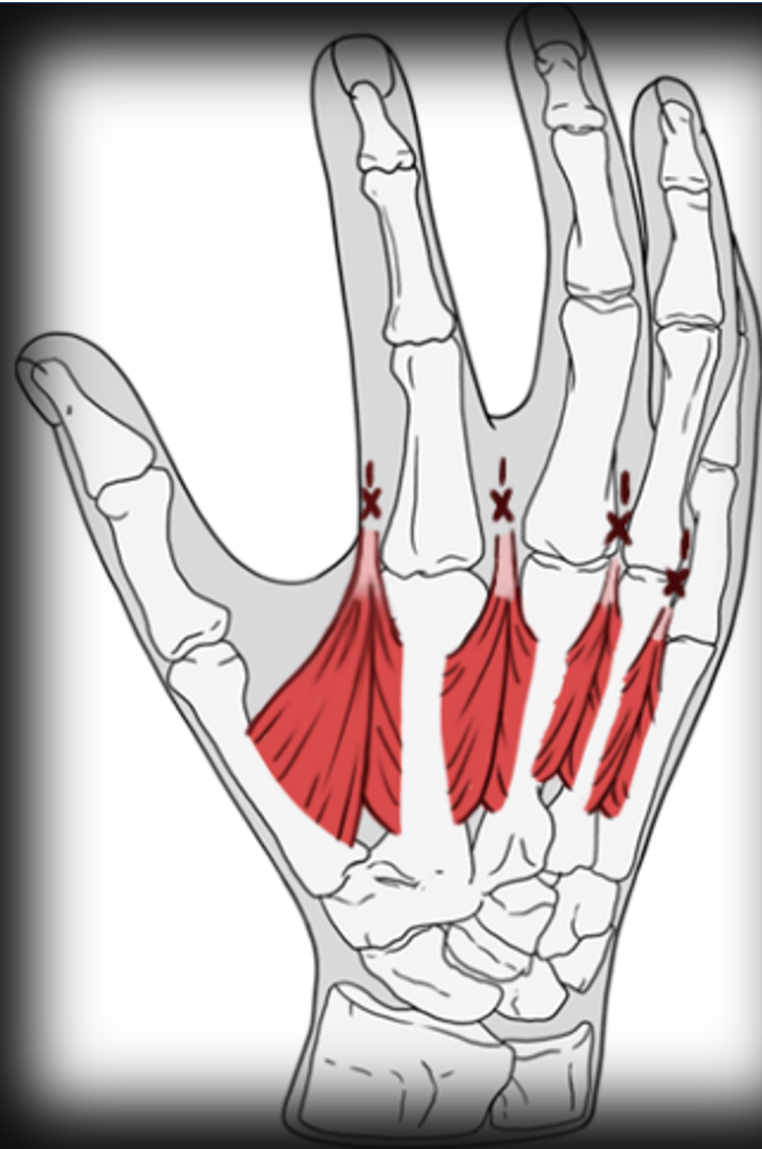


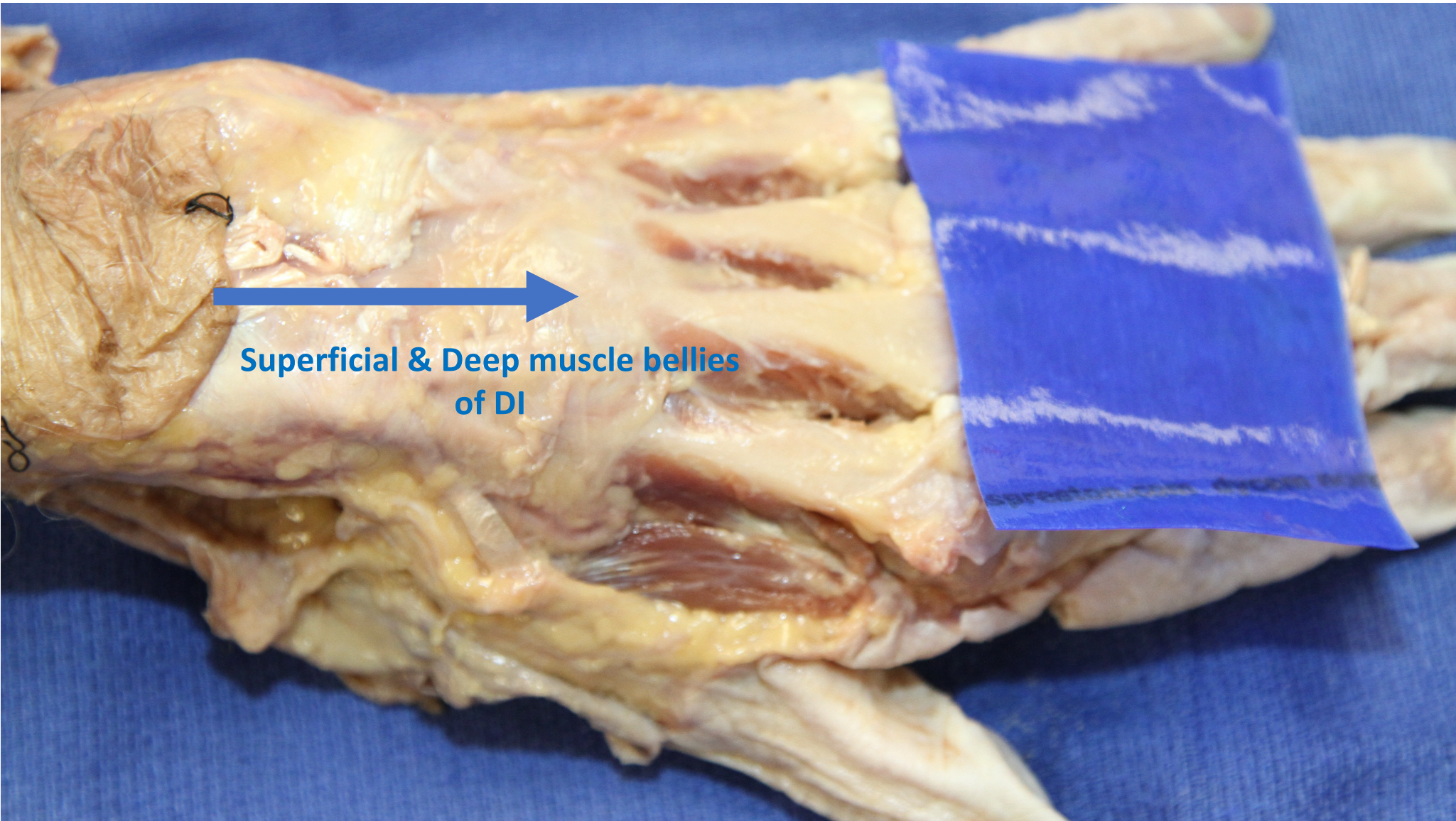
Dorsal Hand



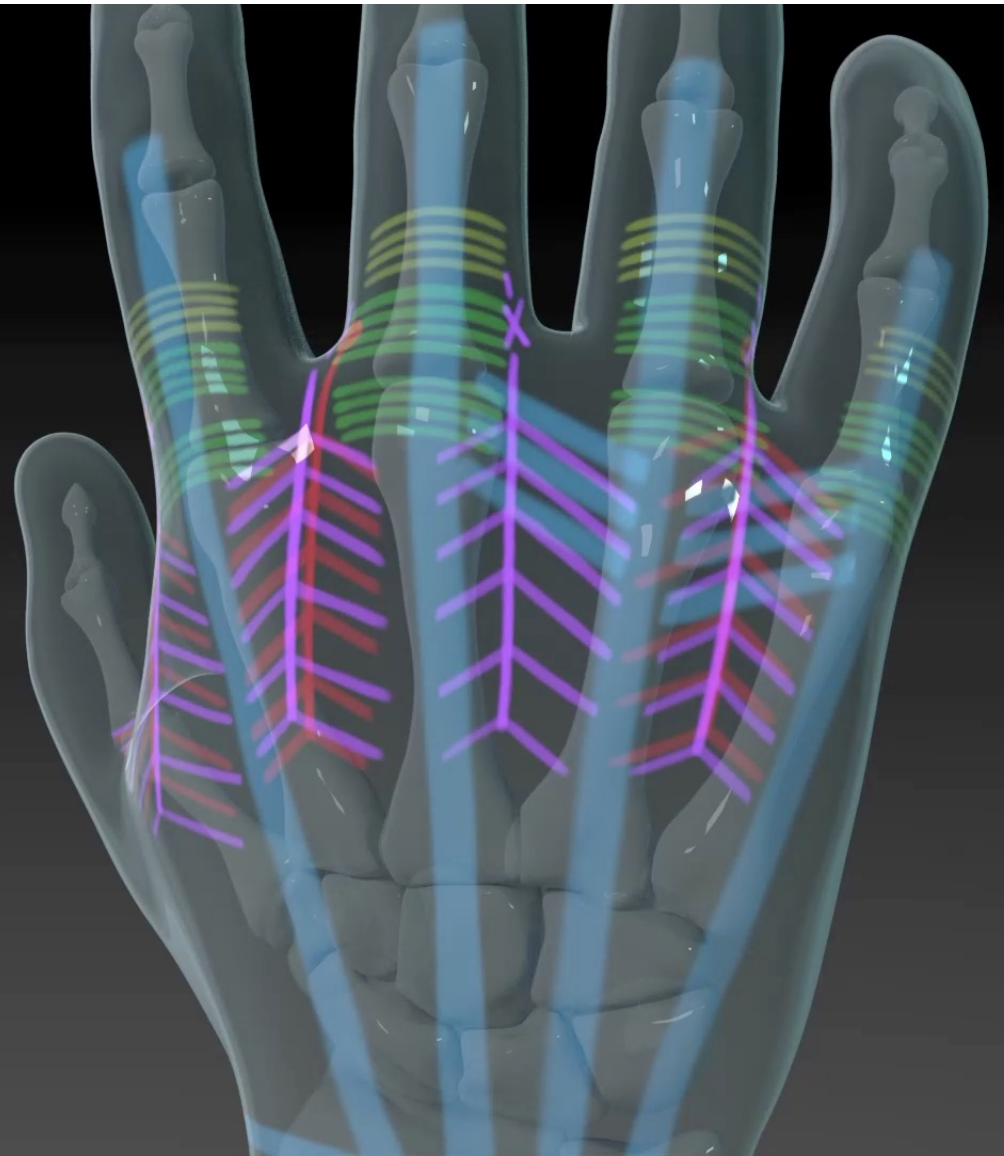
X - Insert into Tissue



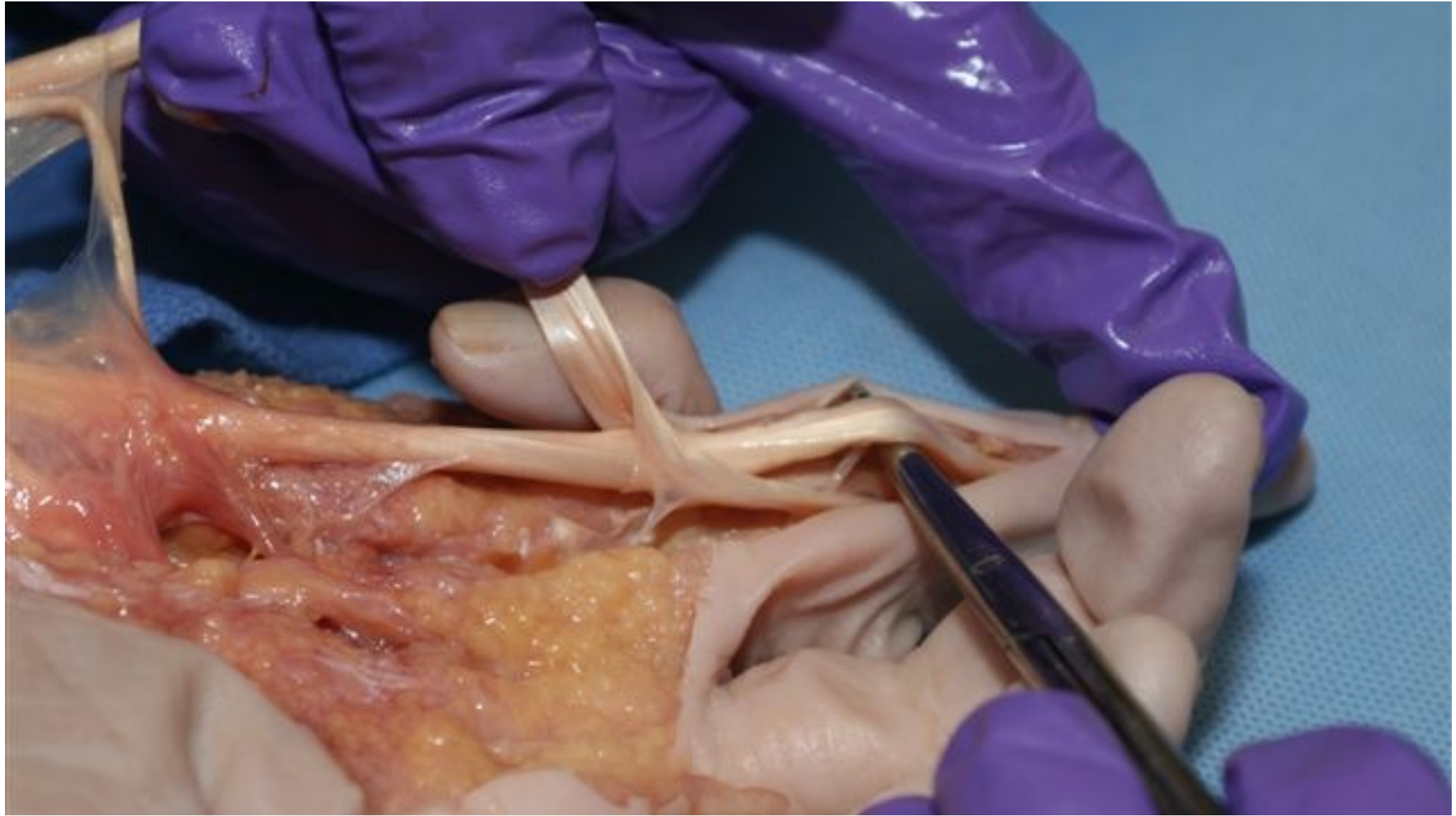




**Superficial & Deep muscle bellies
of DI**

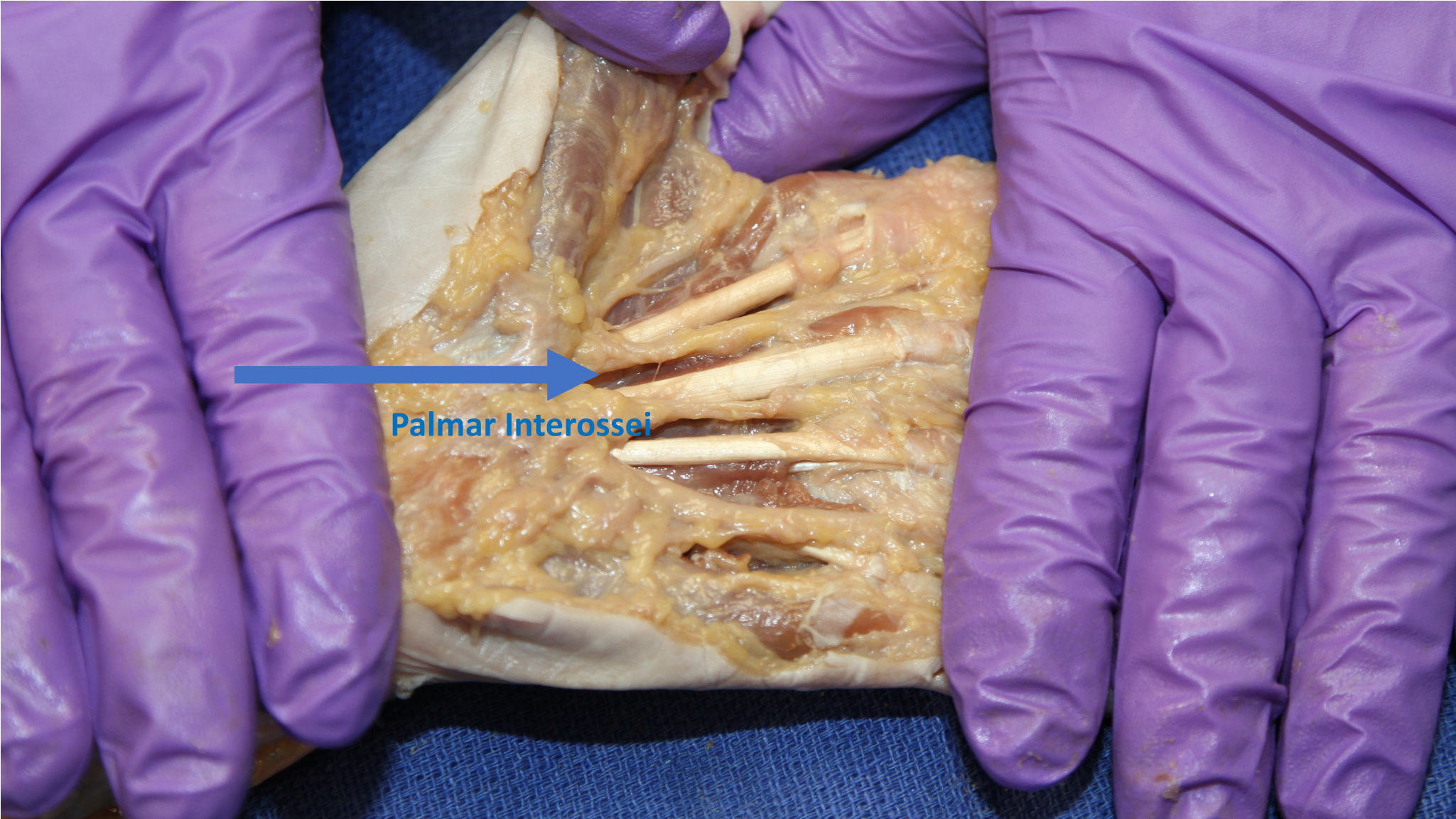


Dorsal Hand

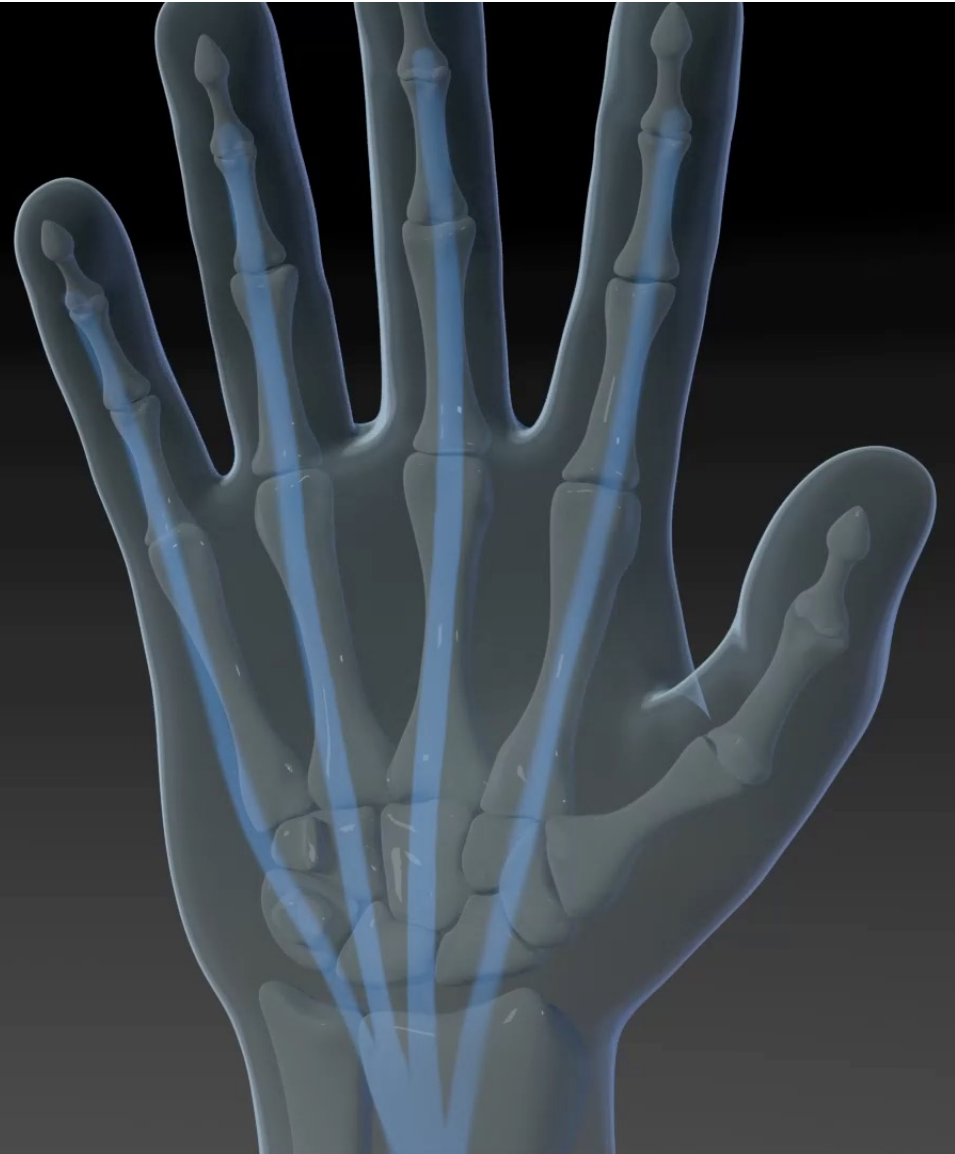



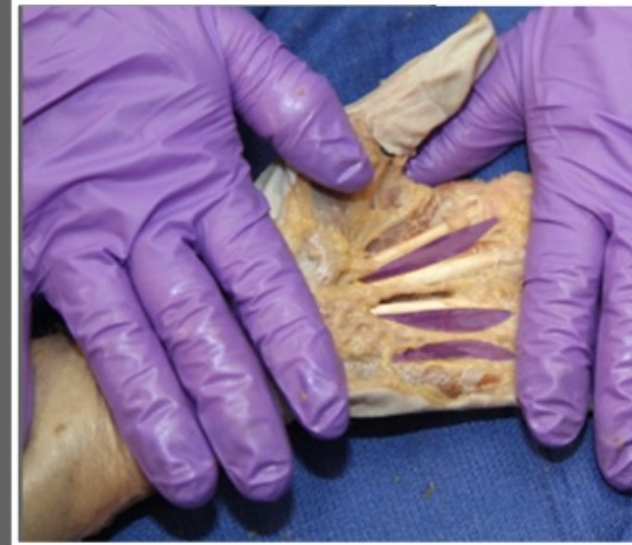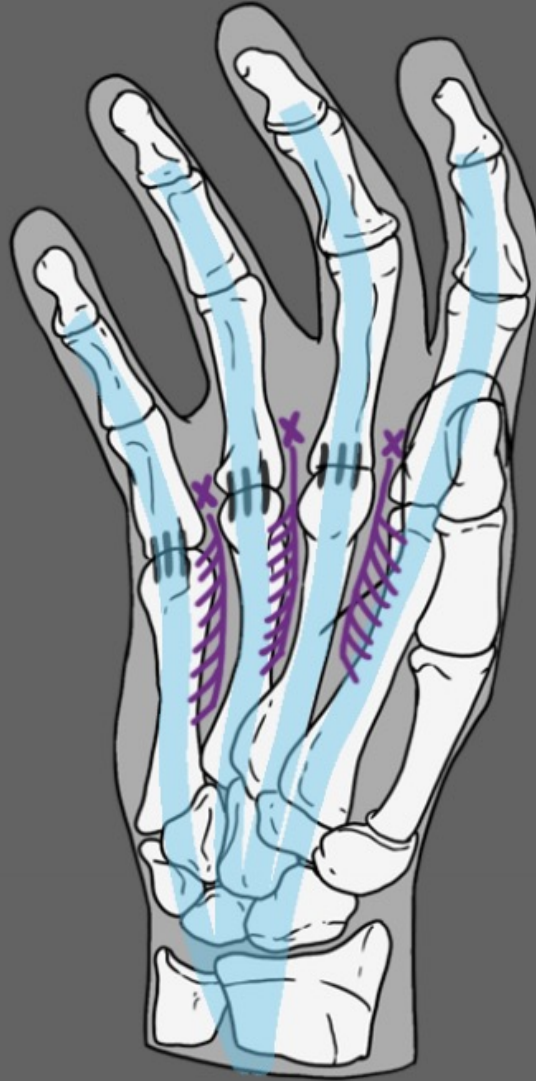
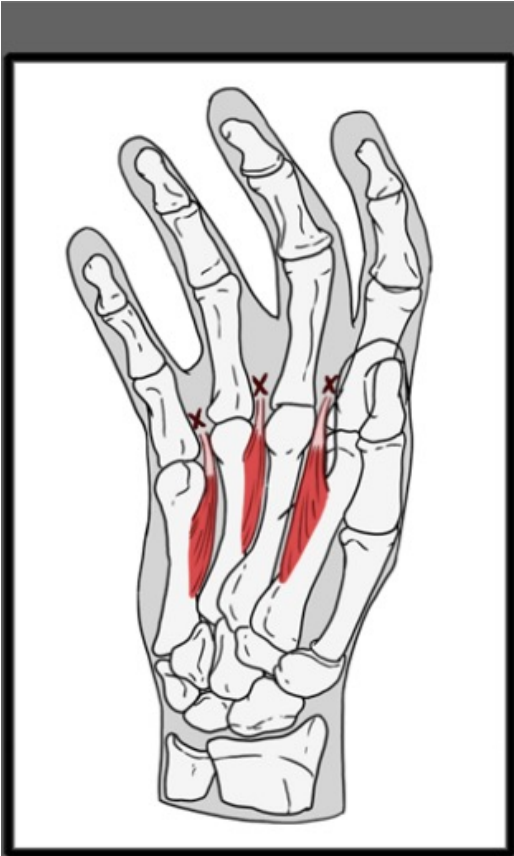
Palmar Interossei

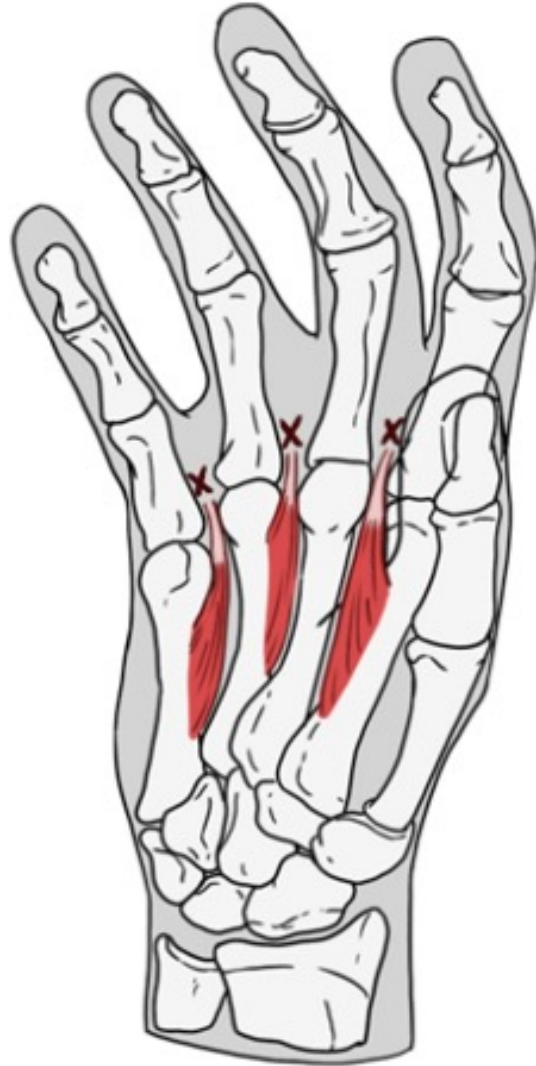


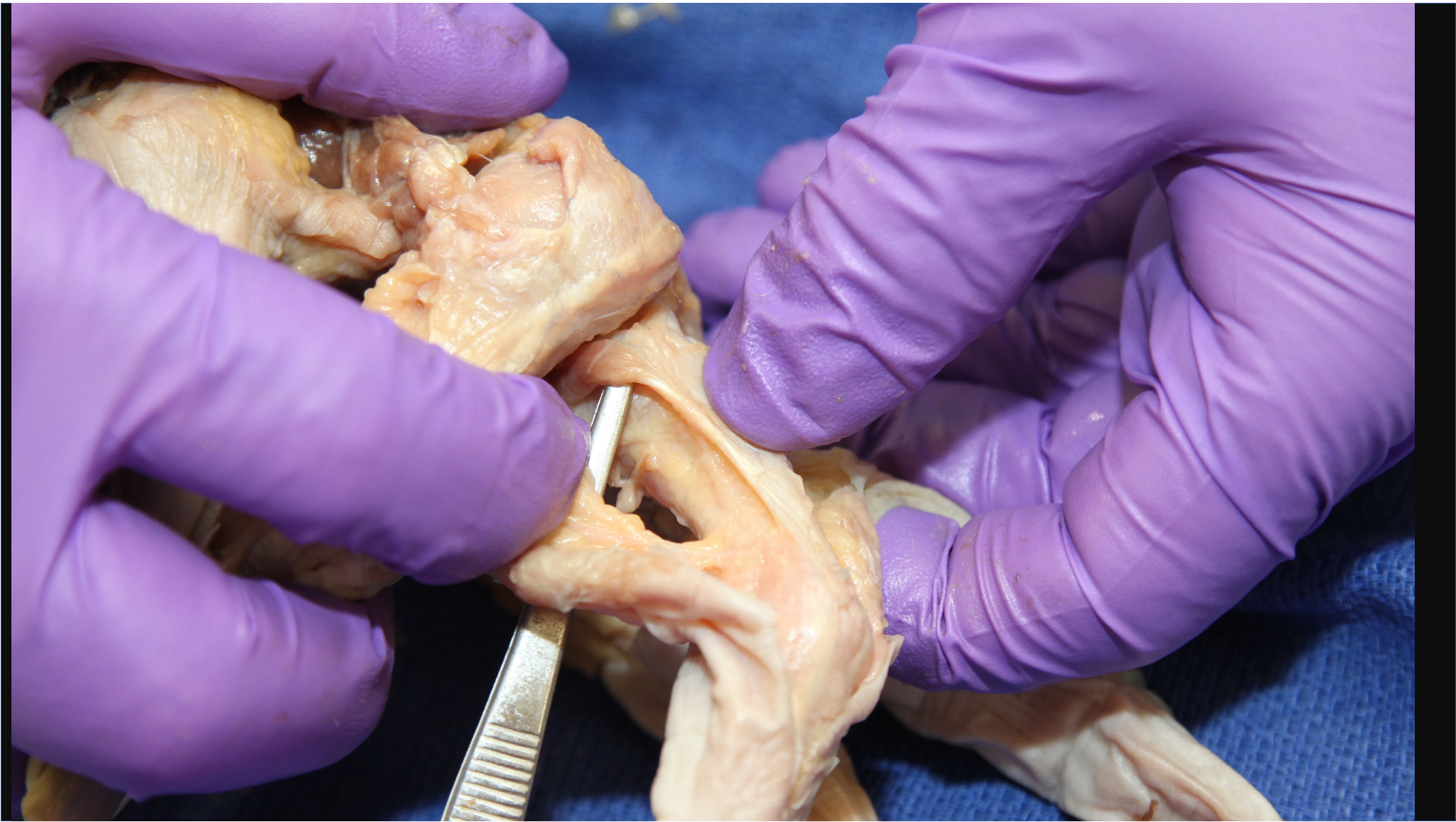


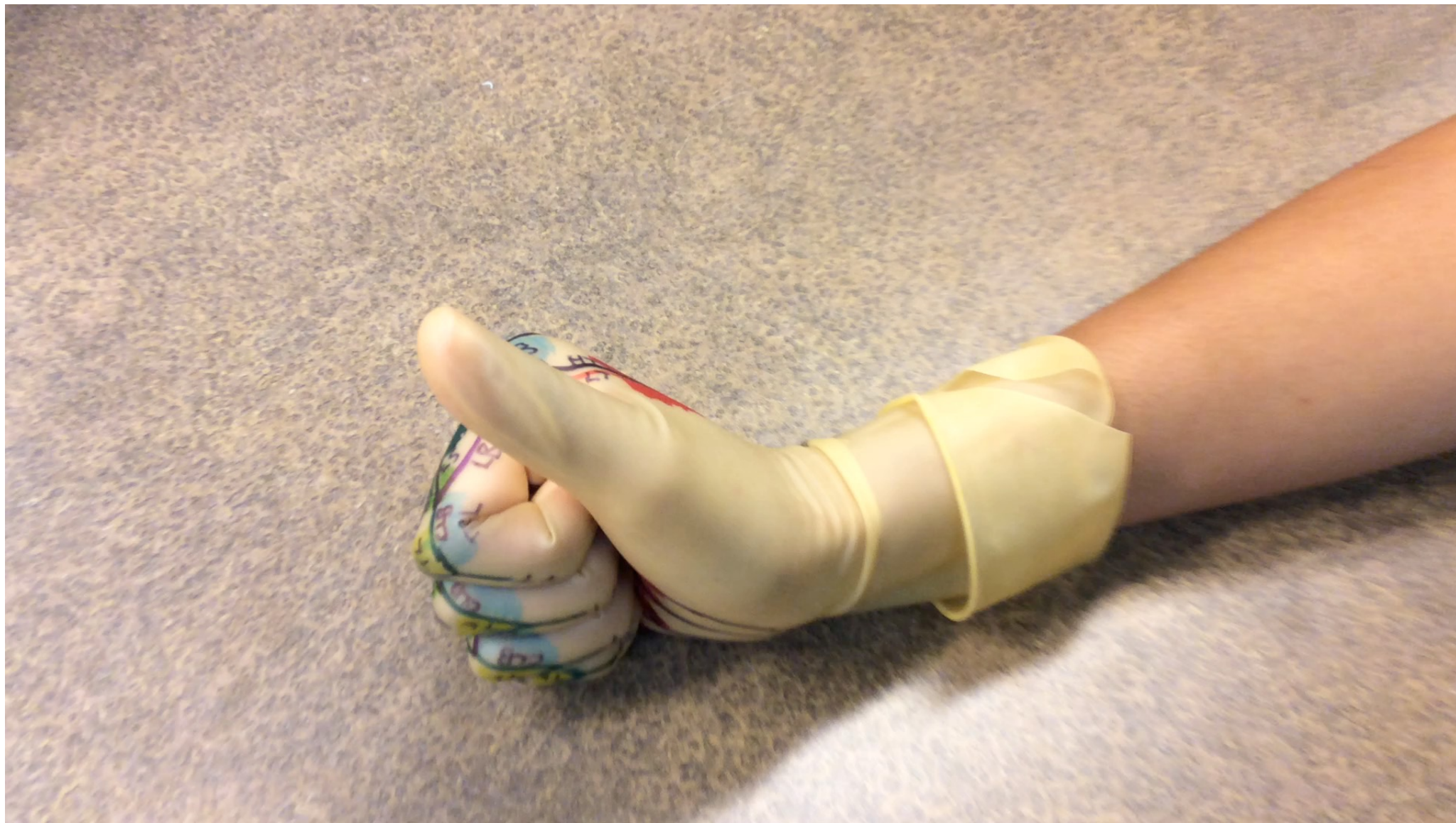
Palmar Hand

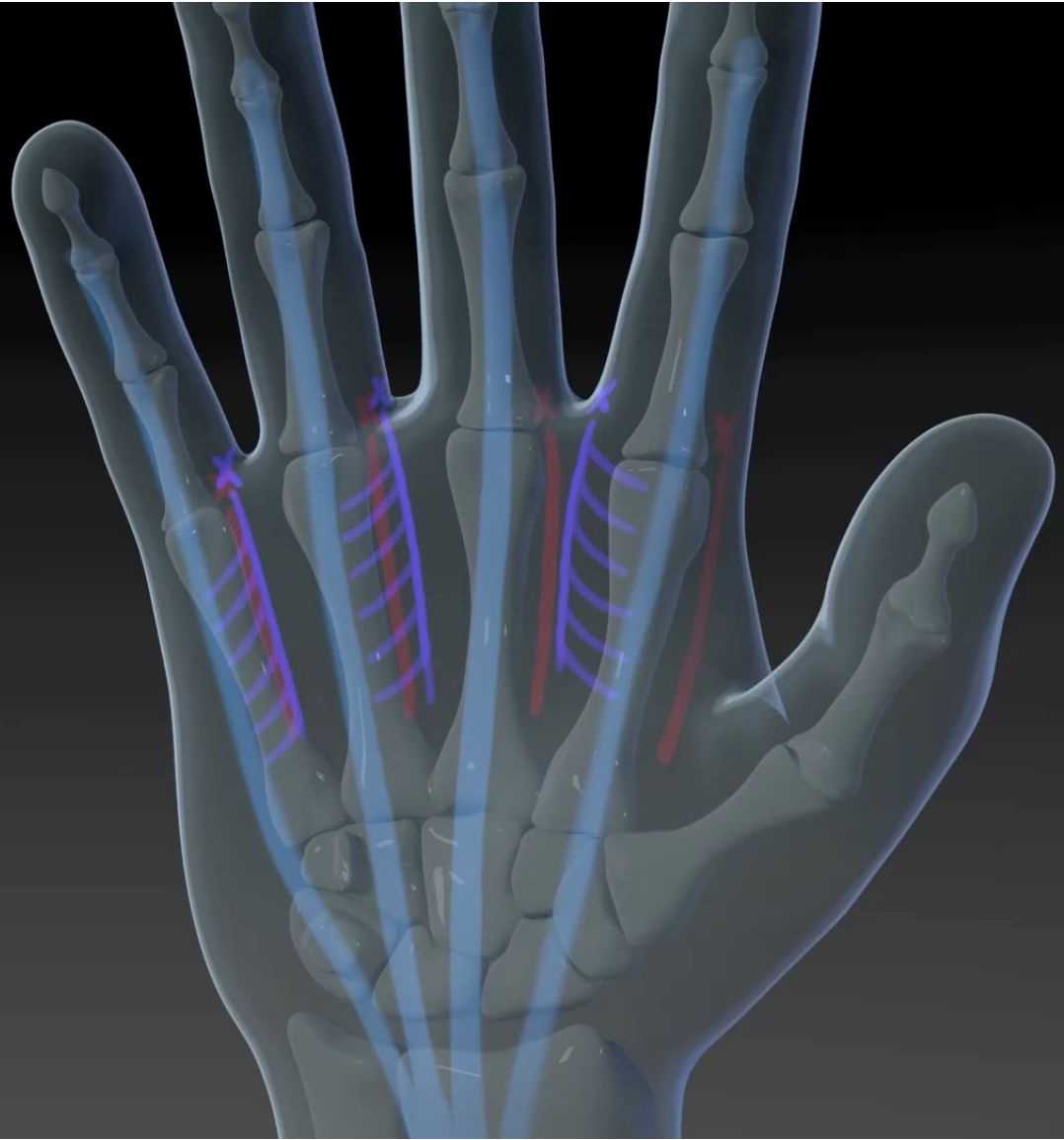




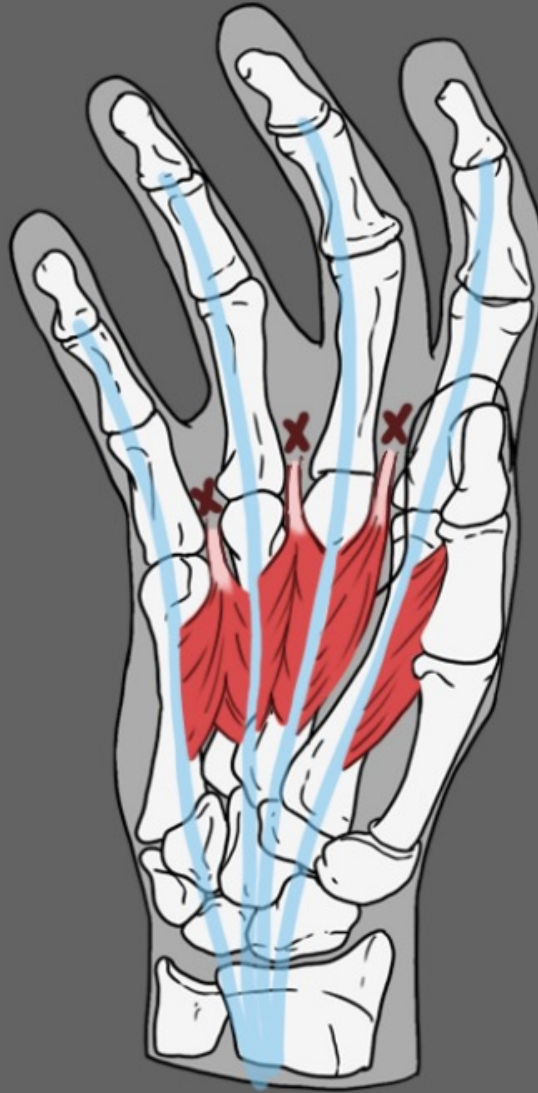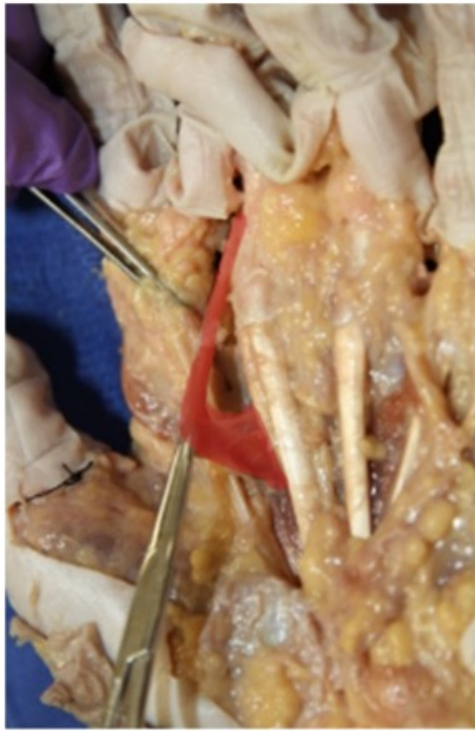


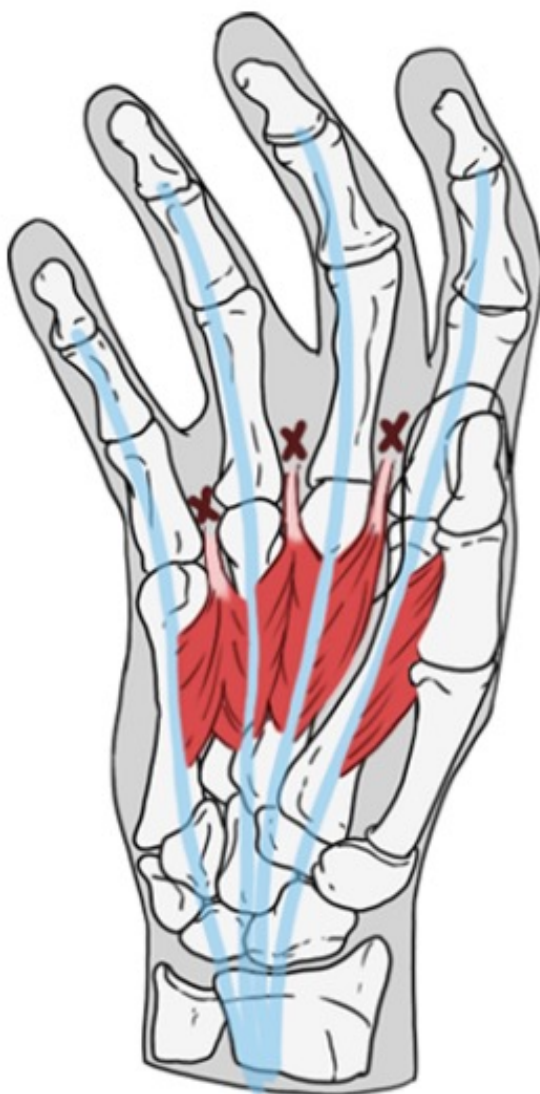


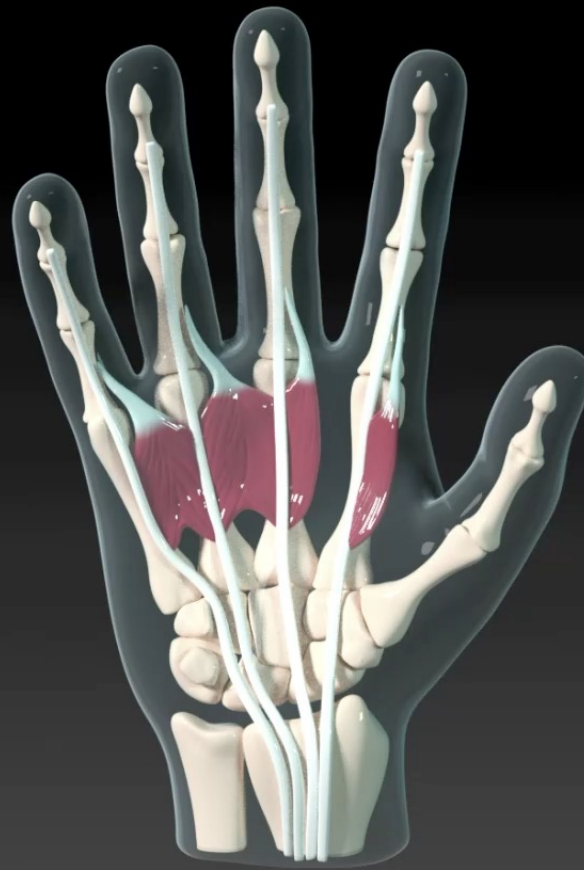Lumbricals

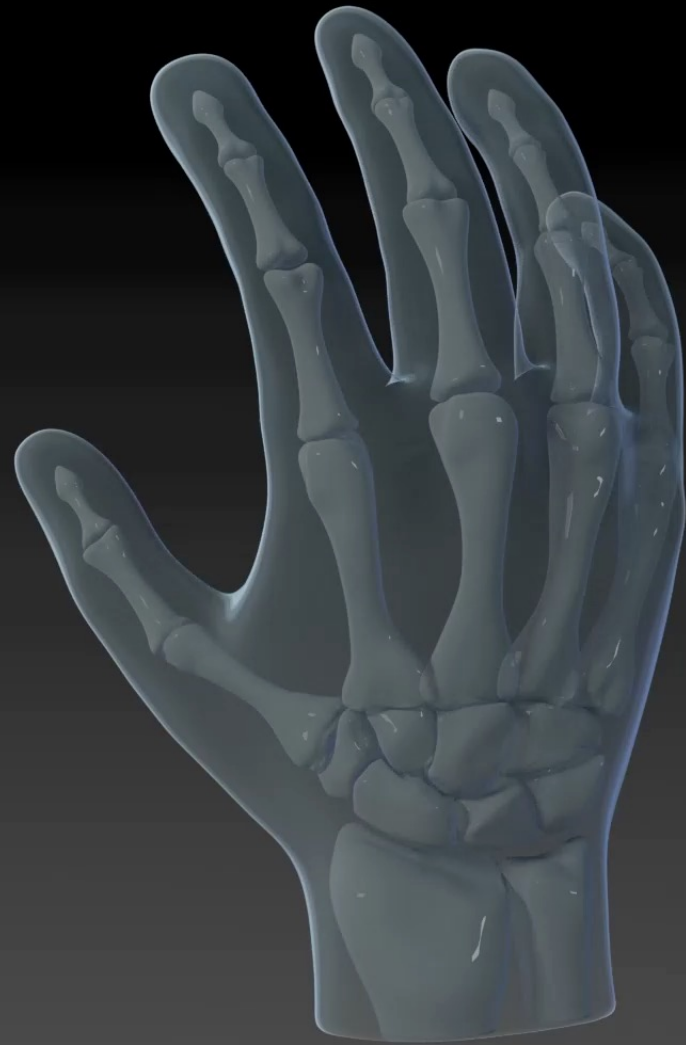

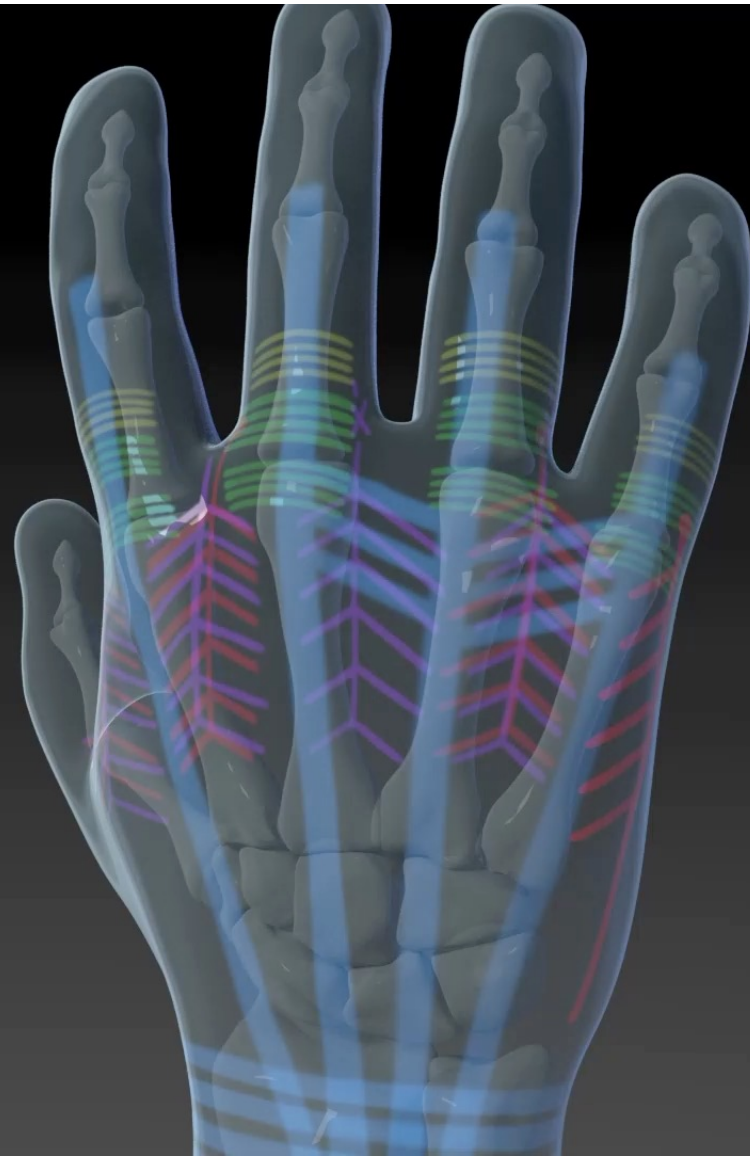
Palmar Hand



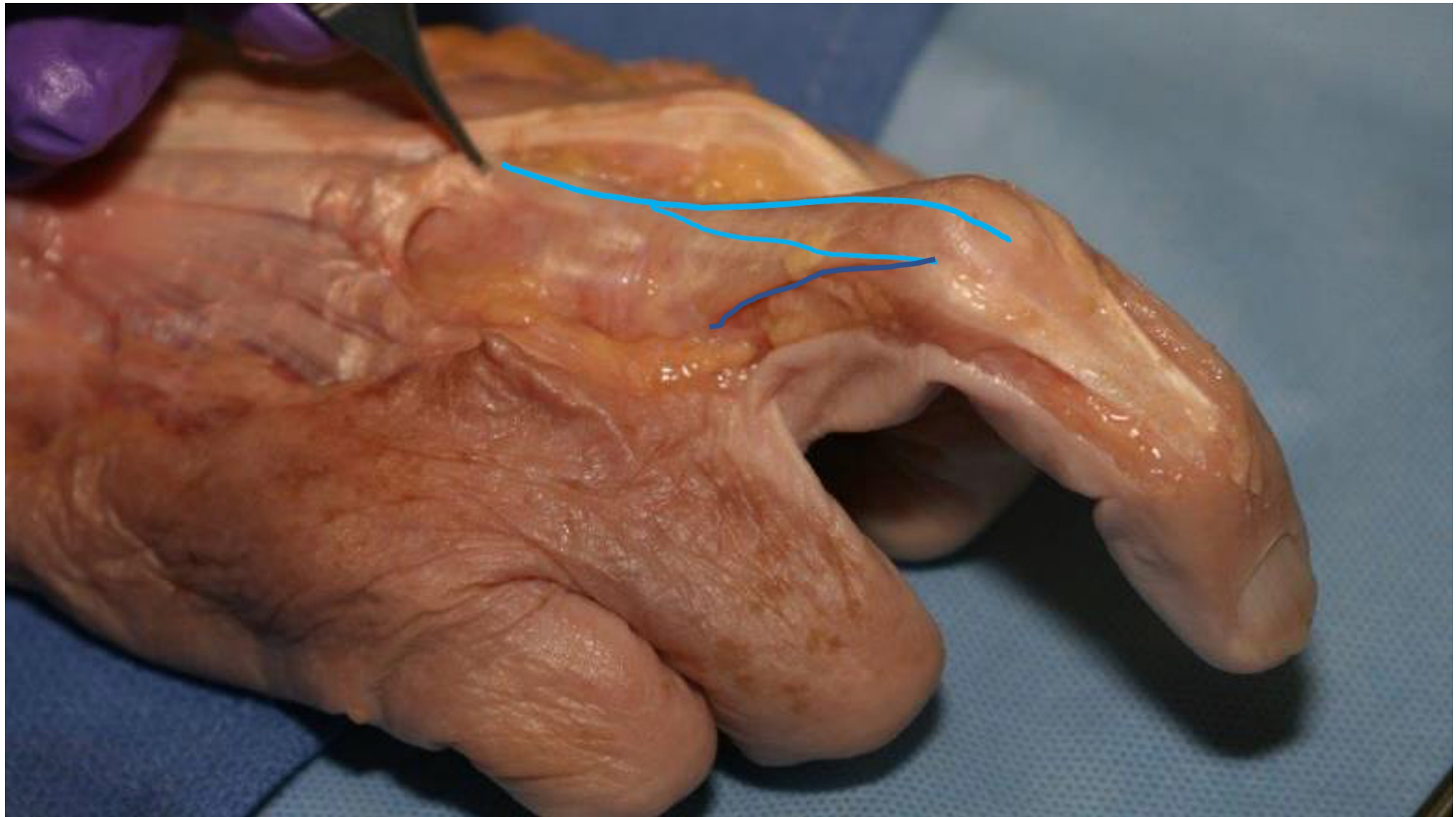




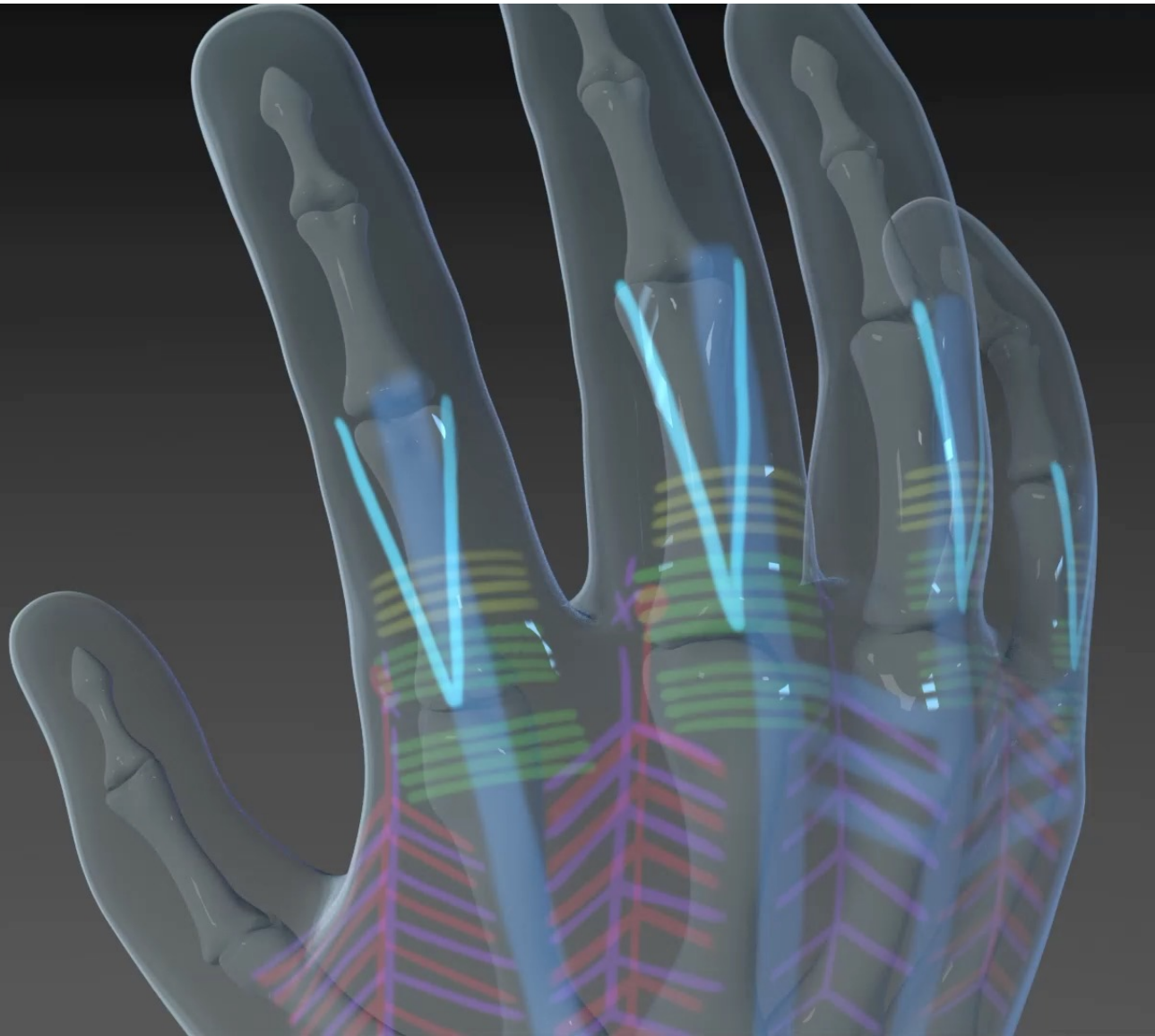
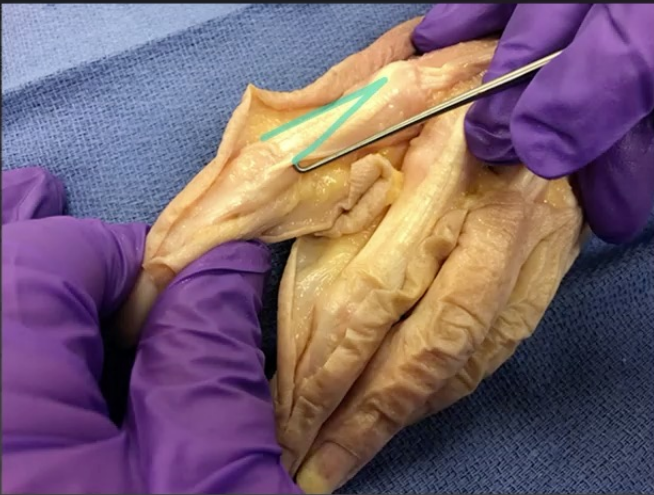



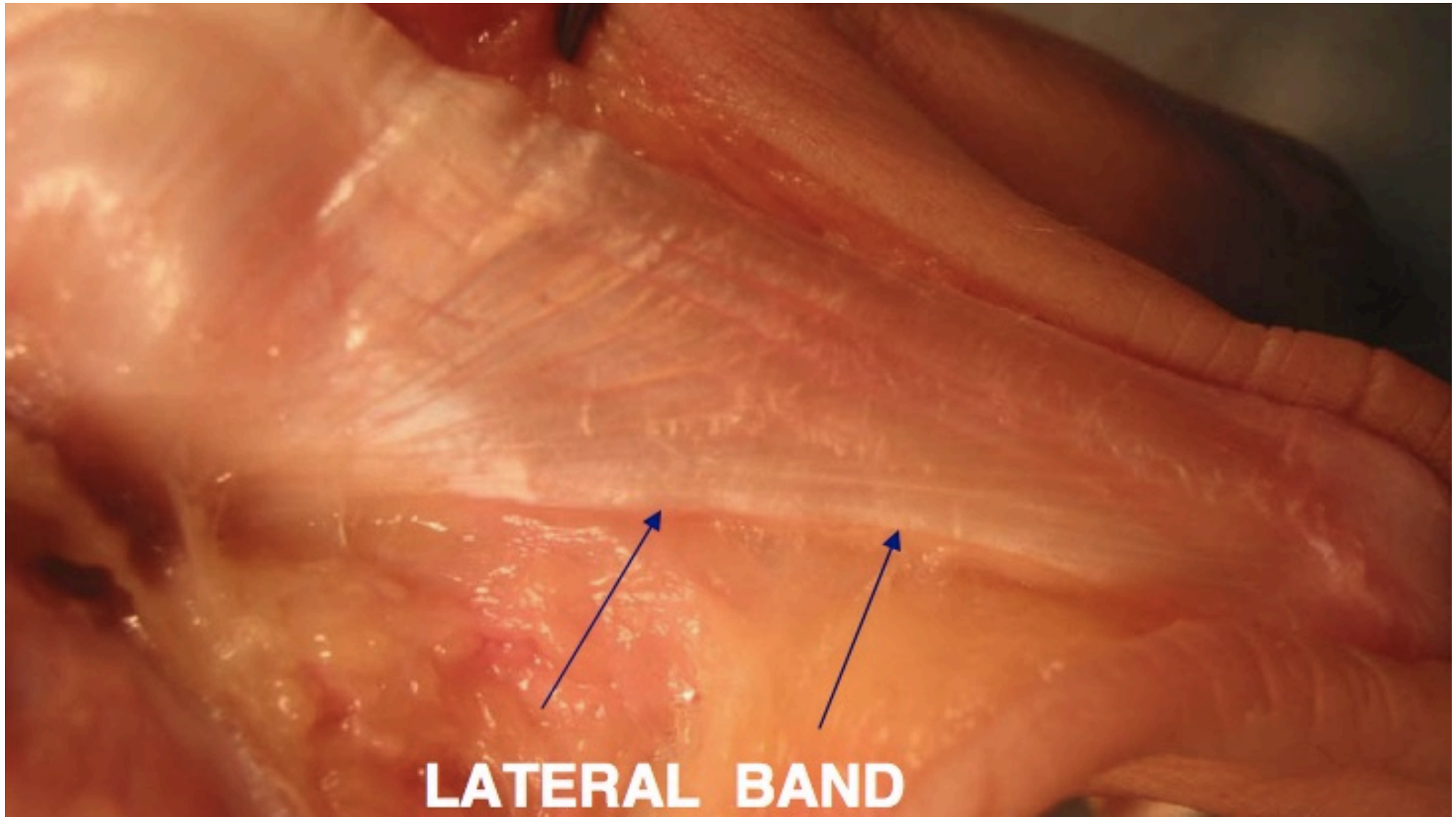
Dorsal Hand



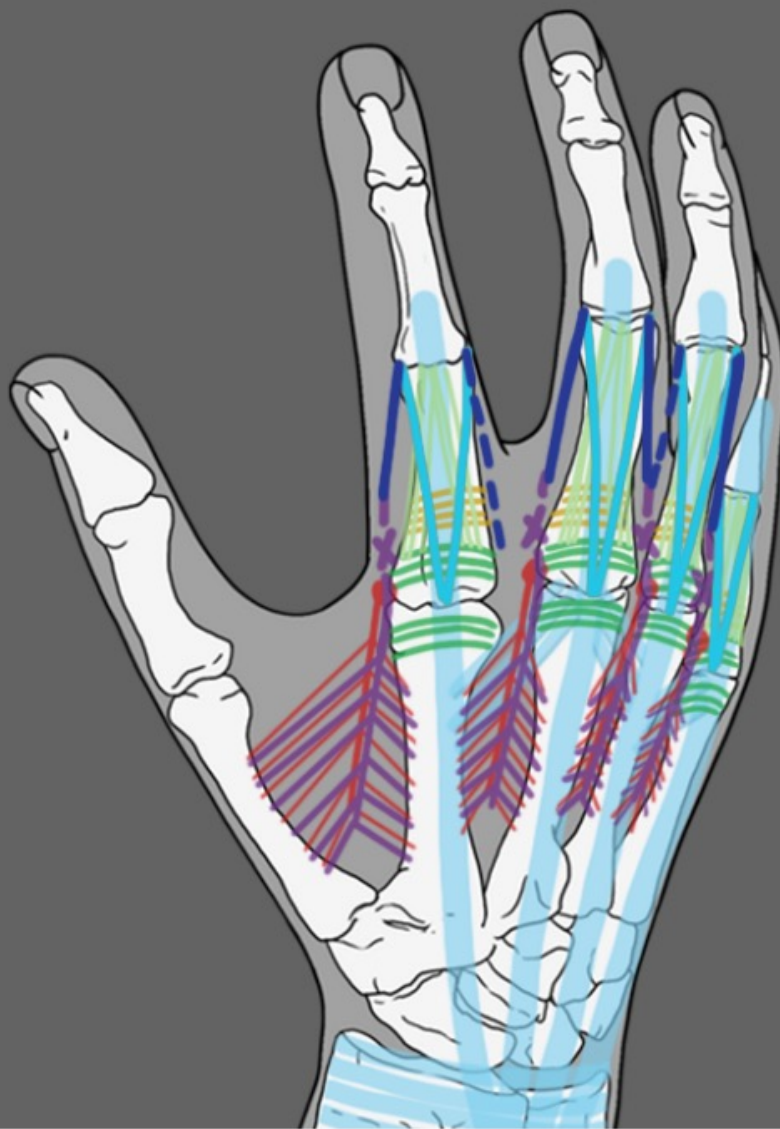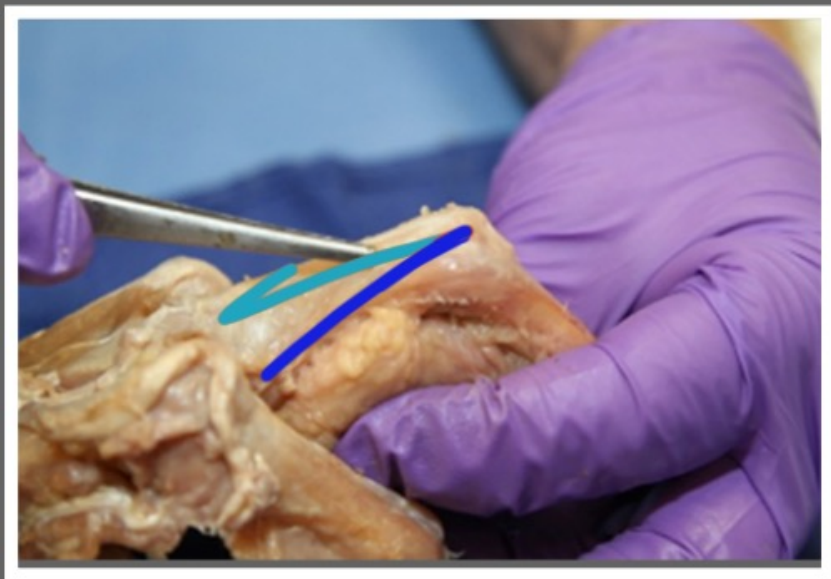
Lateral Slips



Dorsal Hand

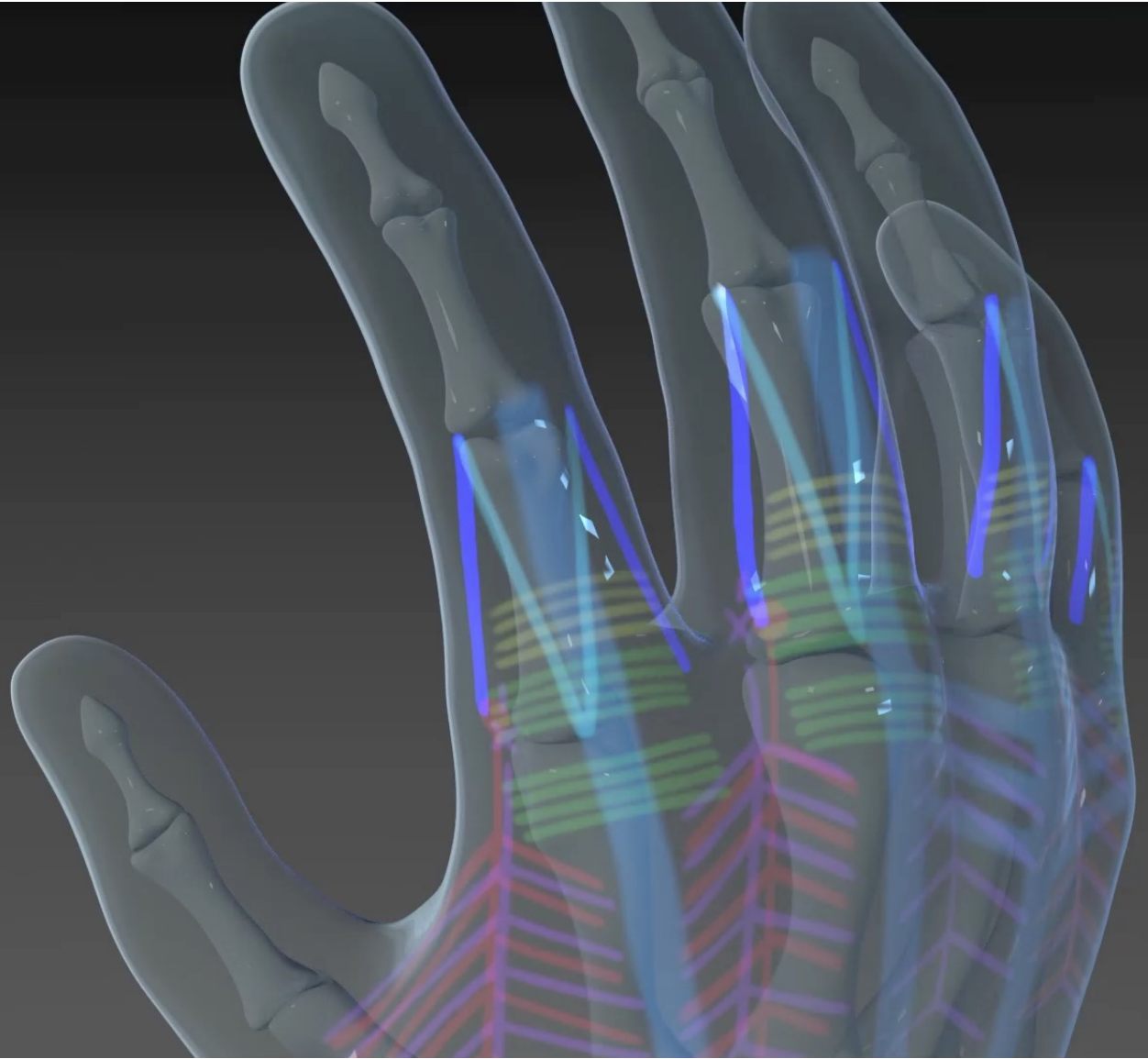


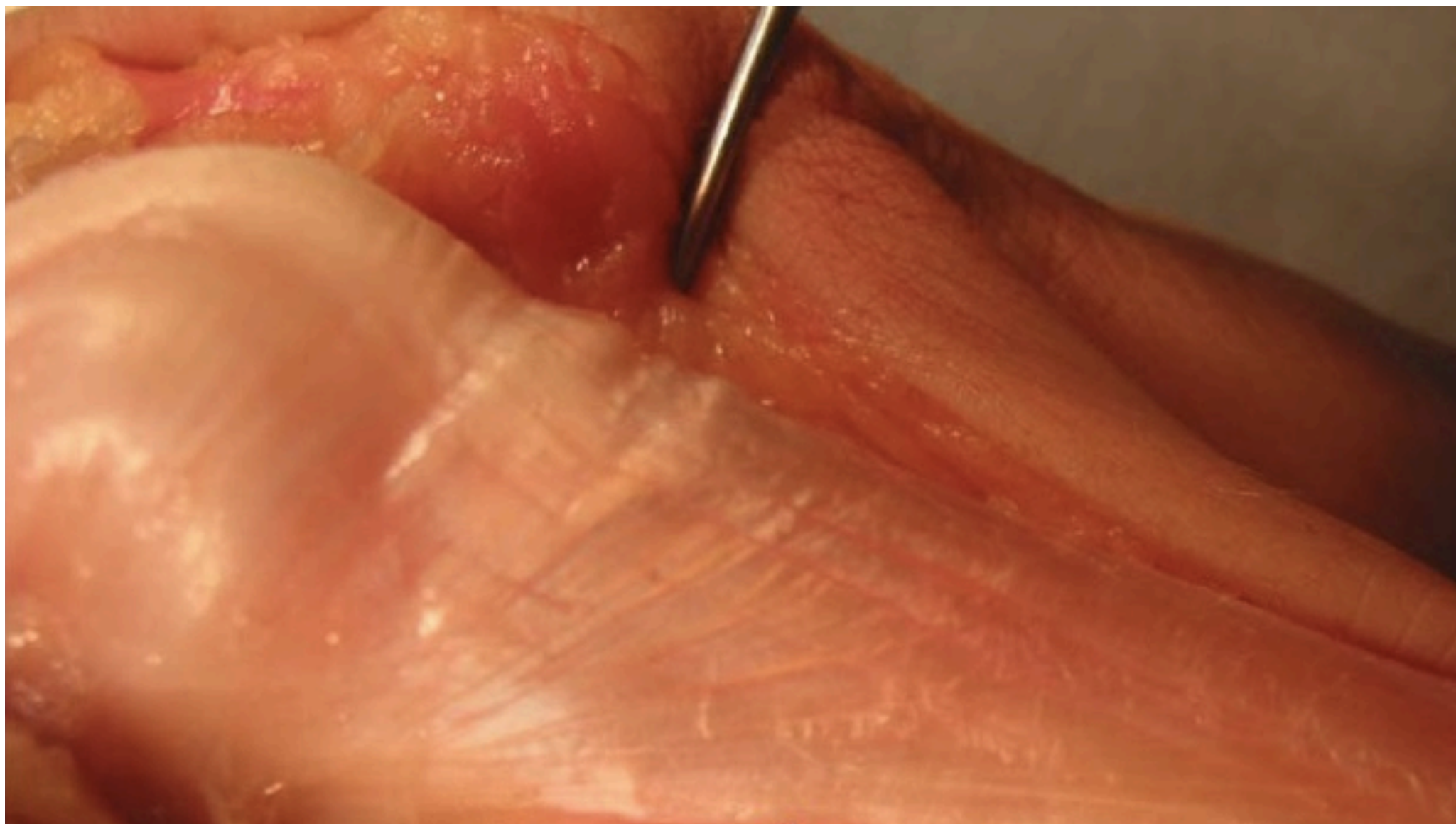
LATERAL BAND



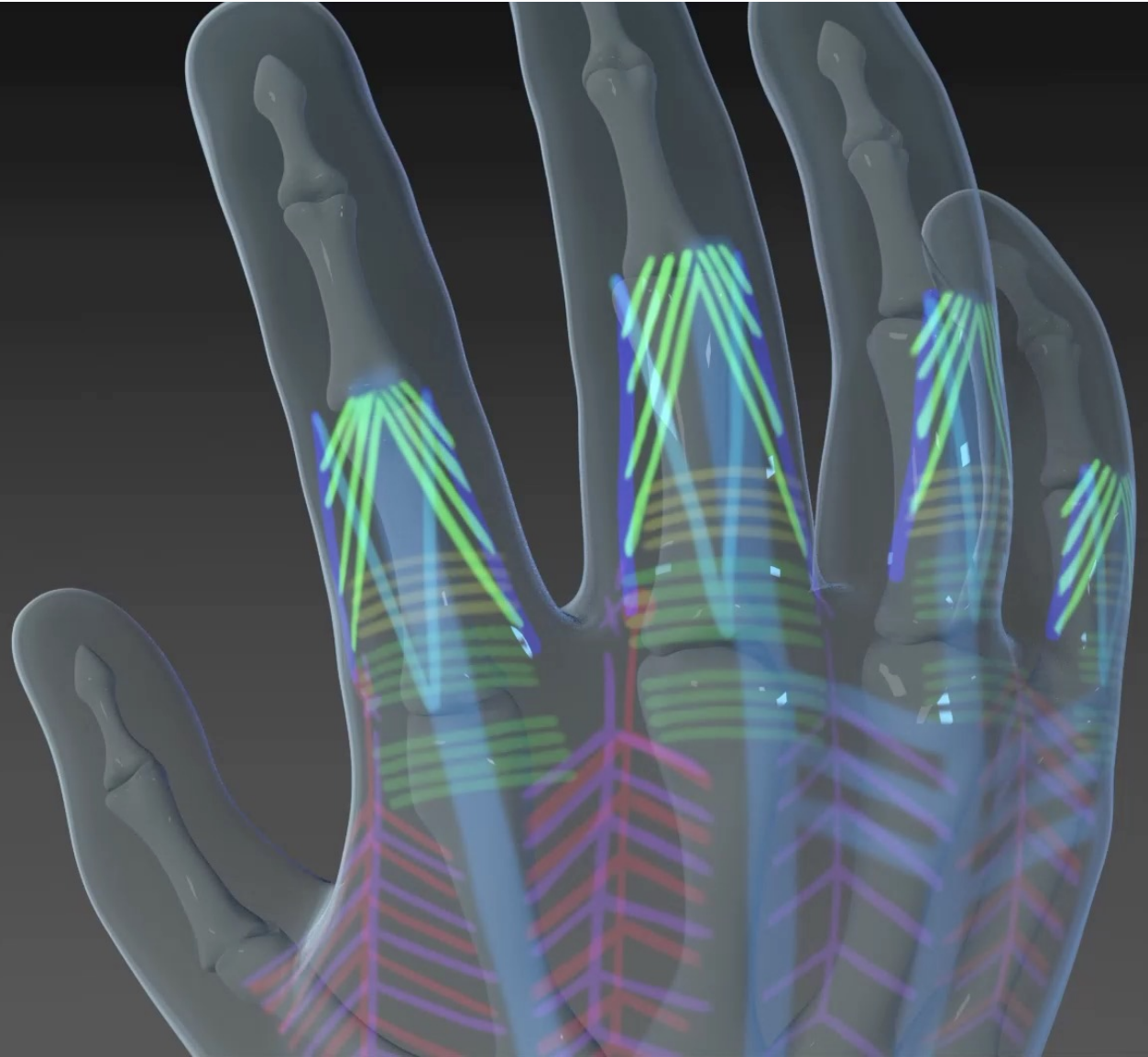
Oblique Fibers

Dorsal Hand

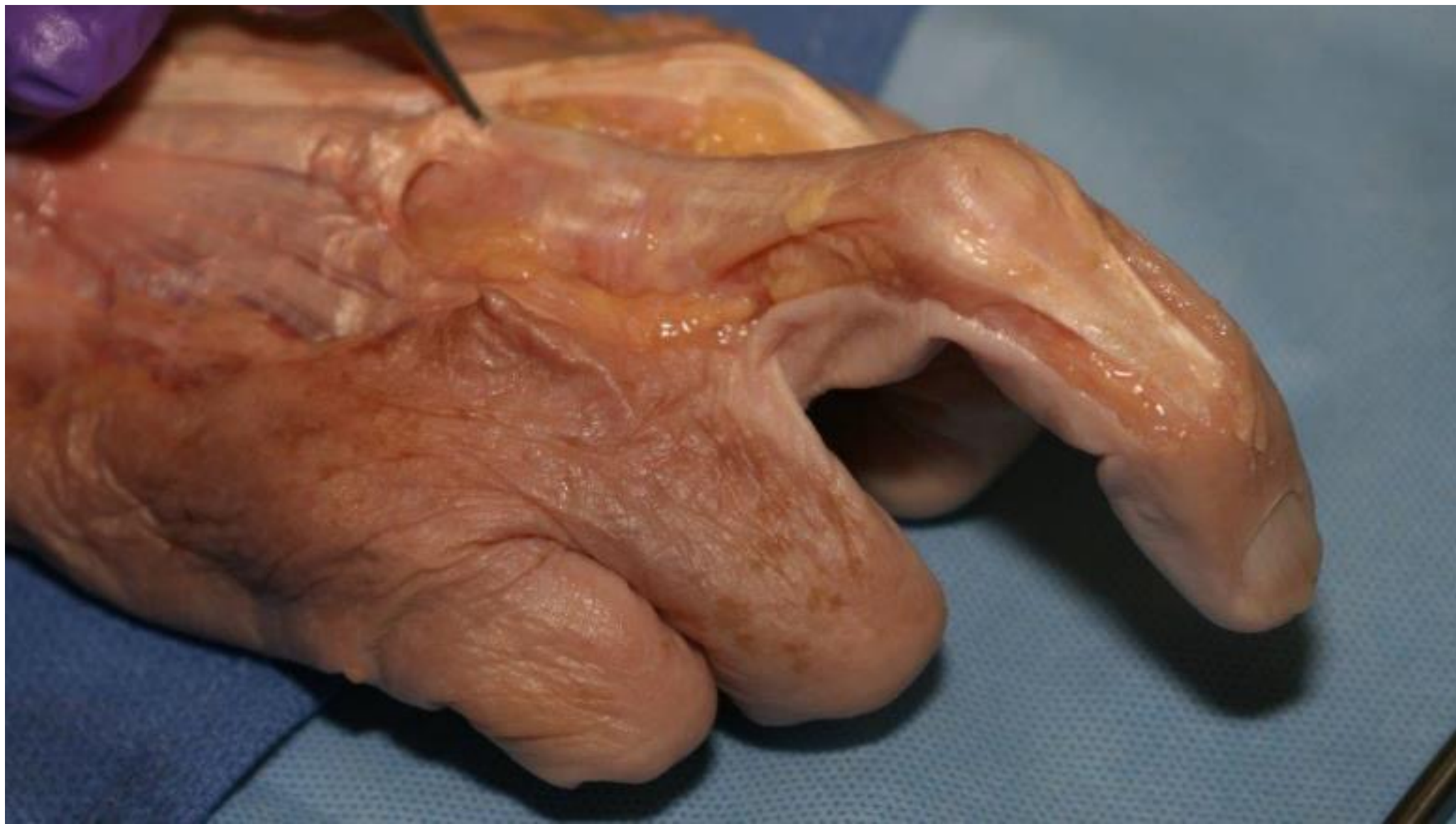



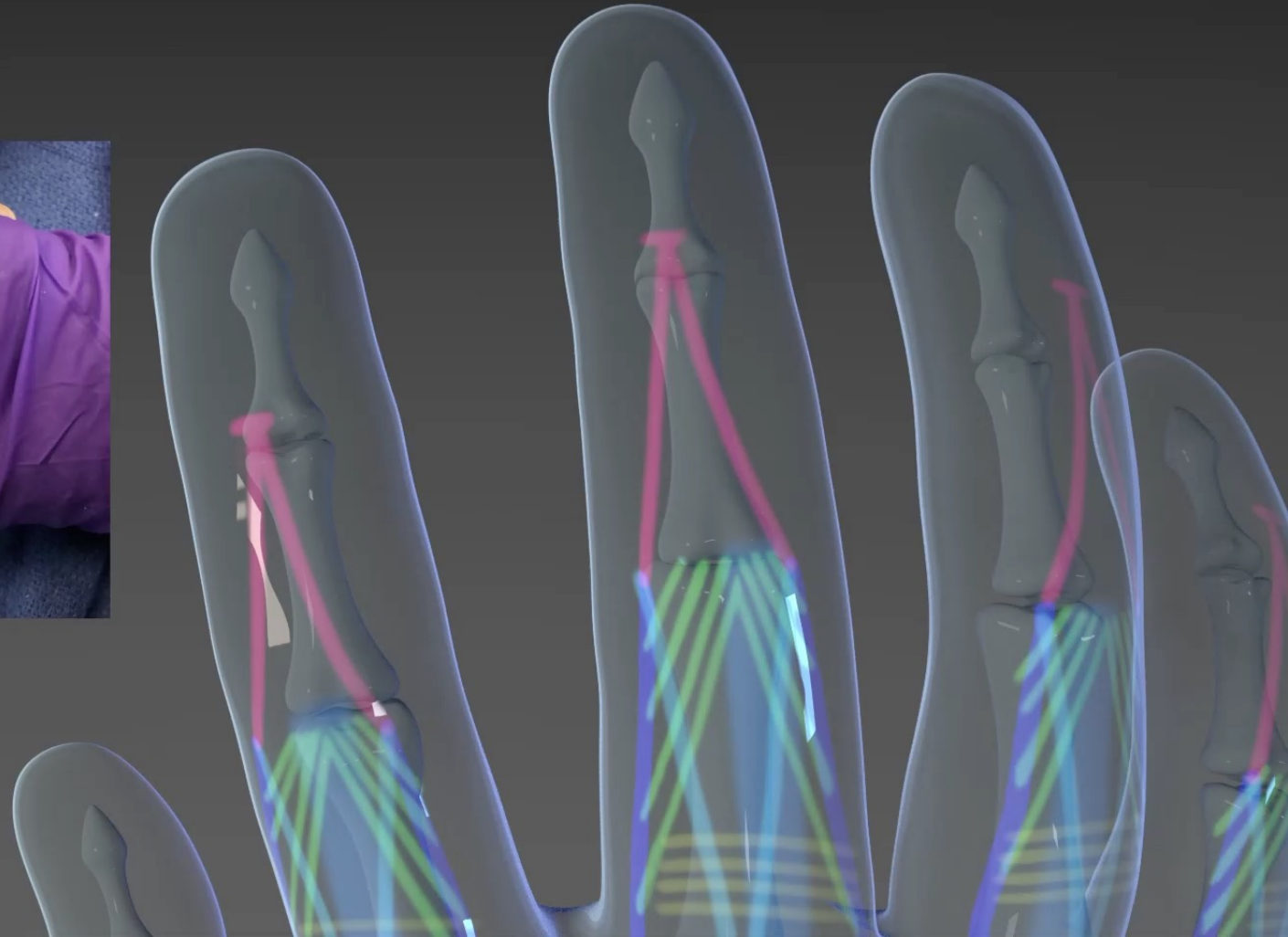
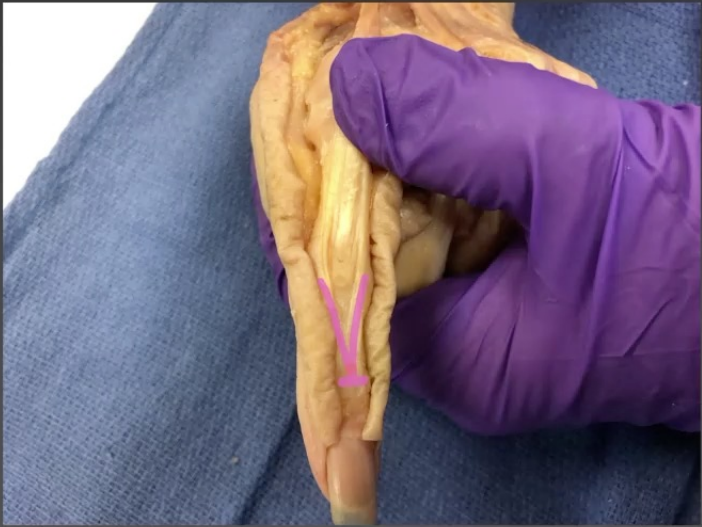Conjoined Lateral Bands



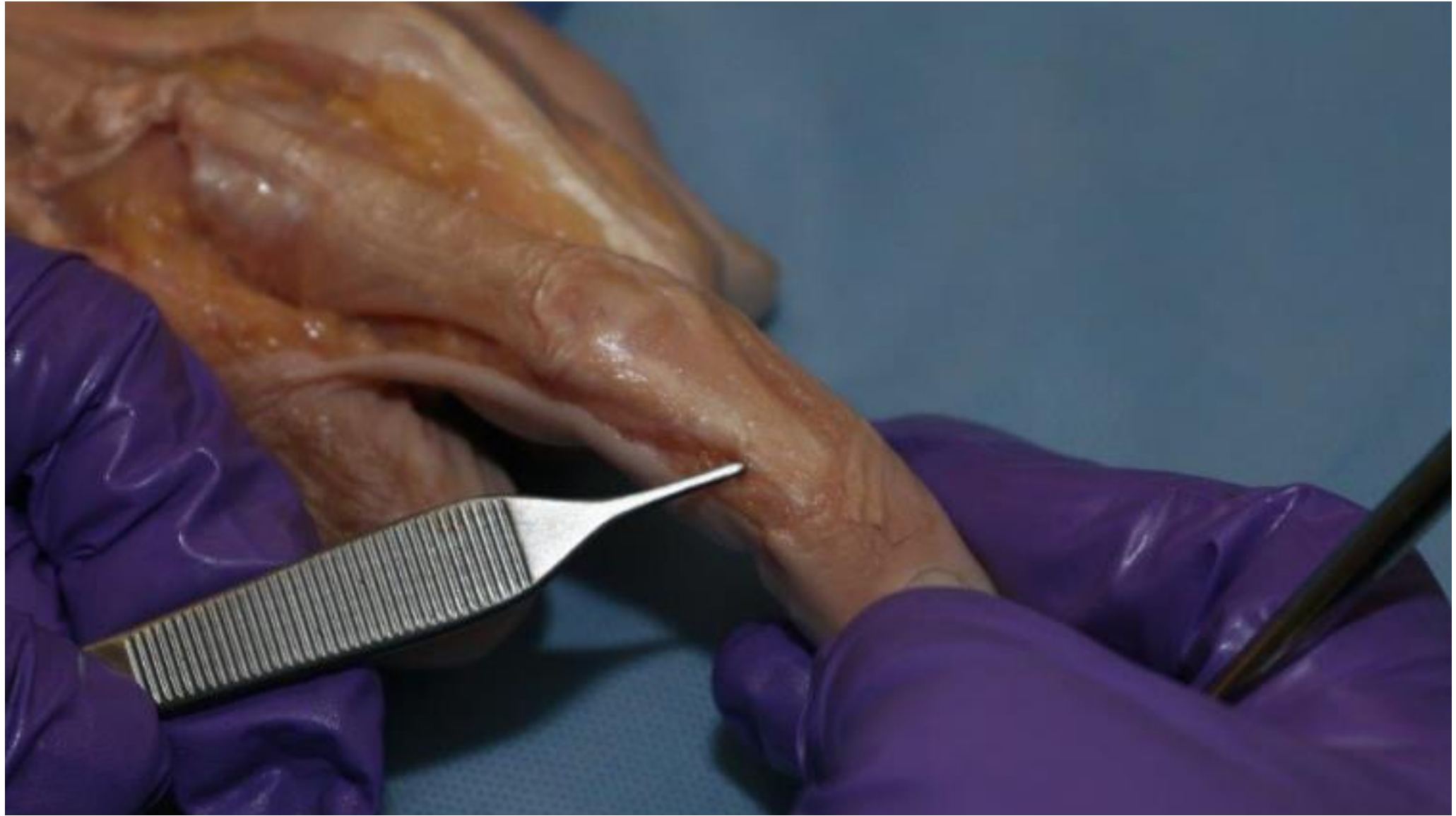Dorsal Hand

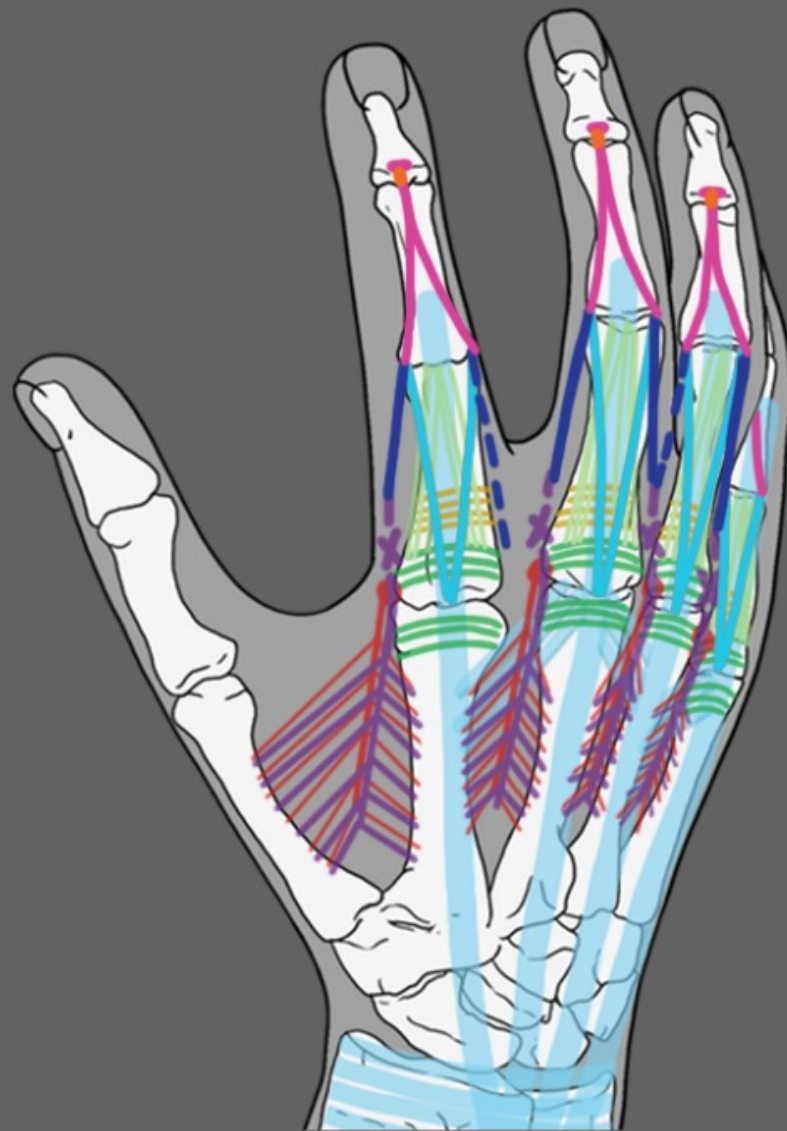
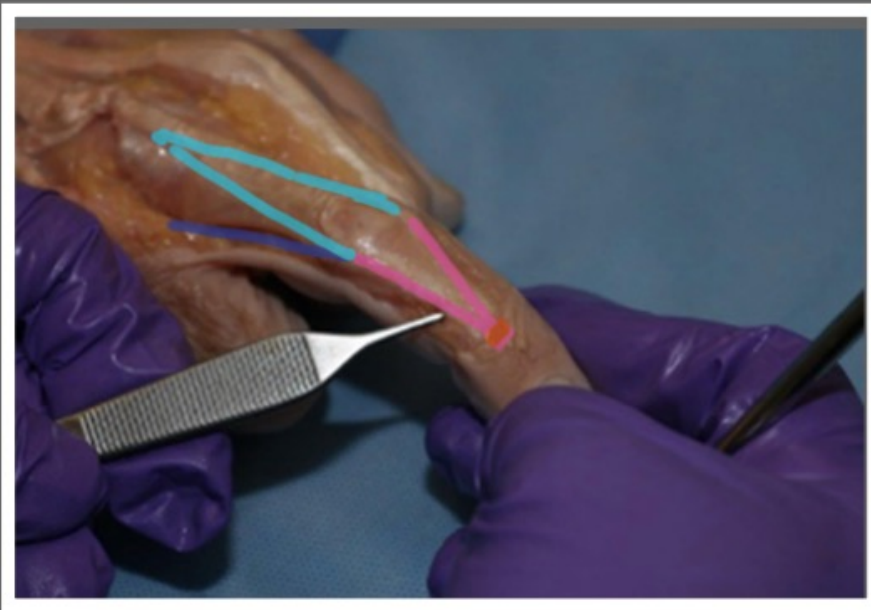


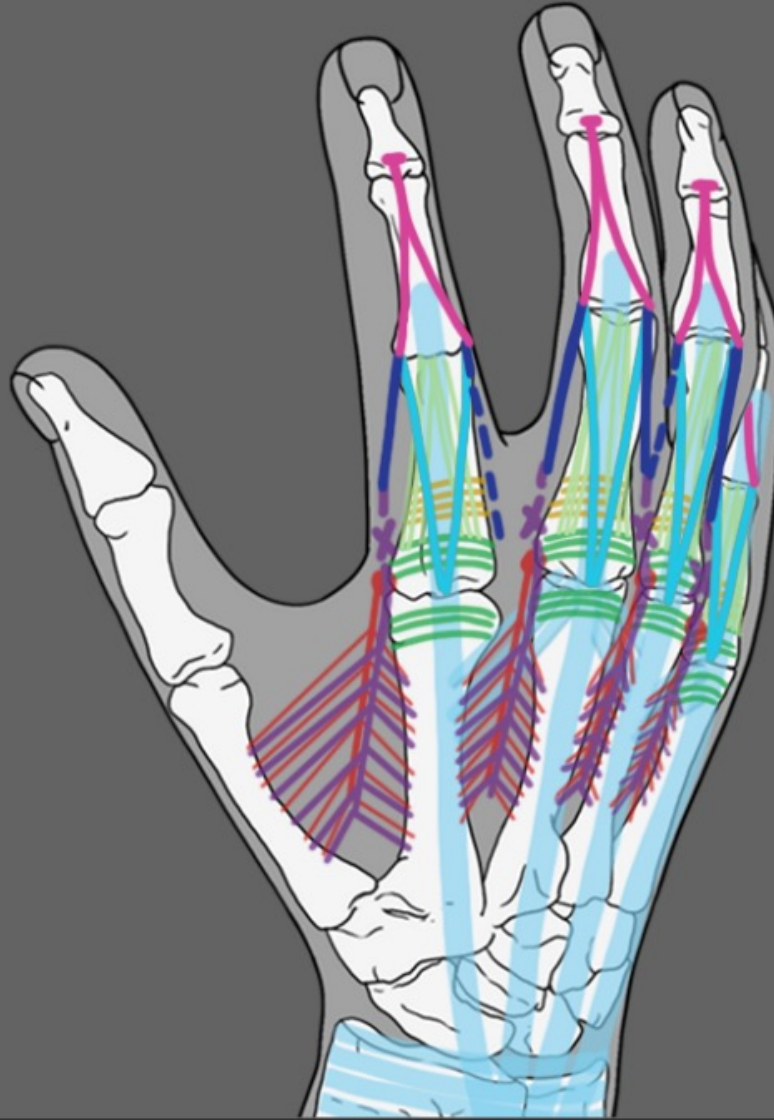
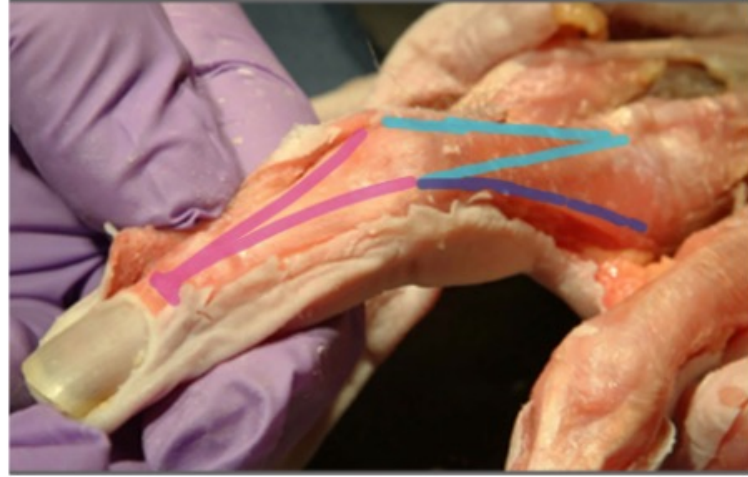
Terminal Tendon



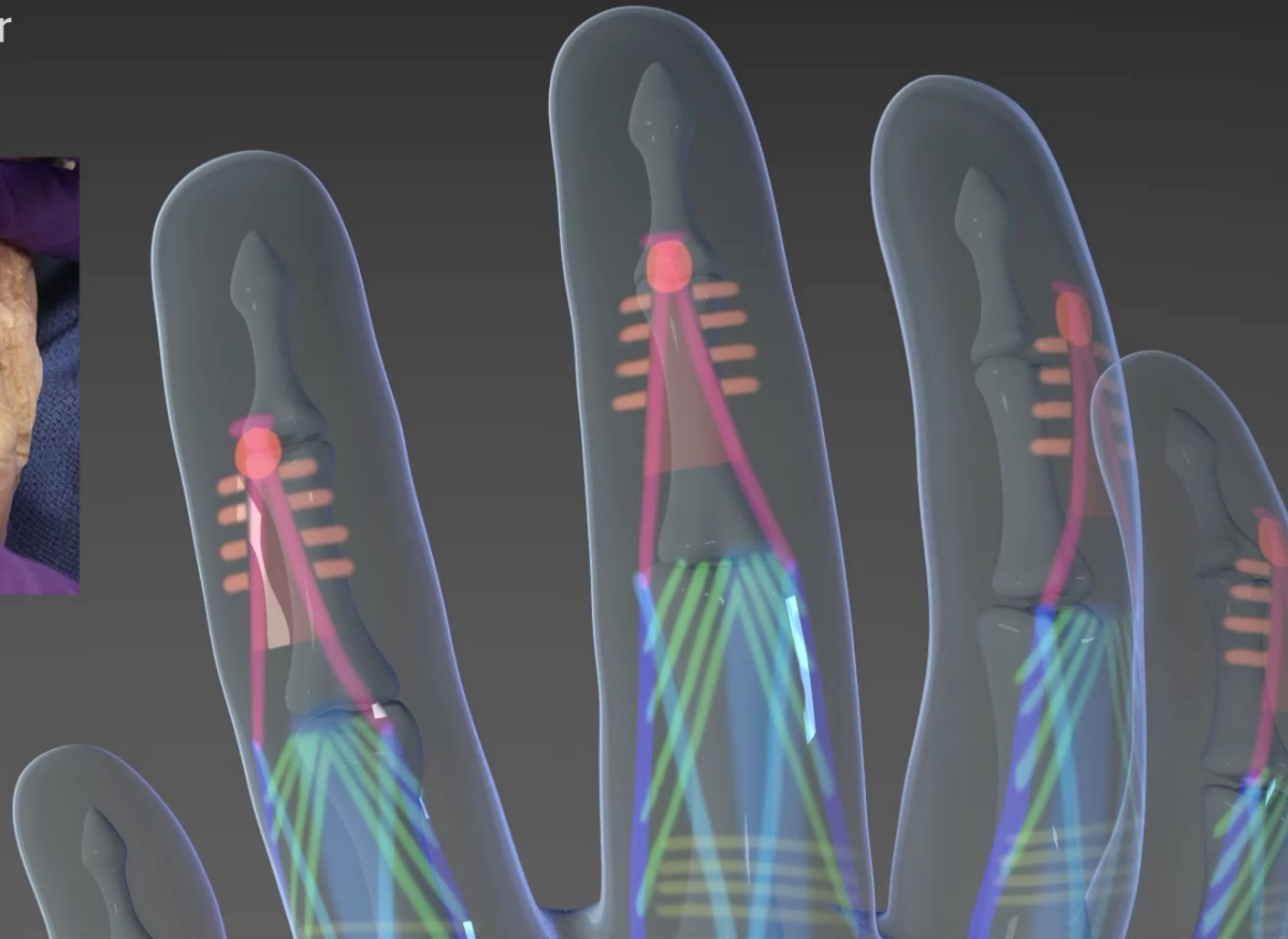
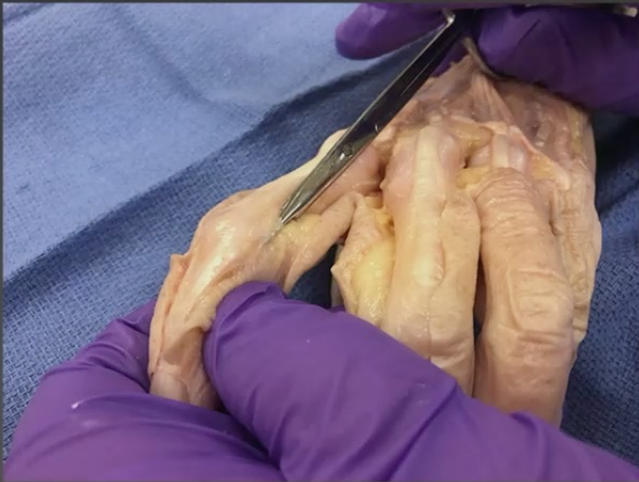Dorsal Hand



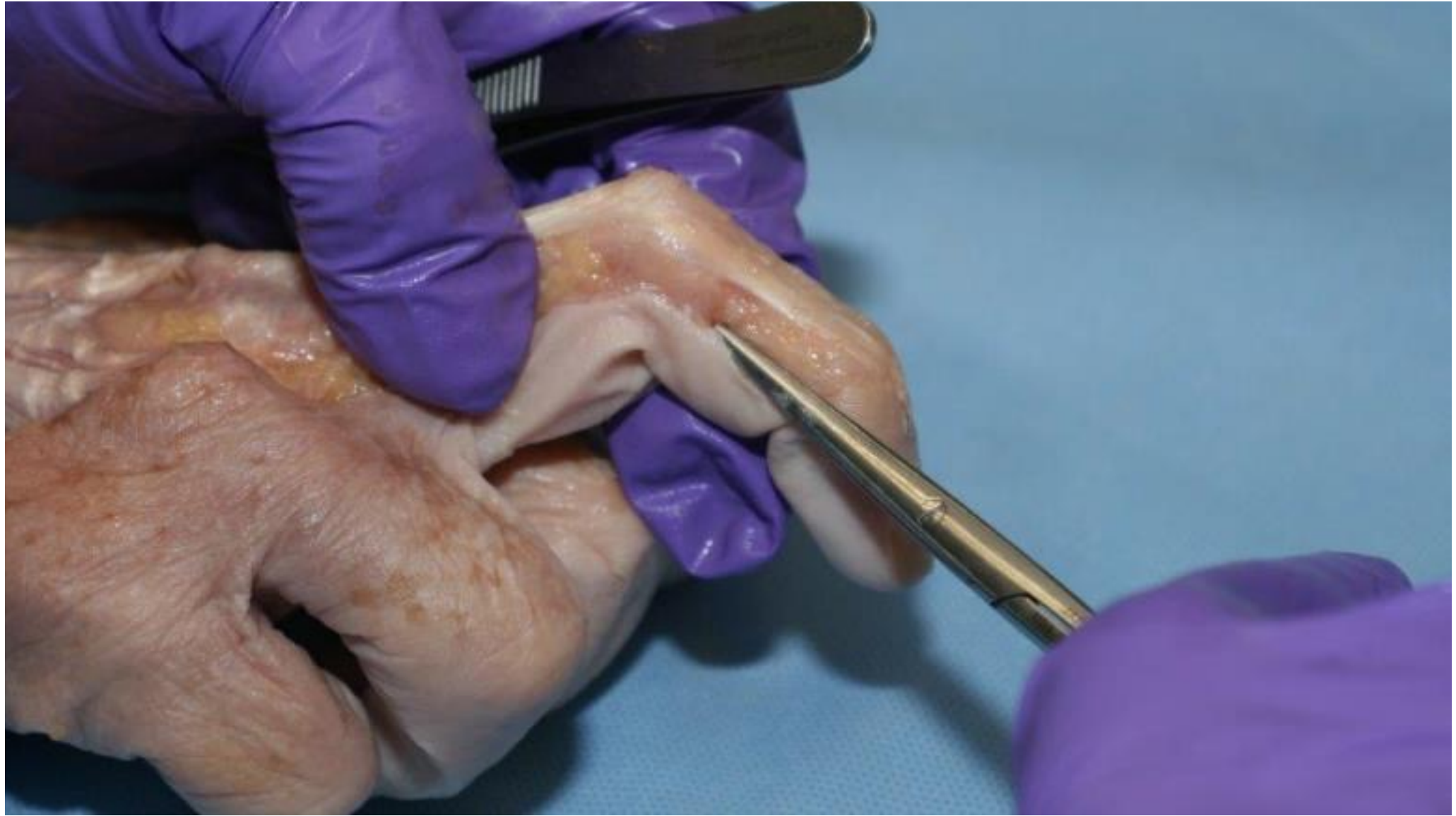



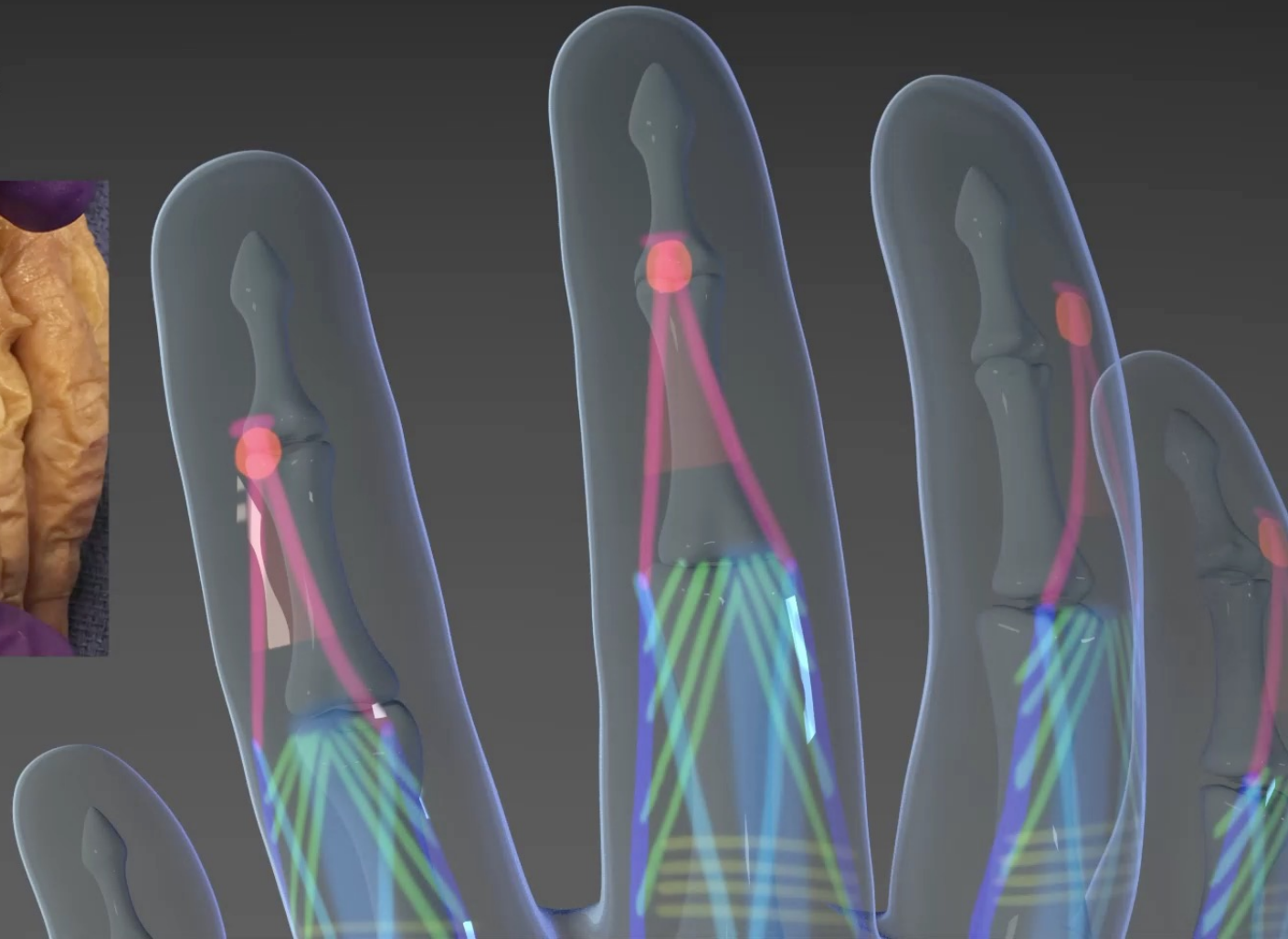
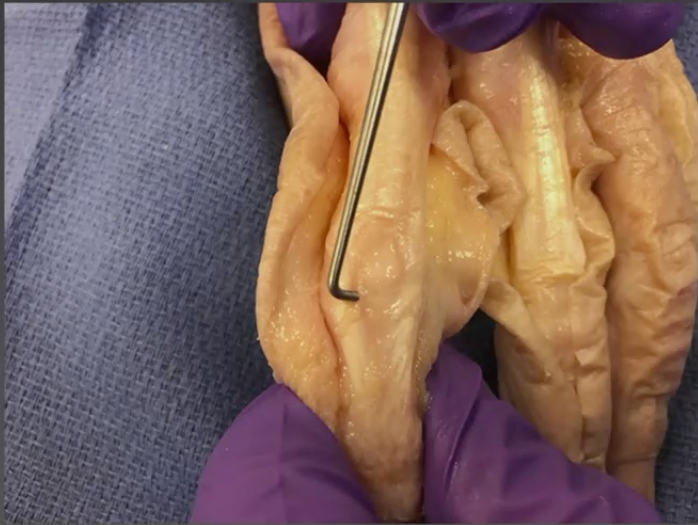Transverse Retinacular Ligament



Dorsal Hand



Triangular Ligament



Dorsal Hand

